Radicular cyst

根尖周囊肿是颌骨内最常见的牙源性囊肿。通常继发于根尖脓肿或根尖肉芽肿。

Radicular cyst

Radicular cyst

[临床表现]

根尖周囊肿常和一死髓牙相连，牙体无光泽，呈黄色或灰色，大多无明显自觉症状，叩诊的反应无明显异常或仅有不适感。

囊肿直径通常在1—2cm，不引起颌骨畸形，常在X线检查是偶尔发现。大者如鸡蛋大小，引起颌骨膨隆，骨皮质变薄，按之有乒乓球感。

Radicular cyst

X-ray features:

Radicular cyst

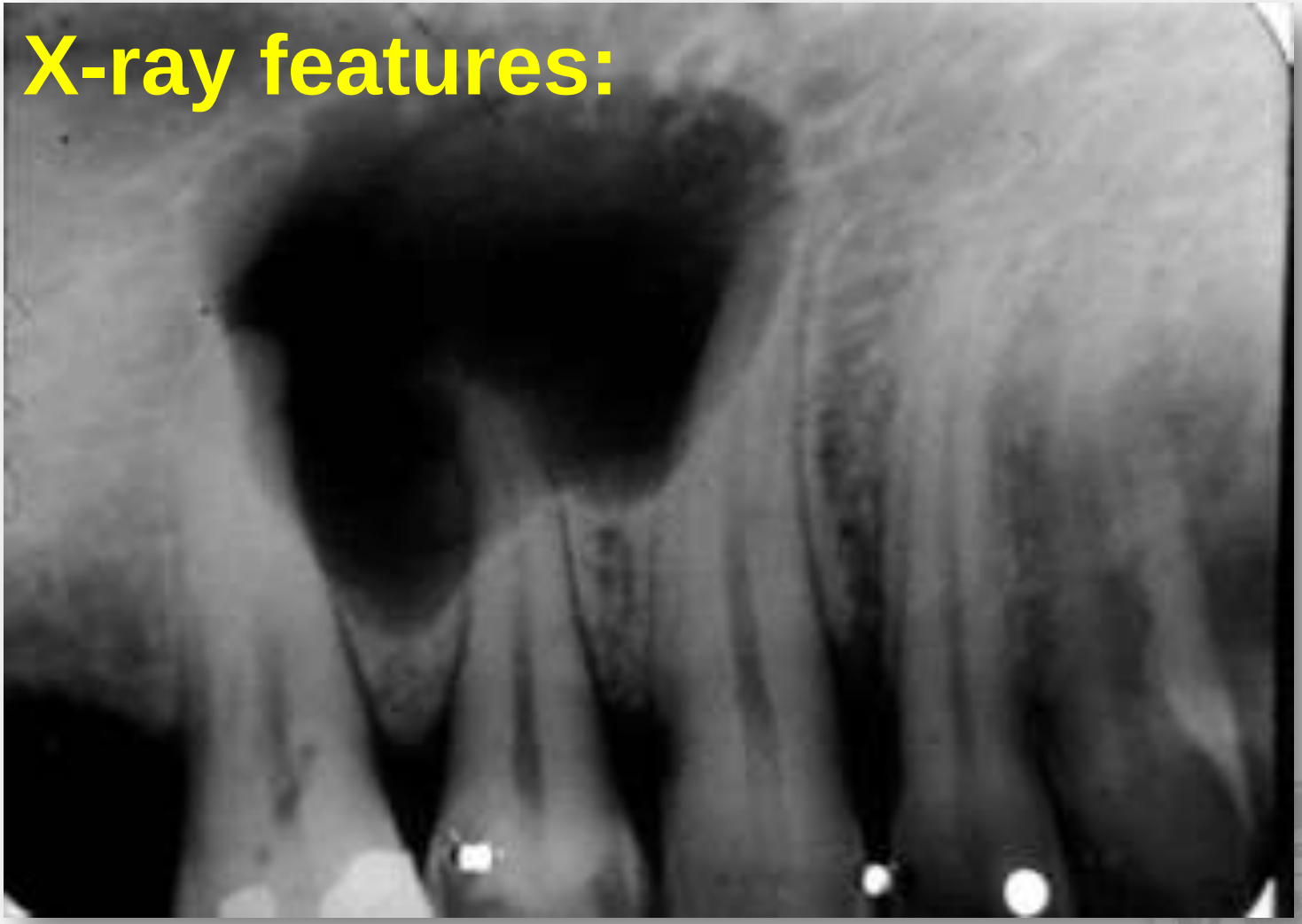

Radicular cyst

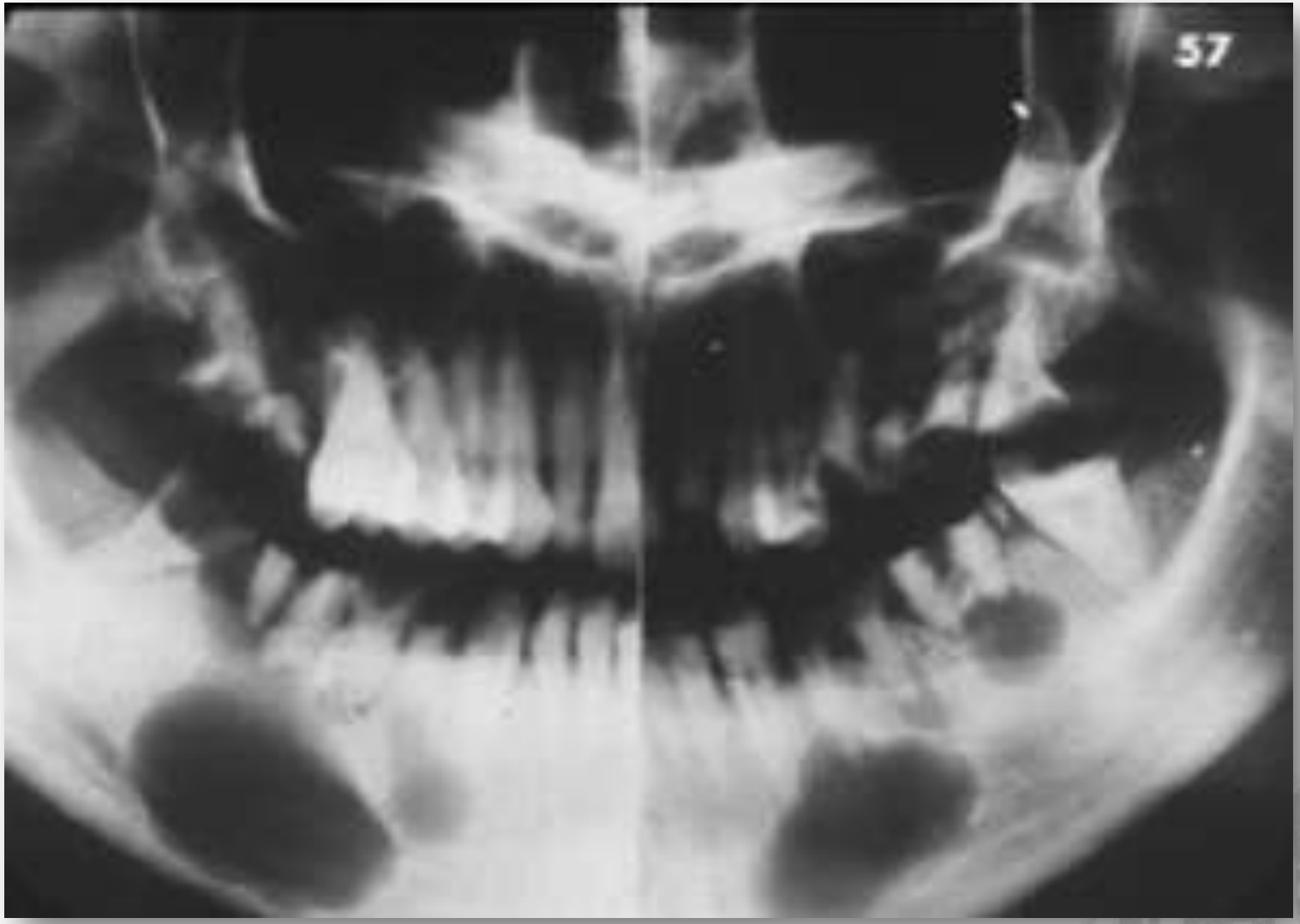

Radicular cyst

pathology

Radicular cyst

Radicular cyst

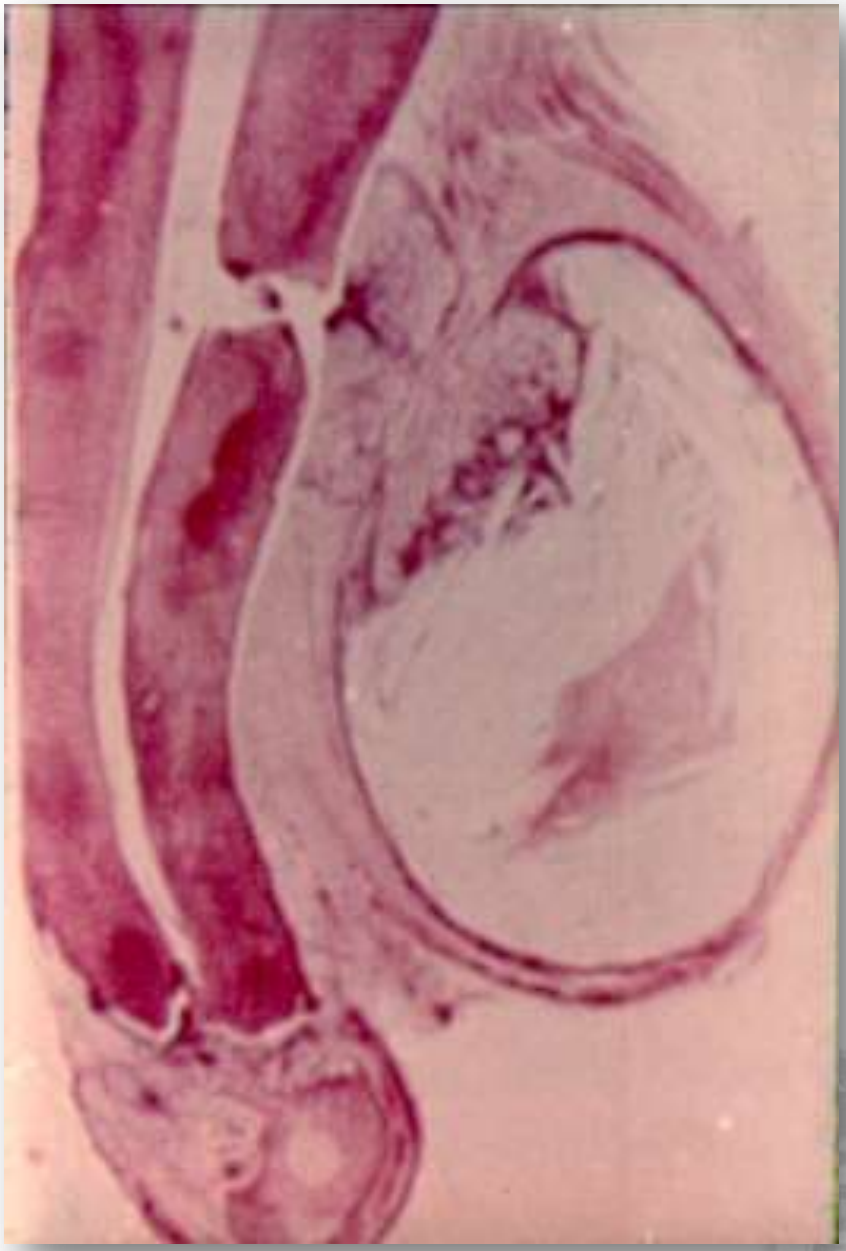

Radicular cyst

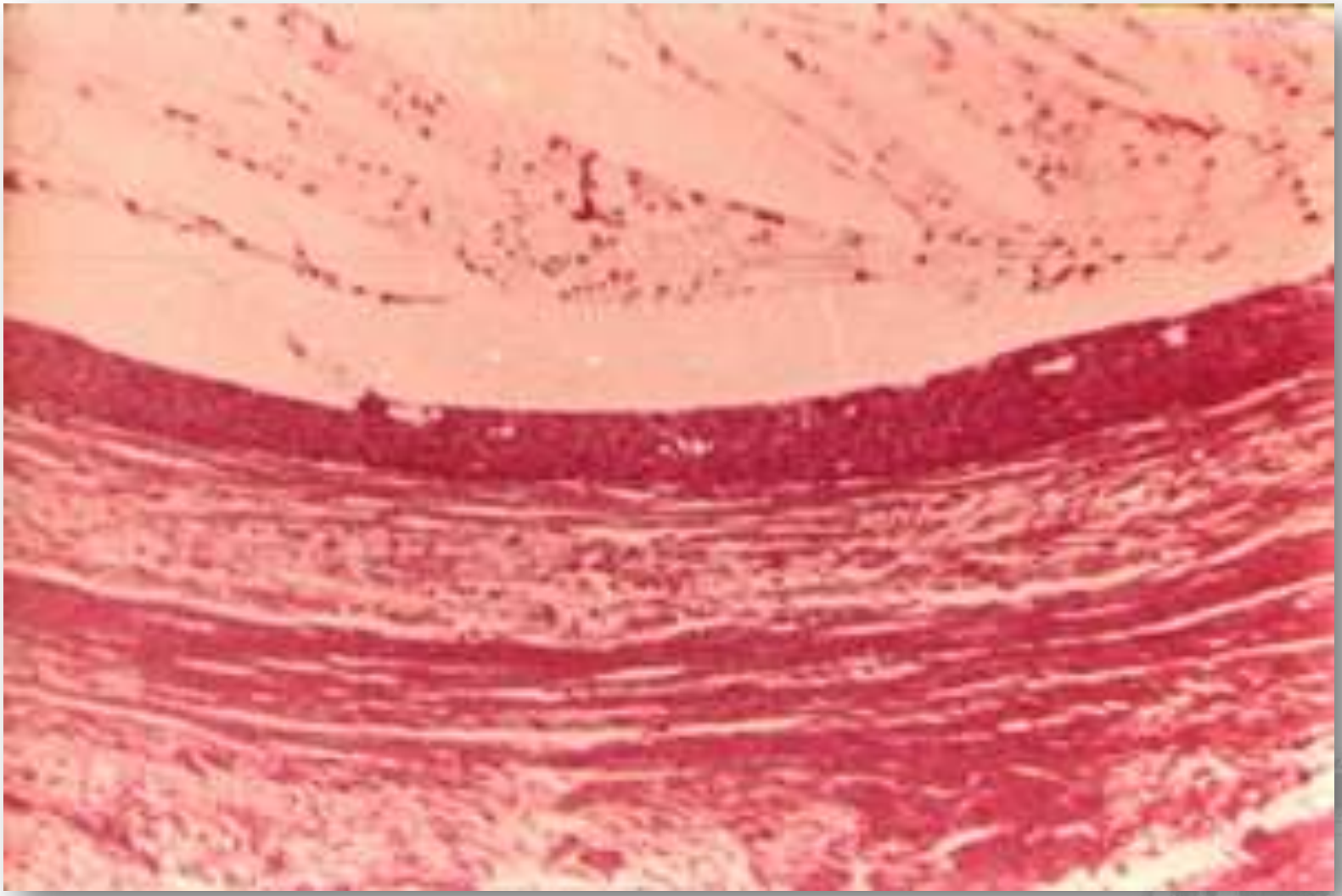

Radicular cyst

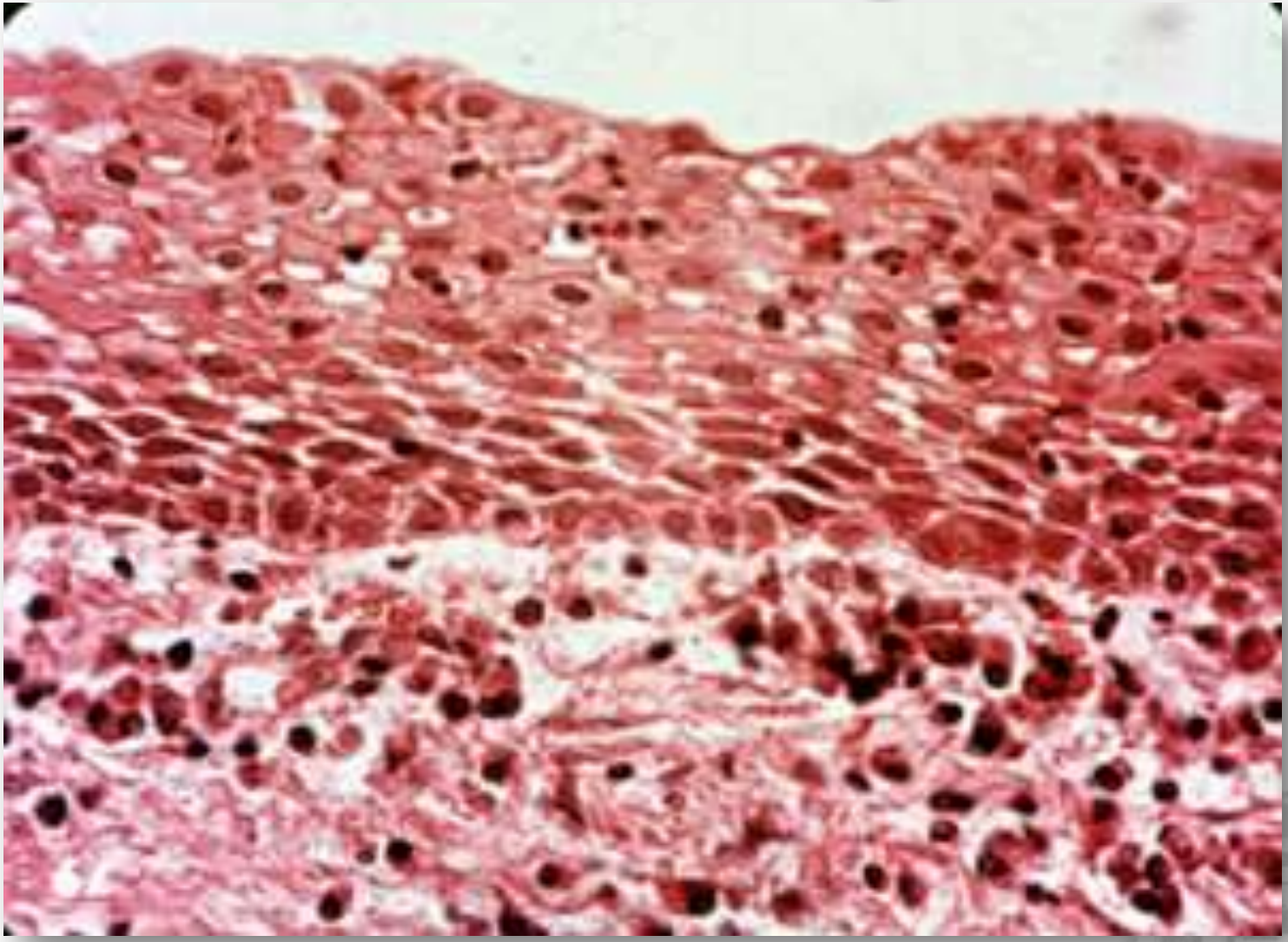

Radicular cyst

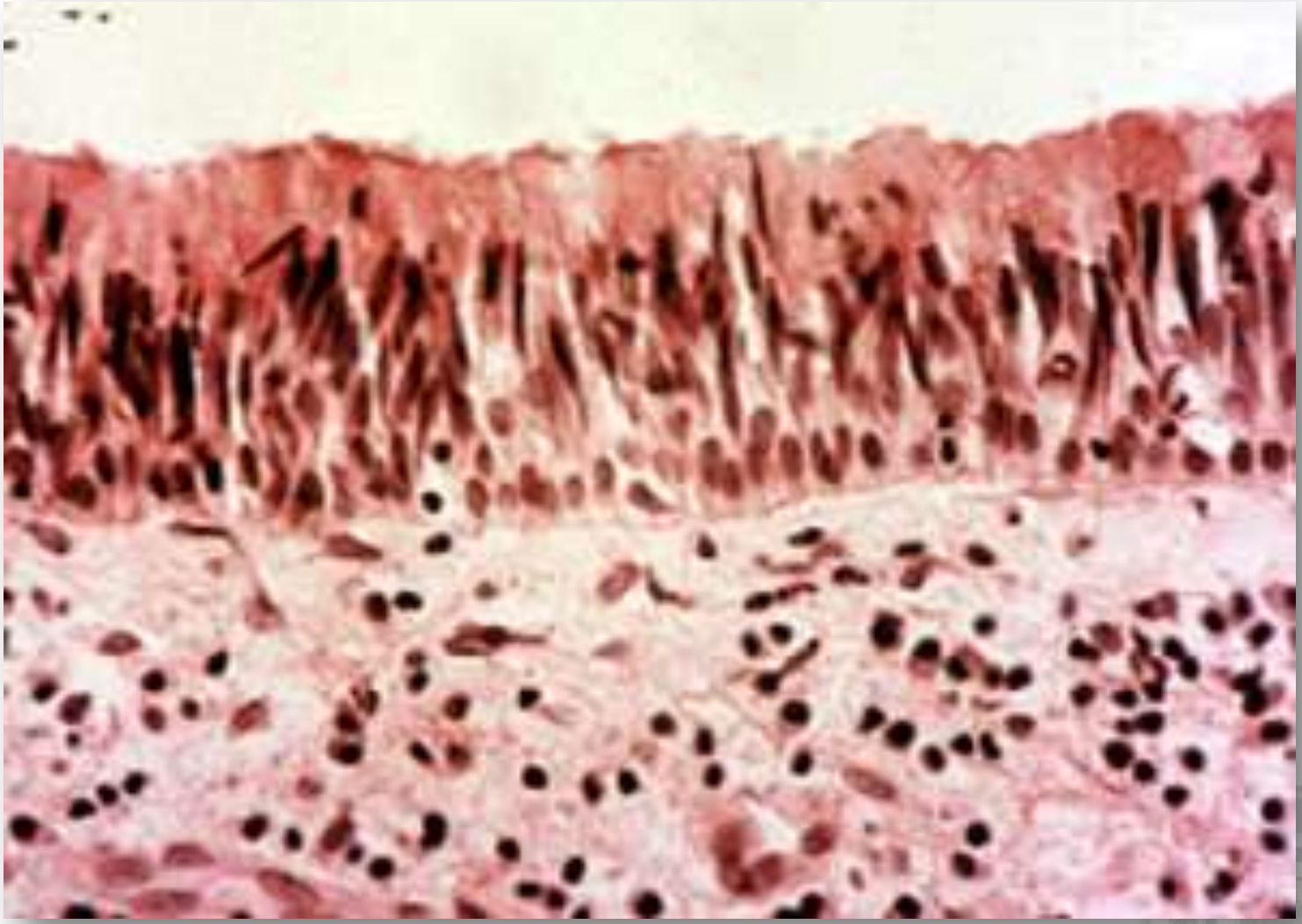

Radicular cyst

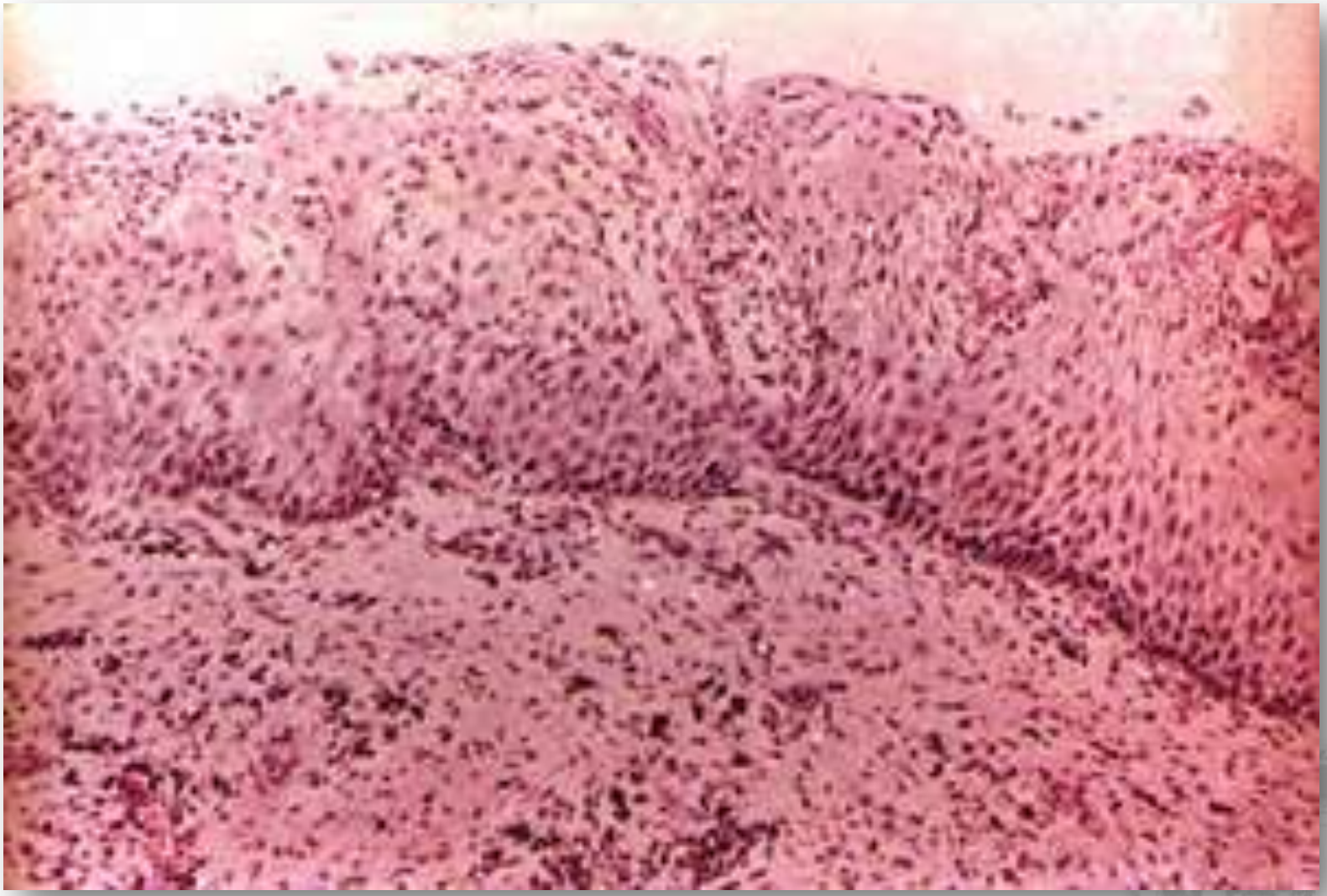

Radicular cyst

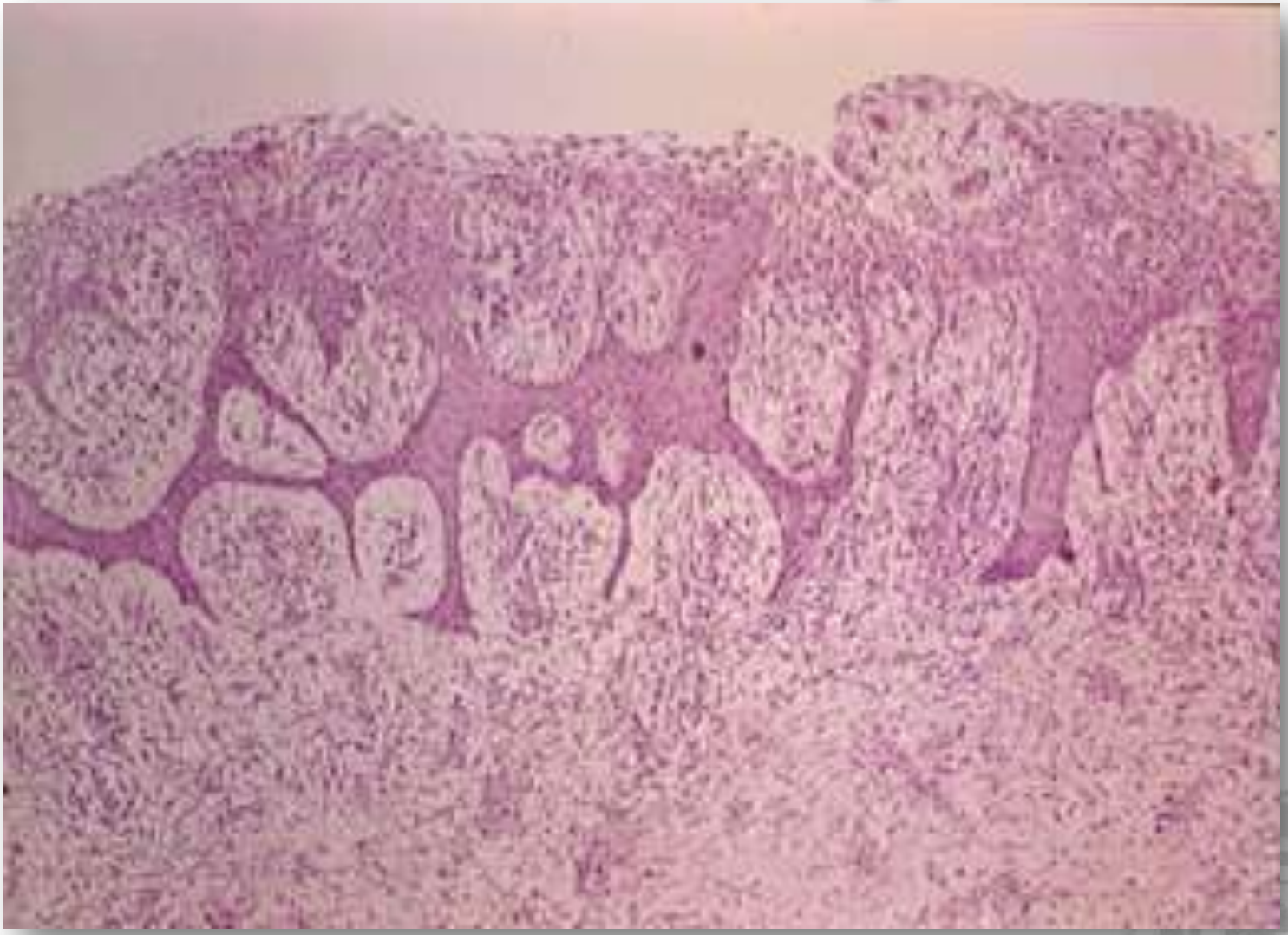

Radicular cyst

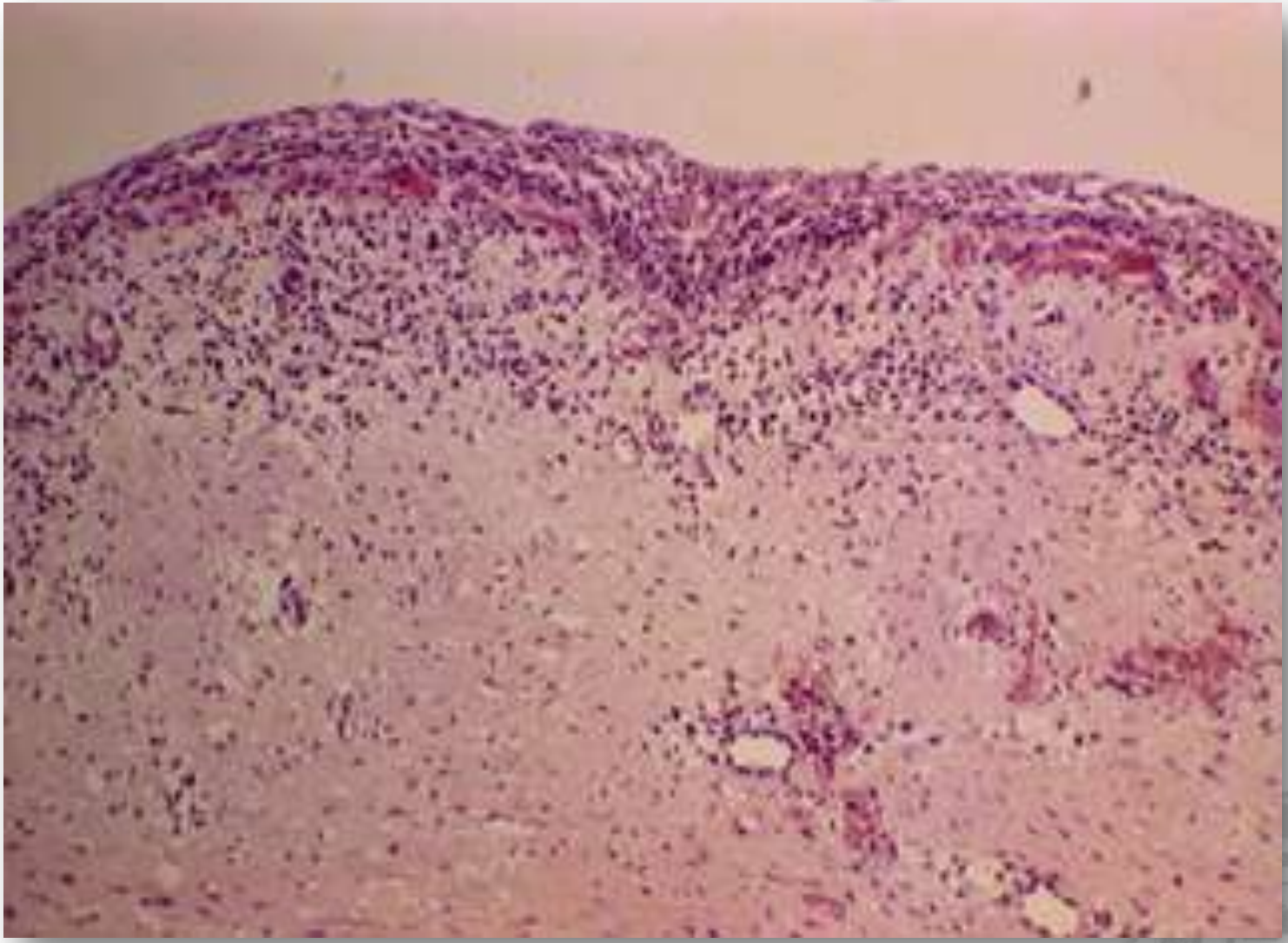

Radicular cyst

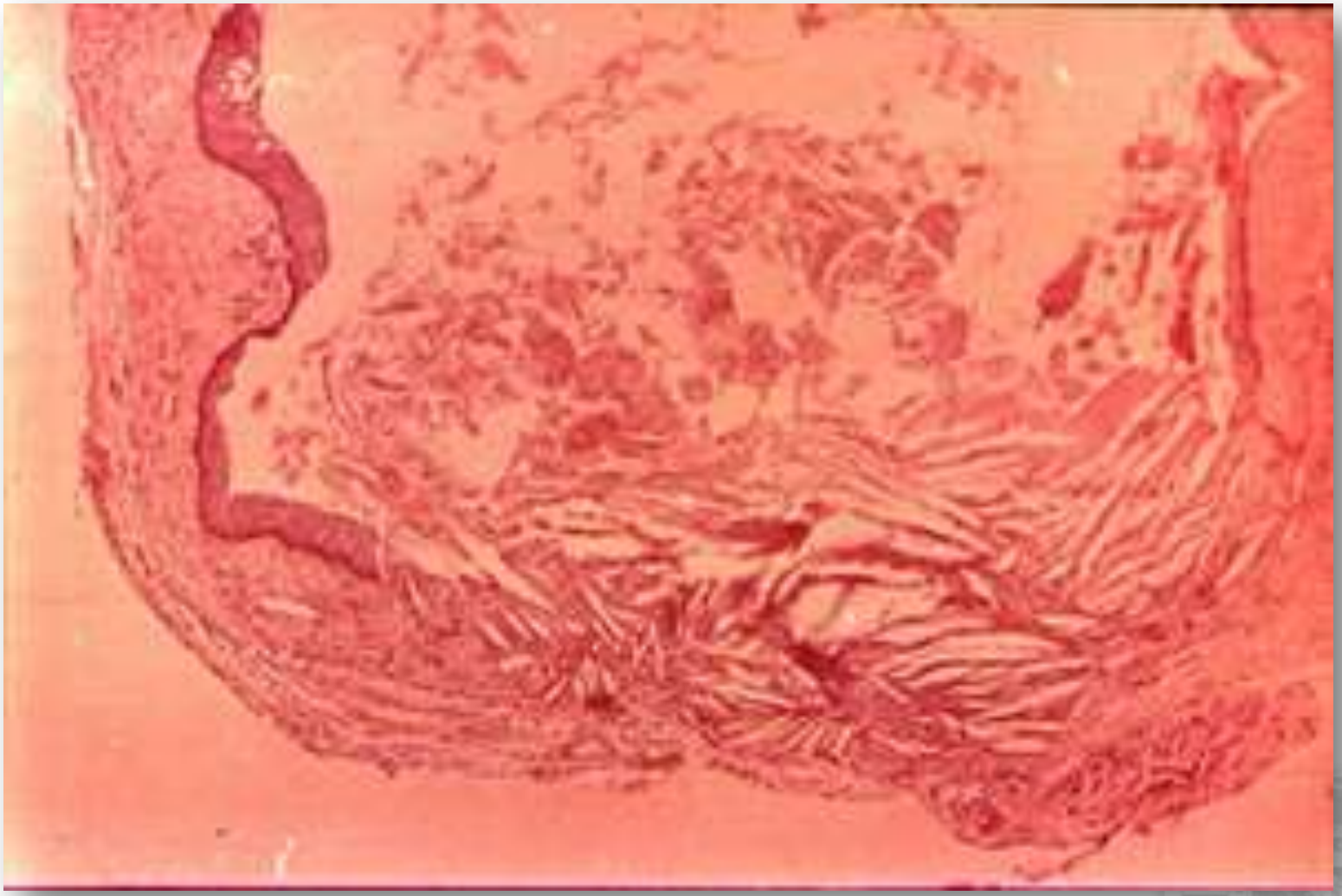

Radicular cyst

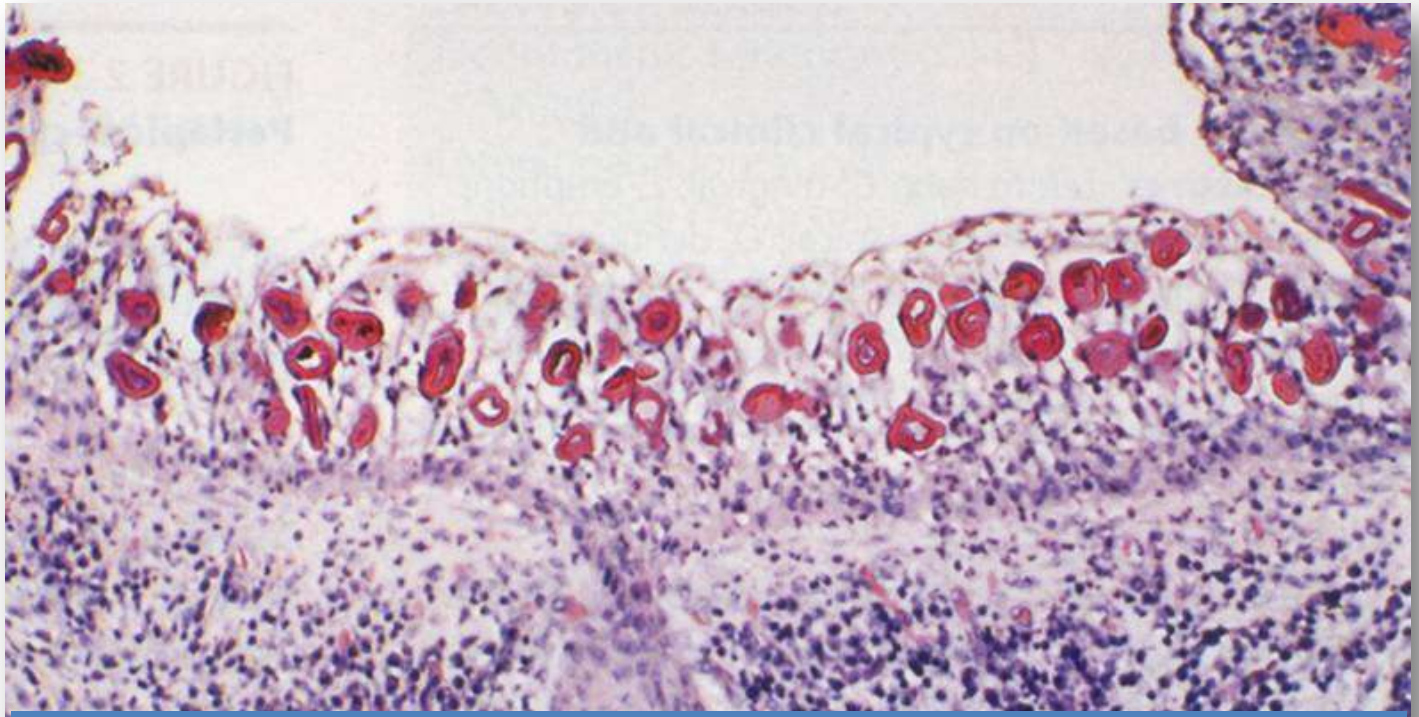

透明小体
(hyaline bodies, Rushton bodies)

Radicular cyst

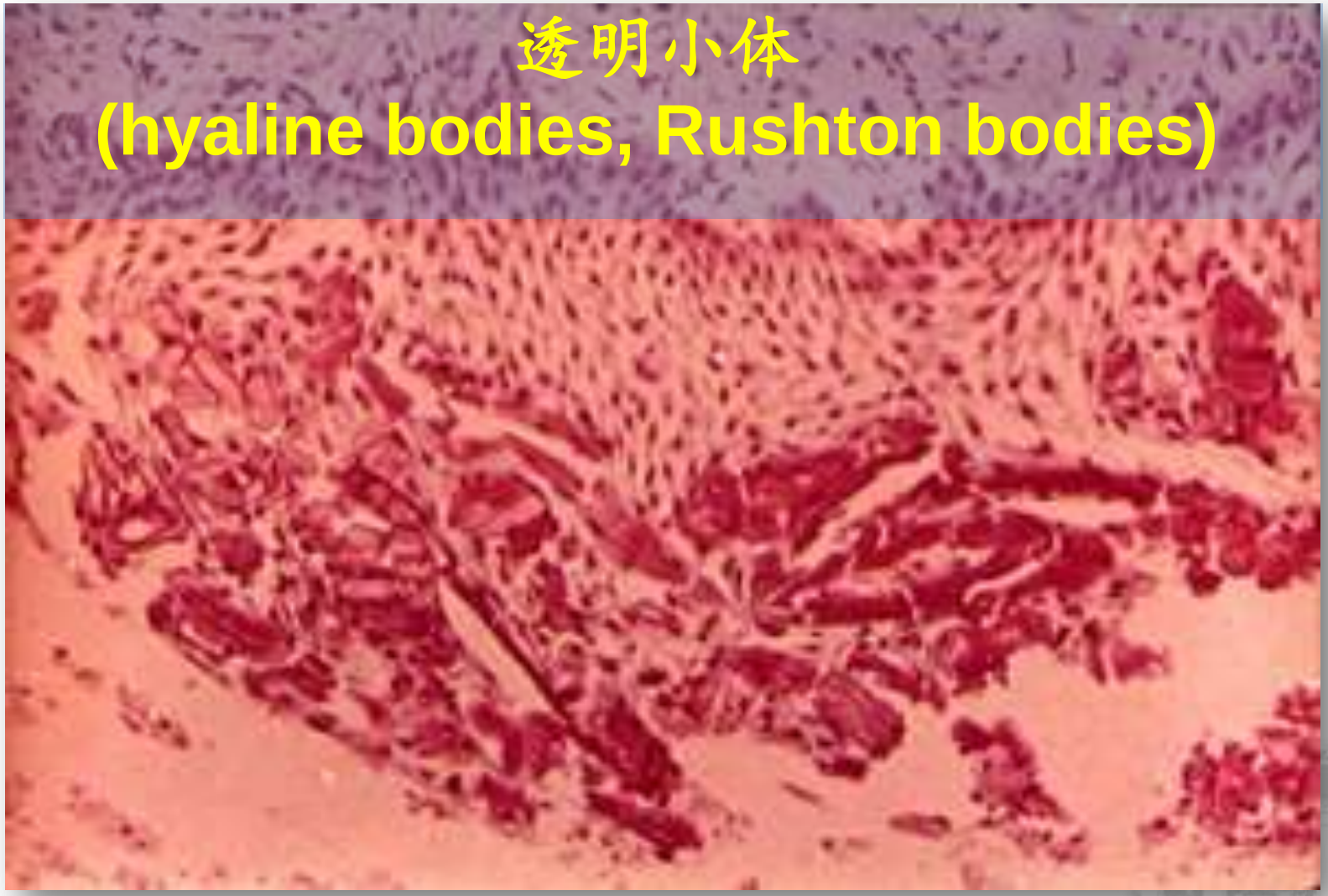

Radicular cyst

Radicular cyst

Radicular cyst

Radicular cyst



Radicular cyst

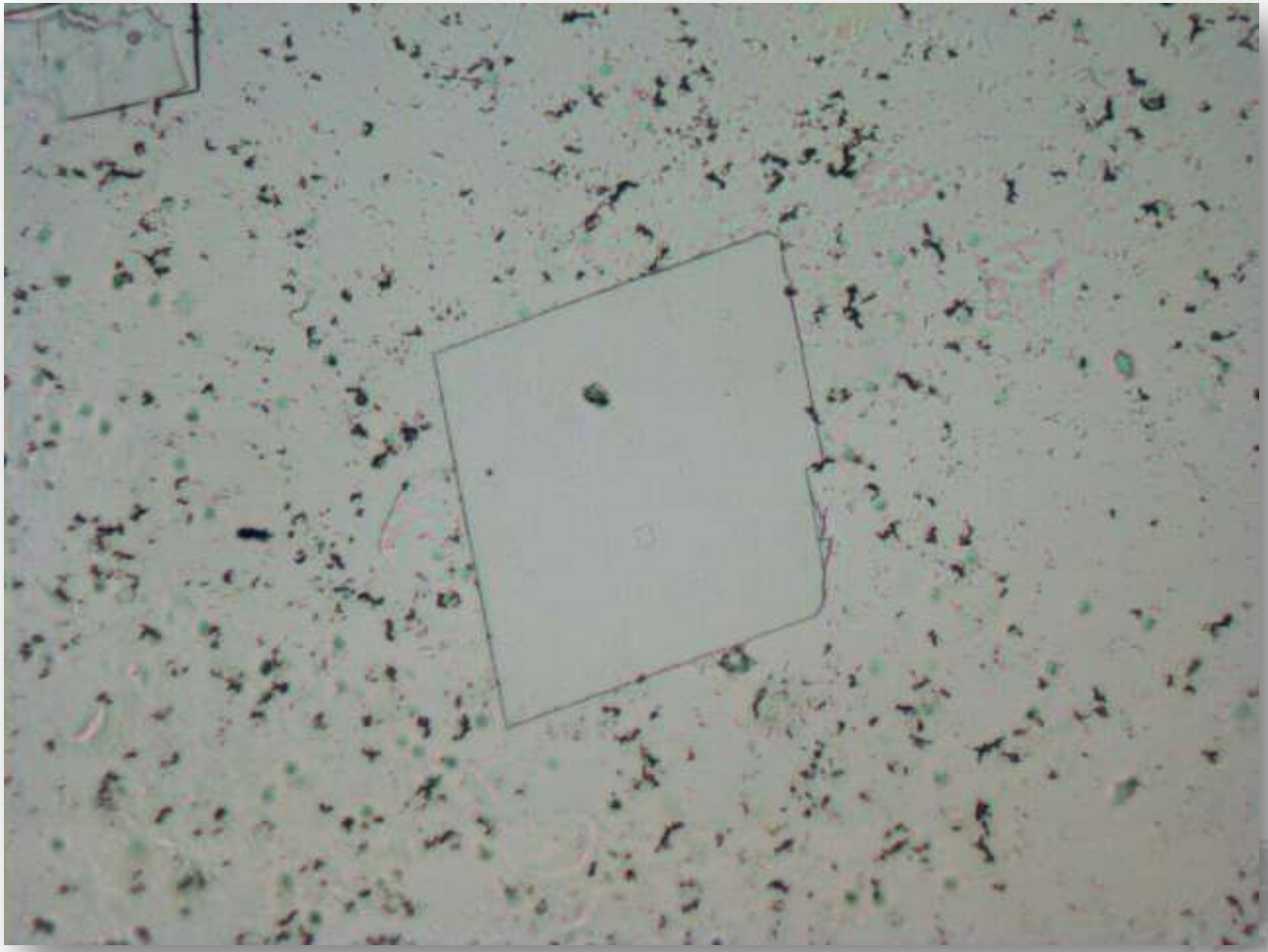

Radicular cyst