

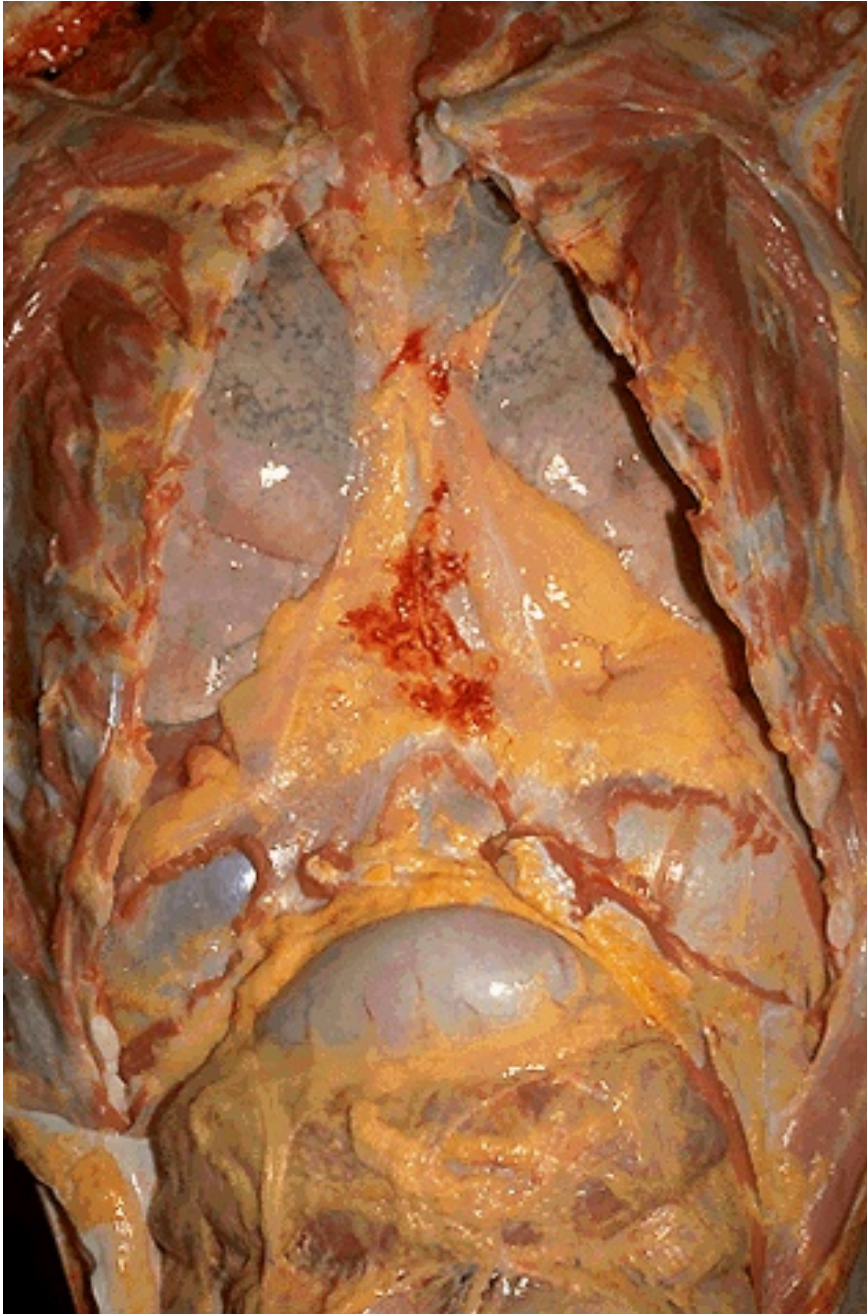Pathology of Respiratory System

Chen Jian *Instructor*

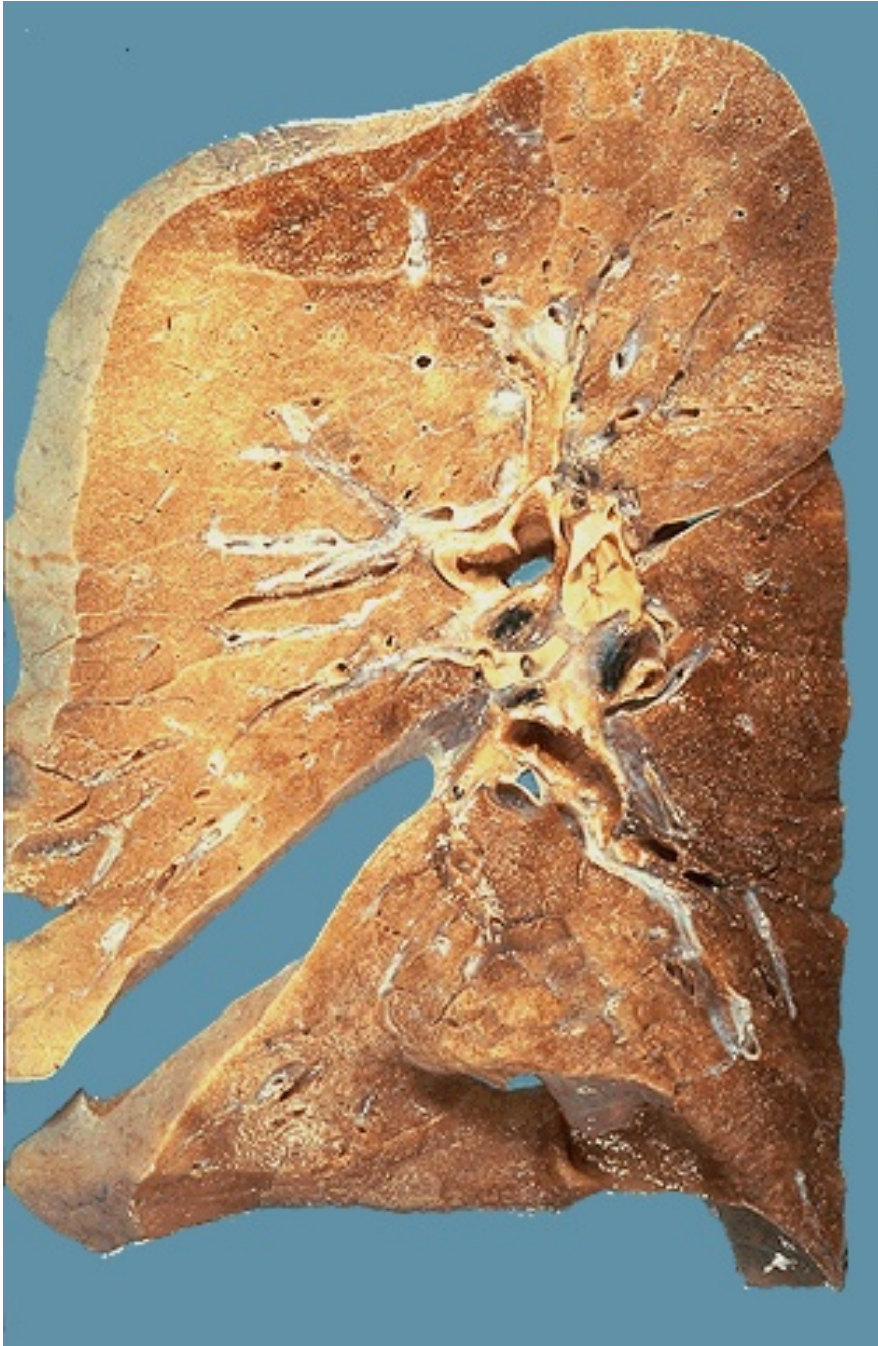Department of Pathology & Pathophysiology
Research Building Section B room 303, School of Medicine,
Zhejiang University, ZJG Campus
cj@zju.edu.cn 88208199

Normal Lung

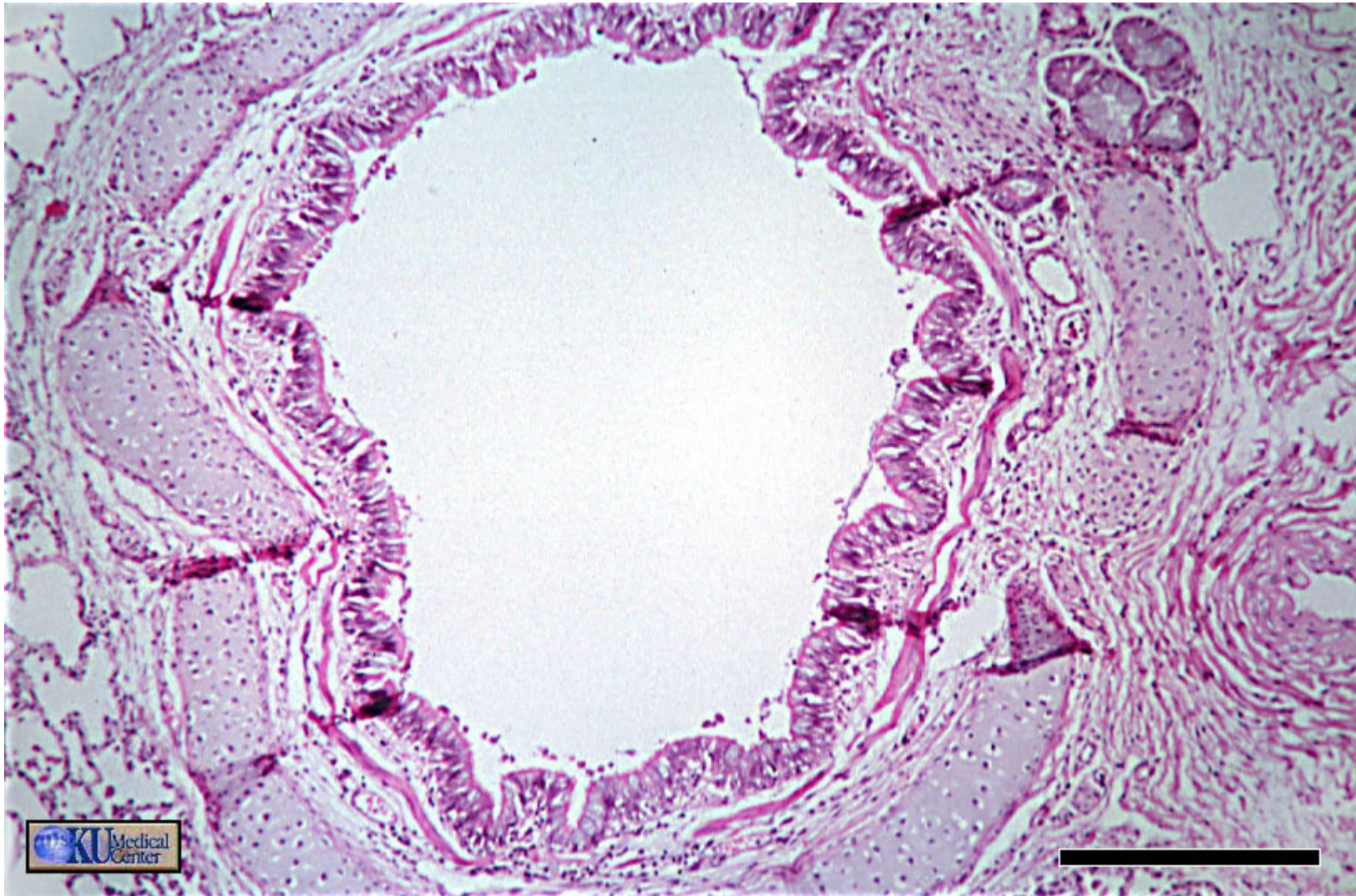
- The major function of the lung is to excrete carbon dioxide from blood and replenish oxygen.
- *Trachea*
- *Bronchi*
- *Bronchiole*
- *Terminal bronchioles*
- *Acinus*
- *Alveoli*



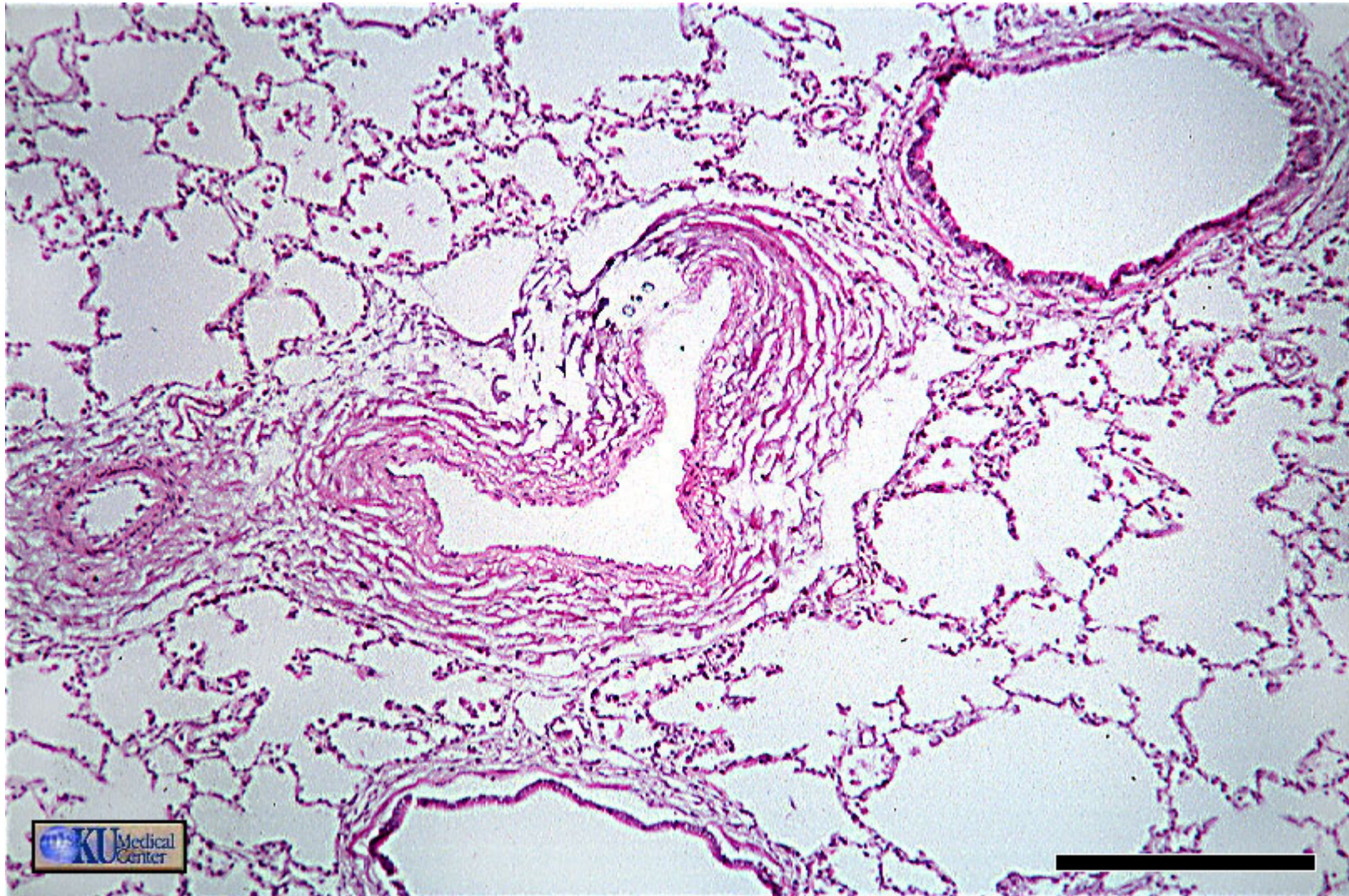
The chest and abdominal cavities are opened here at autopsy. The lungs in the chest have a normal pink aerated appearance with minimal anthracotic pigmentation, because this 80 year old male never smoked and never allowed smoking in his workplace. The mediastinum contains mostly fat. The pericardial sac around the heart has not been opened. The diaphragmatic domes extend upward to the level of the 6th ribs.



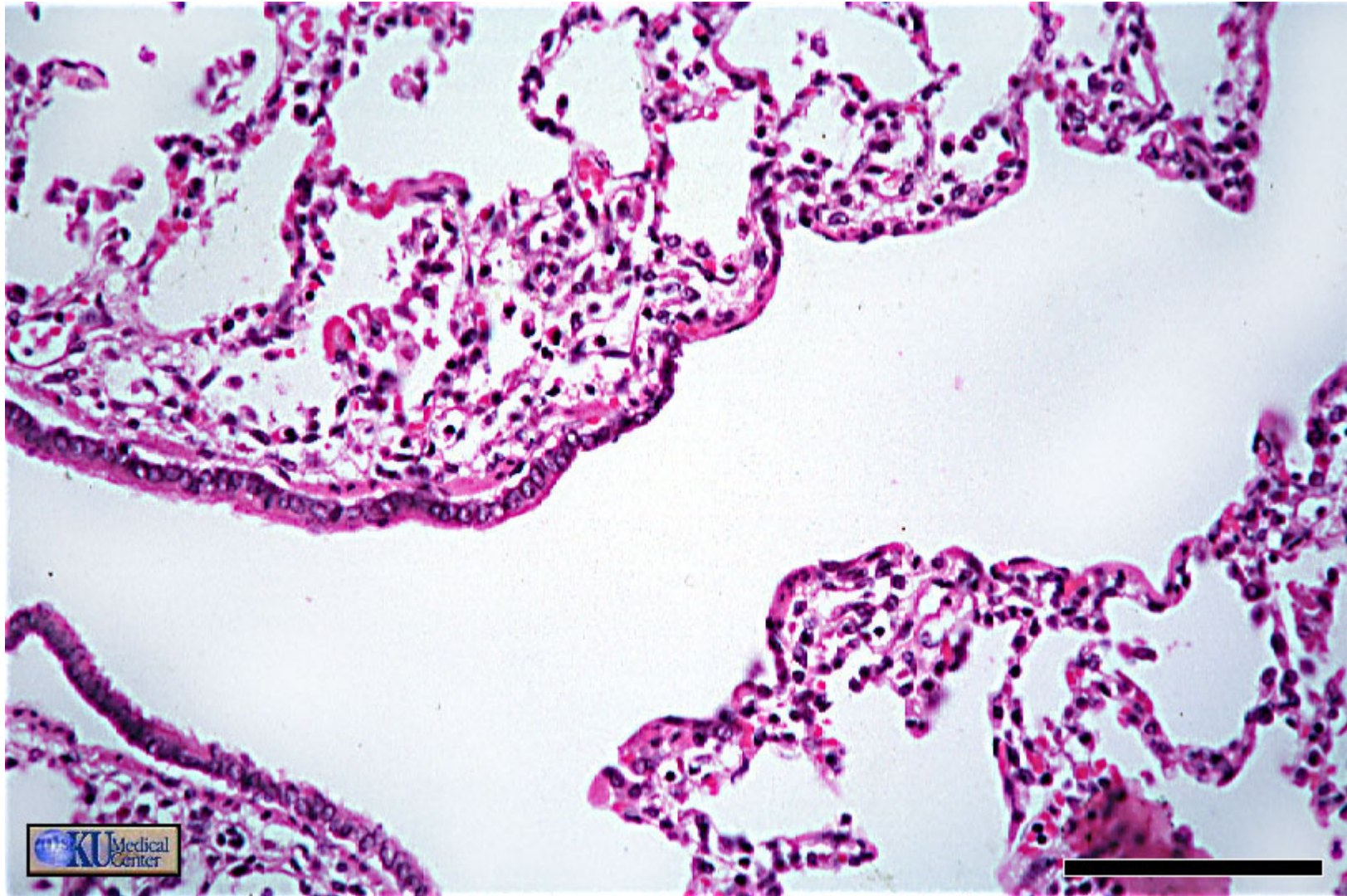
This is a cross-section of normal lung (with only minimal posterior congestion at the lower right). The hilar lymph nodes are small and have enough anthracotic pigment (from dusts in the air breathed in, scavenged by pulmonary macrophages, transferred to lymphatics, and collected in lymph nodes) to make them appear greyish-black.



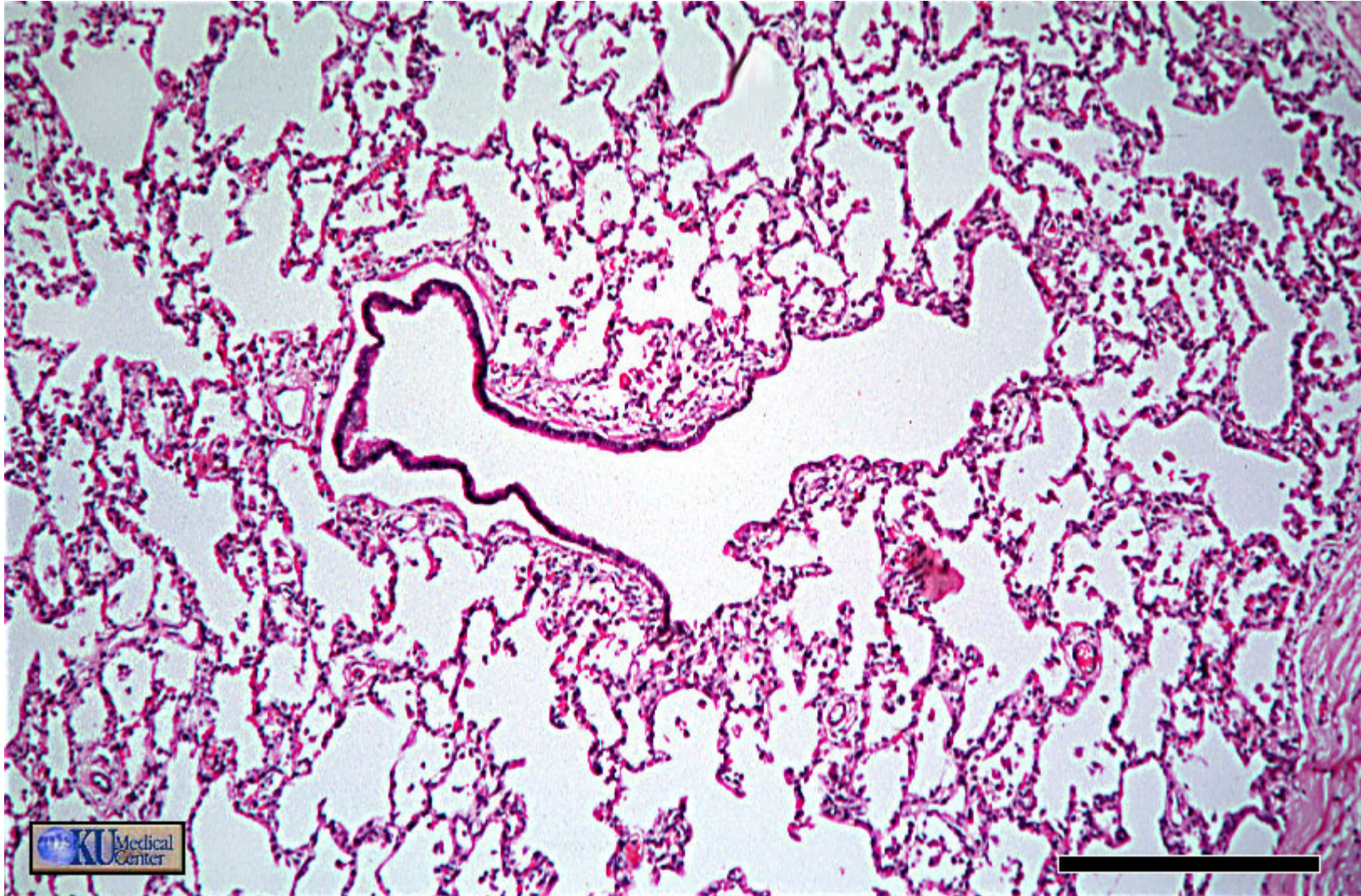
This bronchus has a surrounding ring of cartilage (hyaline) plus sero-mucus glands (upper right). Recall that bronchioles have neither.



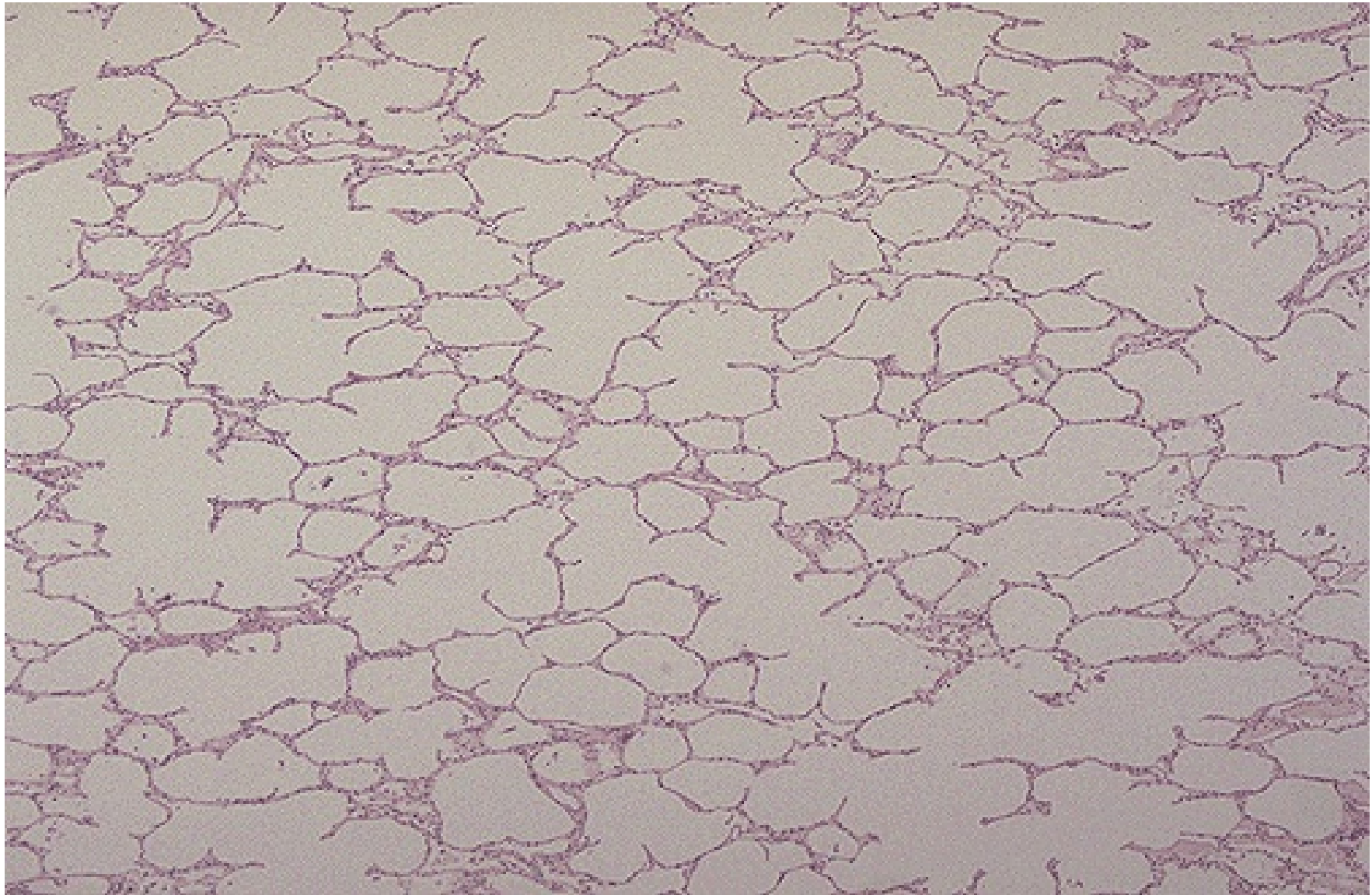
In the absence of cartilage and glands, this must be a bronchiole (upper right). To the left are a pulmonary vein and a pulmonary artery.



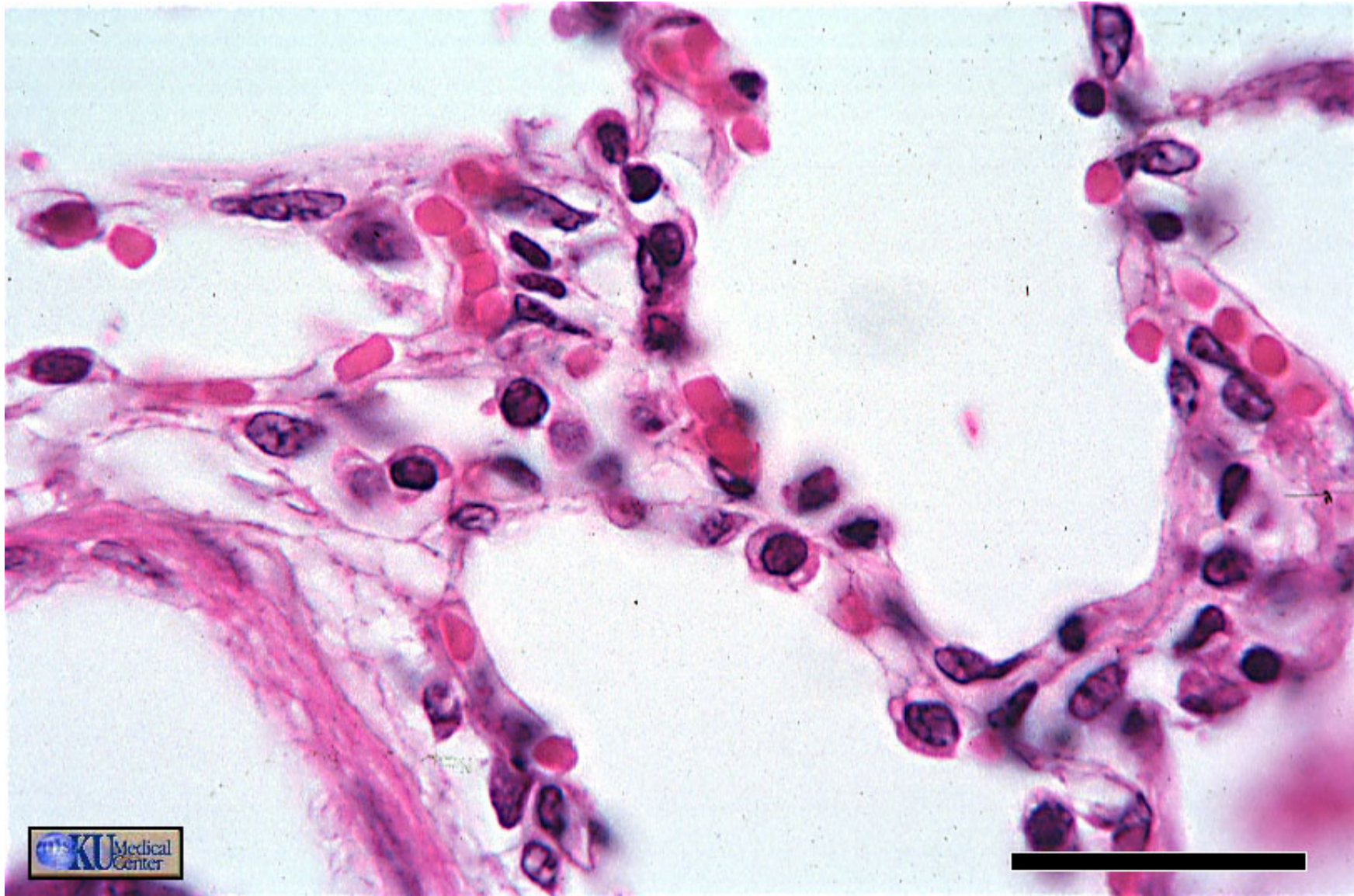The respiratory bronchiole (right) with occasional ciliated cuboidal epithelium interrupted by alveolar openings is the first site of gas exchange.



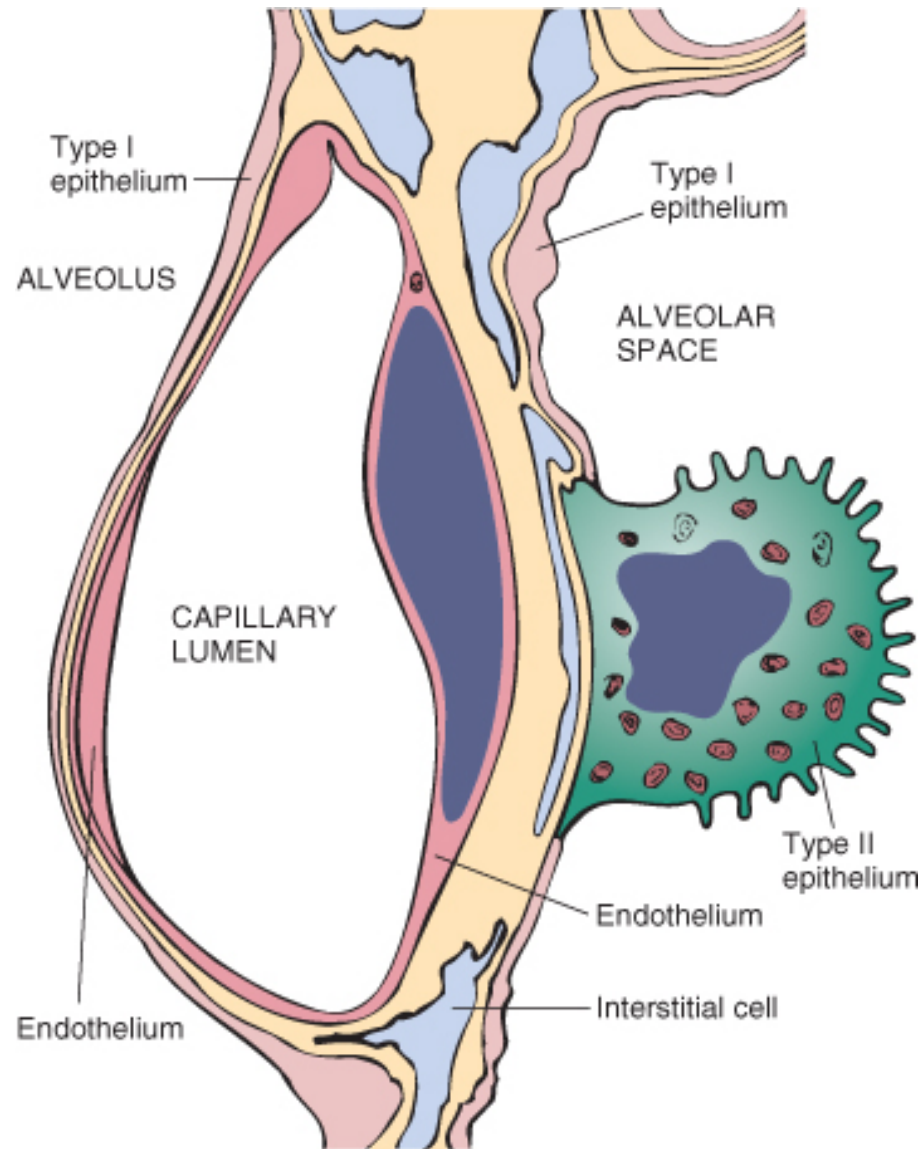
The terminal bronchiole (left) leads to the respiratory bronchiole and finally to the alveolar ducts.



This is normal lung microscopically. The alveolar walls are thin and delicate. The alveoli are well-aerated and contain only an occasional pulmonary macrophage (type II pneumocyte).



The alveoli bring RBCs into close proximity with inspired air.



Microscopic structure of the alveolar wall. Note that the basement membrane (*yellow*) is thin on one side and widened where it is continuous with the interstitial space. Portions of interstitial cells are shown.



Common Approach

- Affecting
 - The airways
 - The interstitium
 - The pulmonary vascular system
- Chronic obstructive pulmonary disease (COPD)
- Acute lung injury
- Pulmonary infections
- Diffuse interstitial (restrictive, infiltrative) lung diseases
- Lung tumors

Chronic Obstructive Pulmonary Diseases (COPD)

- Chronic bronchitis
- Emphysema
- Bronchiectasis
- *Asthma*

Chronic Bronchitis

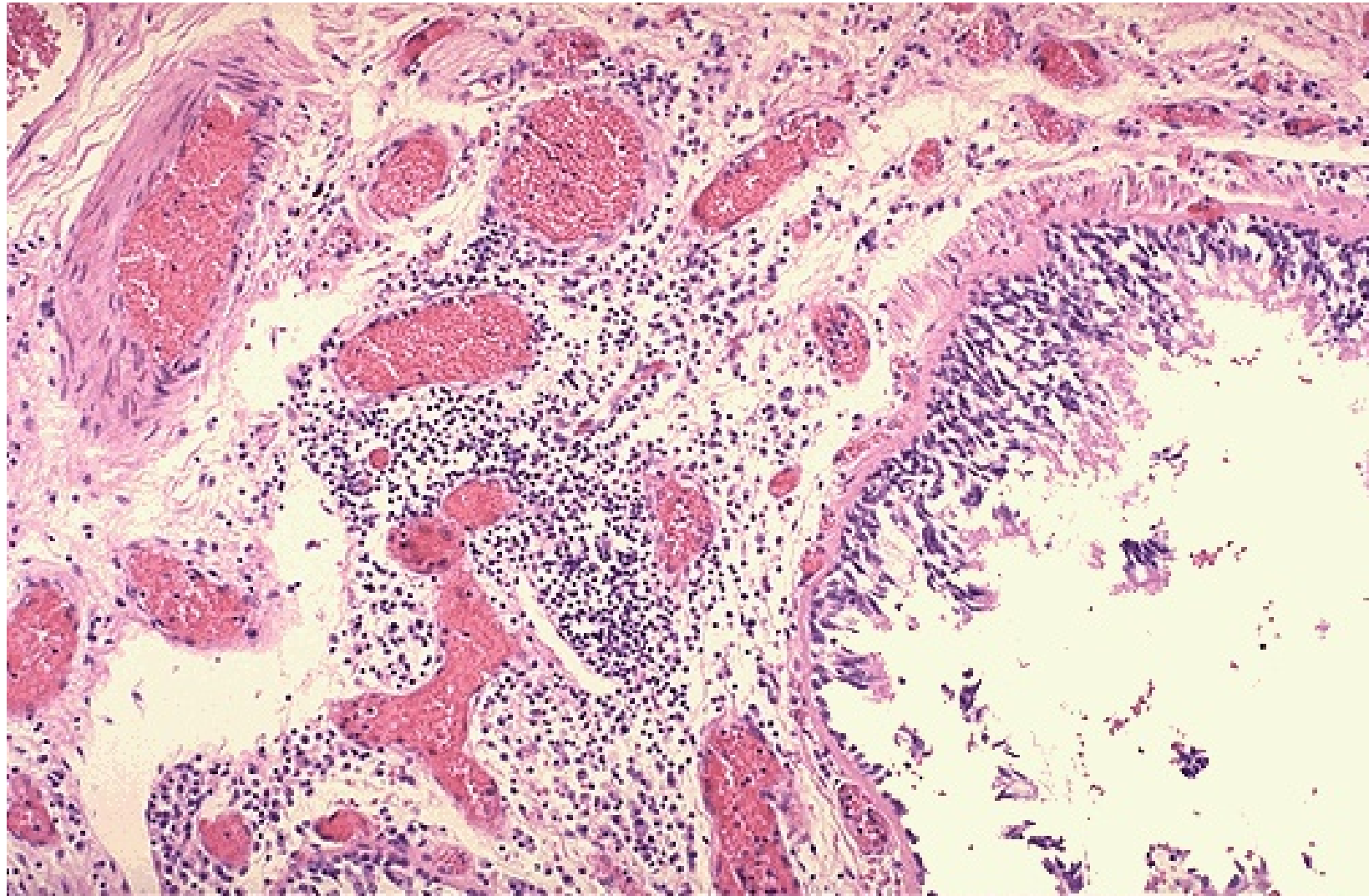
- *Chronic bronchitis* is defined **clinically**. It is present in any patient who has persistent cough with sputum production for **at least 3 months in at least 2 consecutive years**, in the absence of any other identifiable cause.
- (1) Progress to chronic obstructive airway disease
- (2) Lead to cor pulmonale and heart failure
- (3) Cause atypical metaplasia and dysplasia of the respiratory epithelium.

Pathogenesis

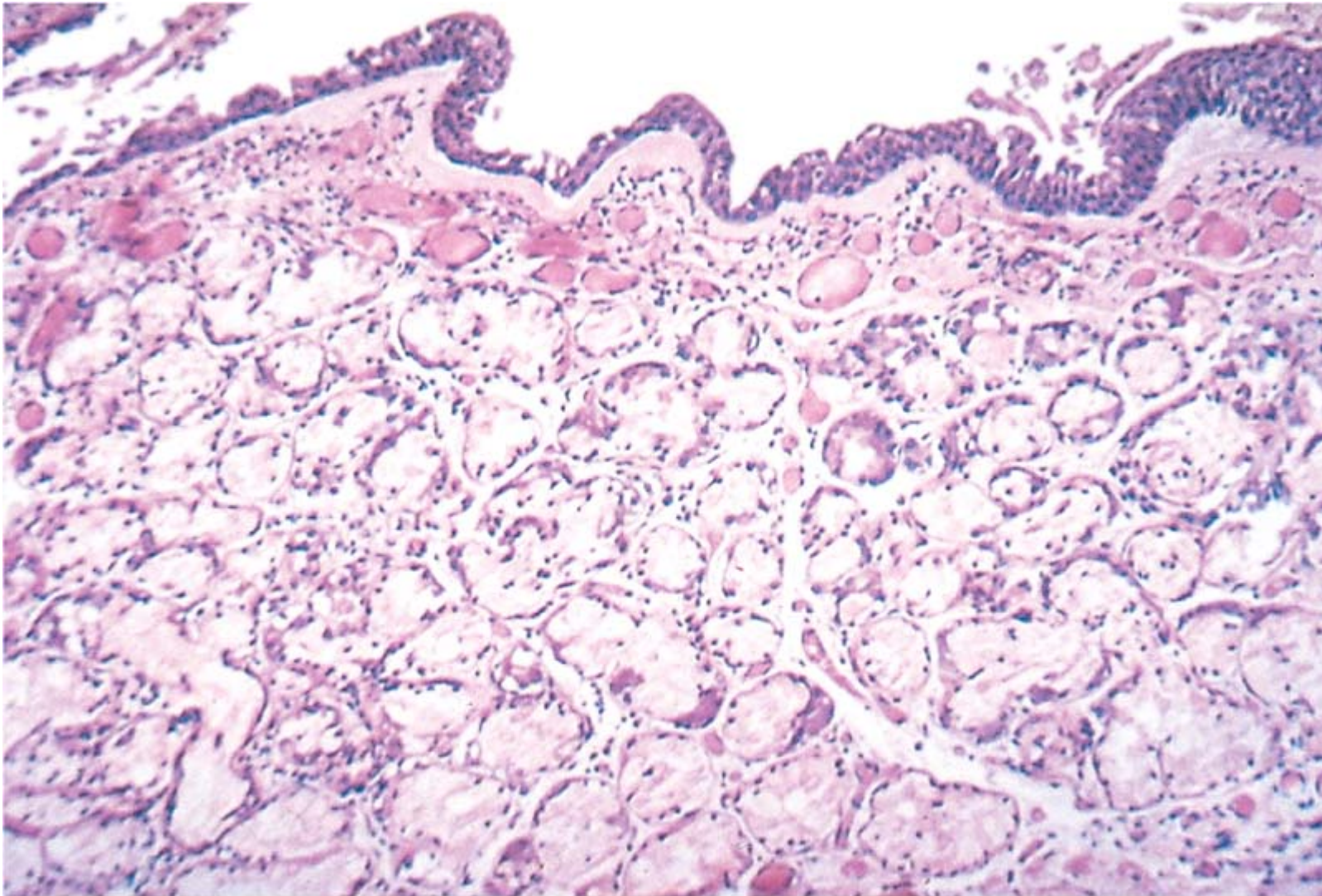
- **Tobacco smoke**
 - 90% of patients are smokers.
- Grain, cotton, and silica dust
- Air pollution
- **Infection**
 - Bacterial and viral infections are important in triggering acute exacerbation of the disease.
- Others

Morphology

- Grossly
 - Hyperemic and swollen
 - Mucinous or mucopurulent secretions
- Histologically
 - Chronic inflammation of the airways (predominantly lymphocytes)
 - **Enlargement of the mucus-secreting glands** in the trachea and larger bronchi
 - Inflammatory cells, largely mononuclear but sometimes admixed with neutrophils
 - Goblet cell metaplasia, mucus plugging, inflammation, and fibrosis (small airway disease, (bronchiolitis obliterans))



This photomicrograph demonstrates a bronchus with increased numbers of chronic inflammatory cells in the submucosa.



© Elsevier. Kumar et al: Robbins Basic Pathology 8e - www.studentconsult.com

Chronic bronchitis. The lumen of the bronchus is above. Note the marked thickening of the mucous gland layer (approximately twice normal) and squamous metaplasia of lung epithelium. (From the teaching collection of the Department of Pathology, University of Texas, Southwestern Medical School, Dallas, Texas.)

Clinical Course

- Prominent cough
- Production of sputum
- Hypercapnia, hypoxemia, and cyanosis
- Pulmonary hypertension and cardiac failure
- Recurrent infections and respiratory failure

Complications

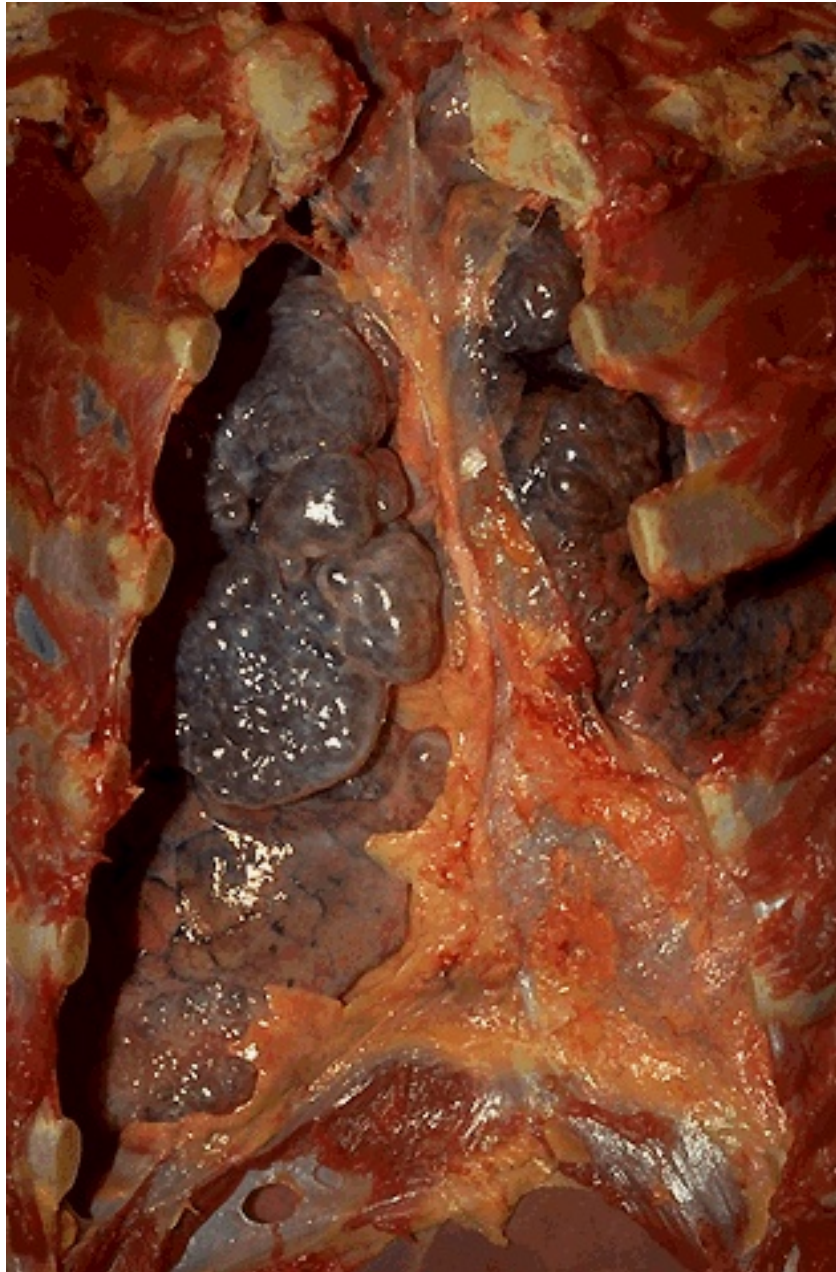- Emphysema
- Cor pulmonale
- Bronchiectasis
- Bronchopneumonia
- Bronchogenic carcinoma of lung

SUMMARY

- Chronic bronchitis is defined as persistent productive cough for at least 3 consecutive months in at least 2 consecutive years.
- Cigarette smoking is the most important underlying risk factor; air pollutants also contribute.
- Chronic obstructive component largely results from small airway disease (chronic bronchiolitis) and coexistent emphysema.
- Histology demonstrates enlargement of mucus-secreting glands, goblet cell metaplasia, and bronchiolar wall fibrosis.

Emphysema

- Definition
 - Emphysema is a condition of the lung characterized by **abnormal permanent enlargement of the airspaces distal to the terminal bronchiole**, accompanied by **destruction of their walls** and without obvious fibrosis.



The chest cavity is opened at autopsy to reveal numerous large bullae apparent on the surface of the lungs in a patient dying with emphysema. Bullae are large dilated airspaces that bulge out from beneath the pleura.

Emphysema is characterized by a loss of lung parenchyma by destruction of alveoli so that there is permanent dilation of airspaces.

Pathogenesis

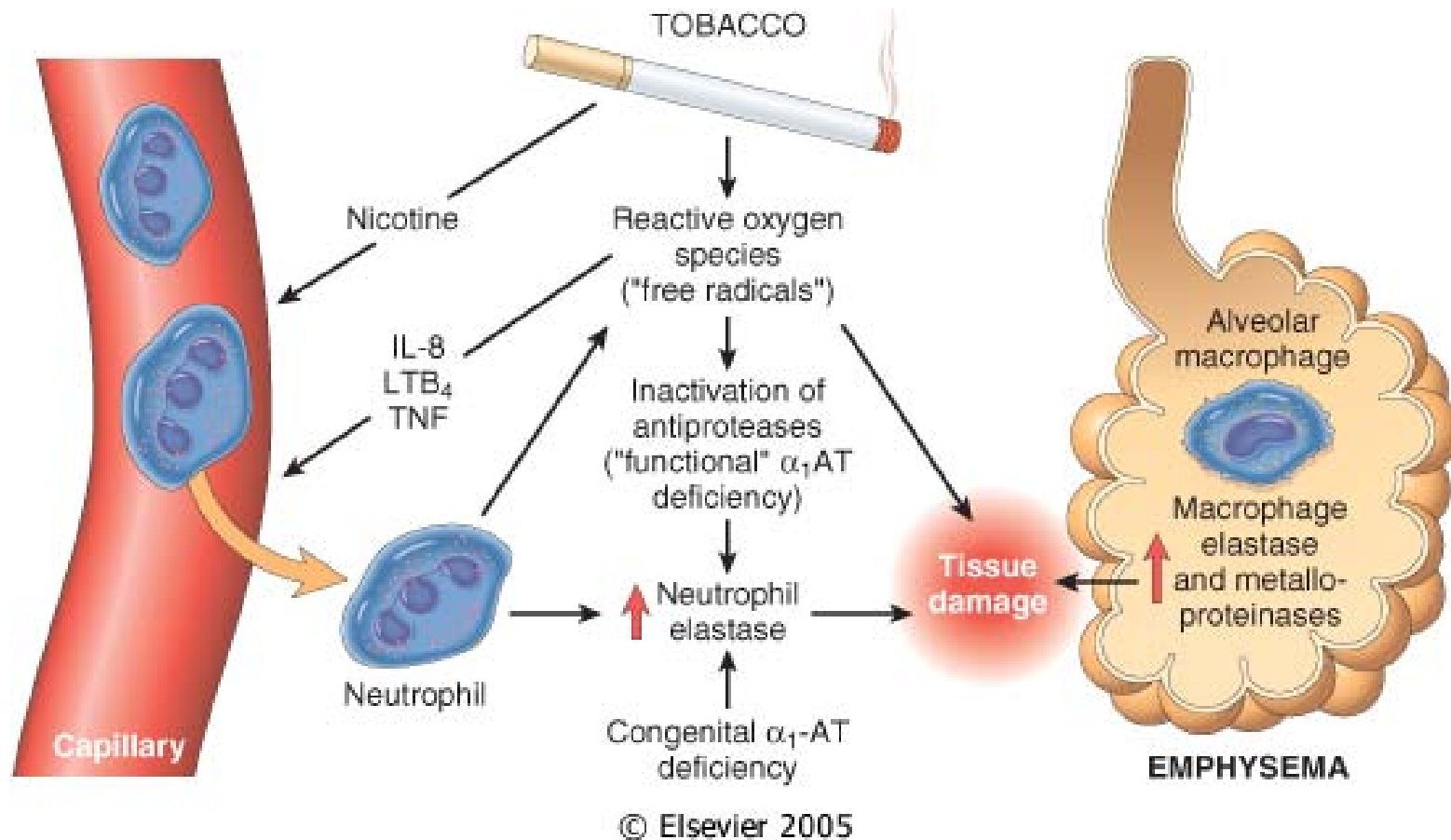
- The genesis of emphysema is not completely understood.
- A consequence of two critical imbalances
 - *The protease-antiprotease imbalance*
 - *Oxidant-antioxidant imbalance*

Protease-Antiprotease Imbalance Hypothesis

- Genetic deficiency of the antiprotease α 1-antitrypsin
- The effect of cigarette smoking in the development of emphysema
 - Increased elastase availability and decreased antielastase activity occur in smokers.
 - Smoking enhances elastase activity in macrophages.

Oxidant-Antioxidant Imbalance

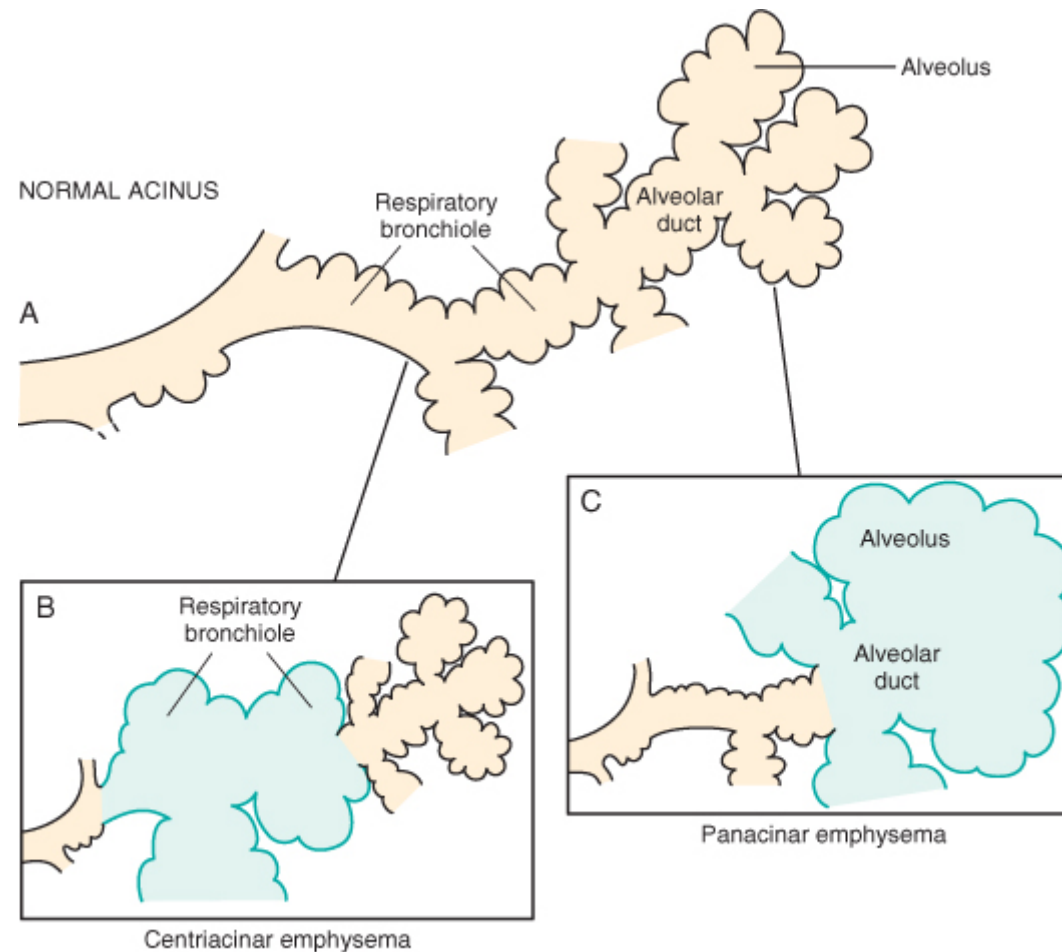
- Tobacco smoke contains abundant reactive oxygen species (free radicals), which deplete these antioxidant mechanisms, thereby inciting tissue damage.
- Tissue breakdown is enhanced as a consequence of inactivation of protective antiproteases by reactive oxygen species in cigarette smoke.



Pathogenesis of emphysema. The protease-antiprotease imbalance and oxidant-antioxidant imbalance are additive in their effects and contribute to tissue damage. α 1-antitrypsin (α 1-AT) deficiency can be either congenital or "functional" as a result of oxidative inactivation.

Types of Emphysema

- According to its *anatomic distribution* within the lobule
- Four major types
 - *Centriacinar*
 - *Panacinar*
 - *Paraseptal*
 - *Irregular*
- Only the first two cause clinically significant airflow obstruction.



© Elsevier 2005

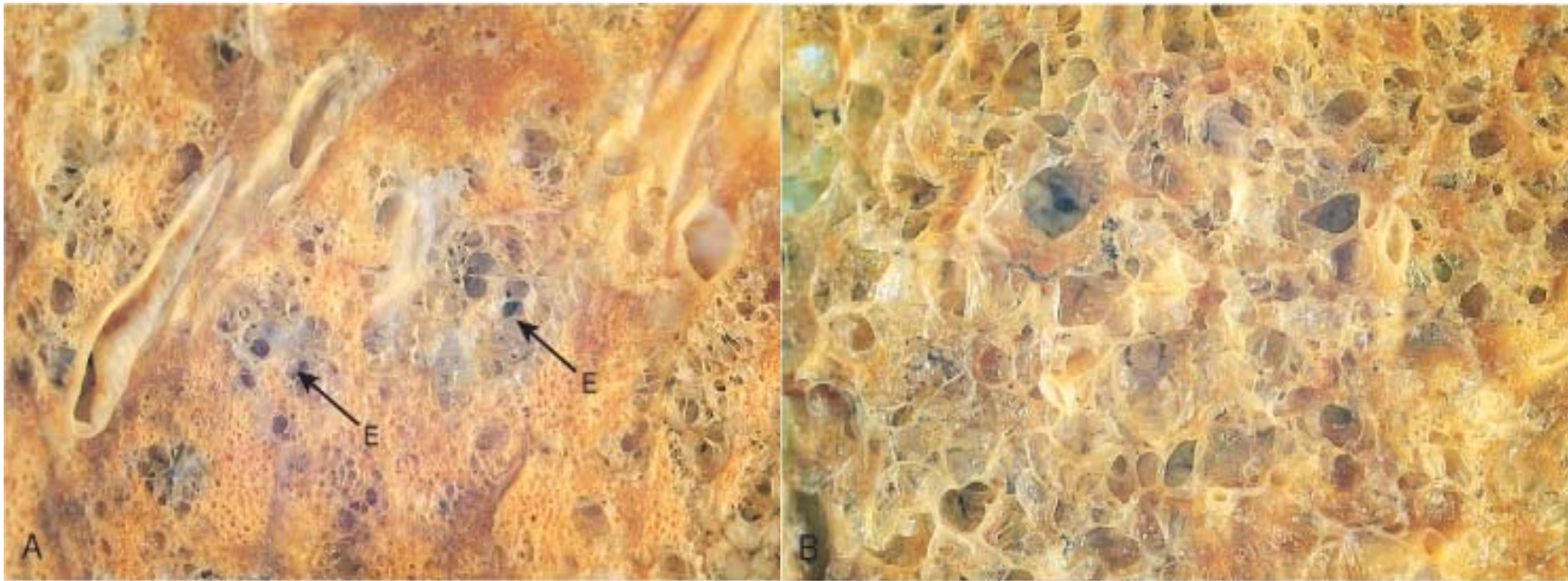
A, Diagram of normal structures within the acinus, the fundamental unit of the lung. A terminal bronchiole (*not shown*) is immediately proximal to the respiratory bronchiole. B, Centriacinar emphysema with dilation that initially affects the respiratory bronchioles. C, Panacinar emphysema with initial distention of the peripheral structures (i.e., the alveolus and alveolar duct); the disease later extends to affect the respiratory bronchioles.

Centriacinar (Centrilobular) Emphysema

- The central or proximal parts of the acini, formed by respiratory bronchioles, are affected, whereas distal alveoli are spared.
- The lesions are more common and severe in the upper lobes, particularly in the apical segments.
- Centriacinar emphysema occurs predominantly in heavy smokers, often in association with chronic bronchitis.

Panacinar (Panlobular) Emphysema

- The acini are uniformly enlarged from the level of the respiratory bronchiole to the terminal blind alveoli.
- Tends to occur more commonly in the lower zones and in the anterior margins of the lung, and it is usually most severe at the bases.
- This type of emphysema is associated with α 1-*antitrypsin* (*α 1-AT*) deficiency.



A, Centriacinar emphysema. Central areas show marked emphysematous damage (E), surrounded by relatively spared alveolar spaces. B, Panacinar emphysema involving the entire pulmonary architecture.



This is a more subtle appearance for centrilobular emphysema in which there are "dirty holes" that appear focally where the central portions of lung acini have lost lung parenchyma while collecting anthracotic pigment at the same time. This pattern is typical for smokers.



On cut section of the lung, the dilated airspaces with emphysema are seen. Although there tends to be some scarring with time because of superimposed infections, the emphysematous process is one of loss of lung parenchyma, not fibrosis. This pattern is typical for alpha-1-antitrypsin deficiency.

Distal Acinar (Paraseptal) Emphysema

- The proximal portion of the acinus is normal, but the distal part is predominantly involved.
- The characteristic findings are of multiple, continuous, enlarged airspaces from less than 0.5 cm to more than 2.0 cm in diameter, sometimes forming cystlike structures.
- This type of emphysema probably underlies many of the cases of spontaneous pneumothorax in young adults.

Airspace Enlargement with Fibrosis (Irregular Emphysema)

- The most common form of emphysema
 - Autopsy shows one or more scars from a healed inflammatory process.
 - In most instances, these foci of irregular emphysema are asymptomatic and clinically insignificant.

Interstitial Emphysema

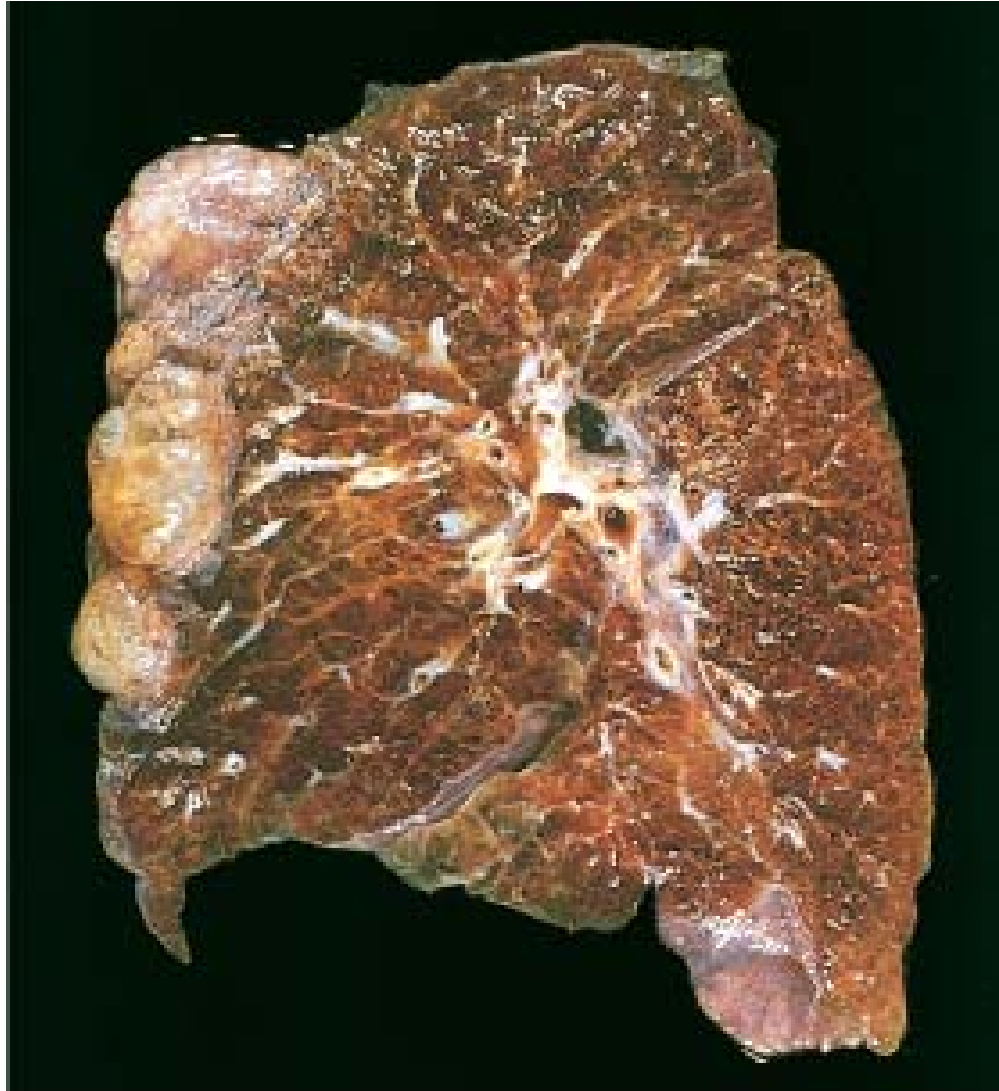- The entrance of air into the connective tissue stroma of the lung, mediastinum, or subcutaneous tissue.
 - Wound of the chest
 - Children with whooping cough and bronchitis,
 - Patients with obstruction to the airways

Compensatory Hyperinflation (Emphysema)

- Surgical removal of a diseased lung or lobe.
- Designate dilation of alveoli but not destruction of septal walls.

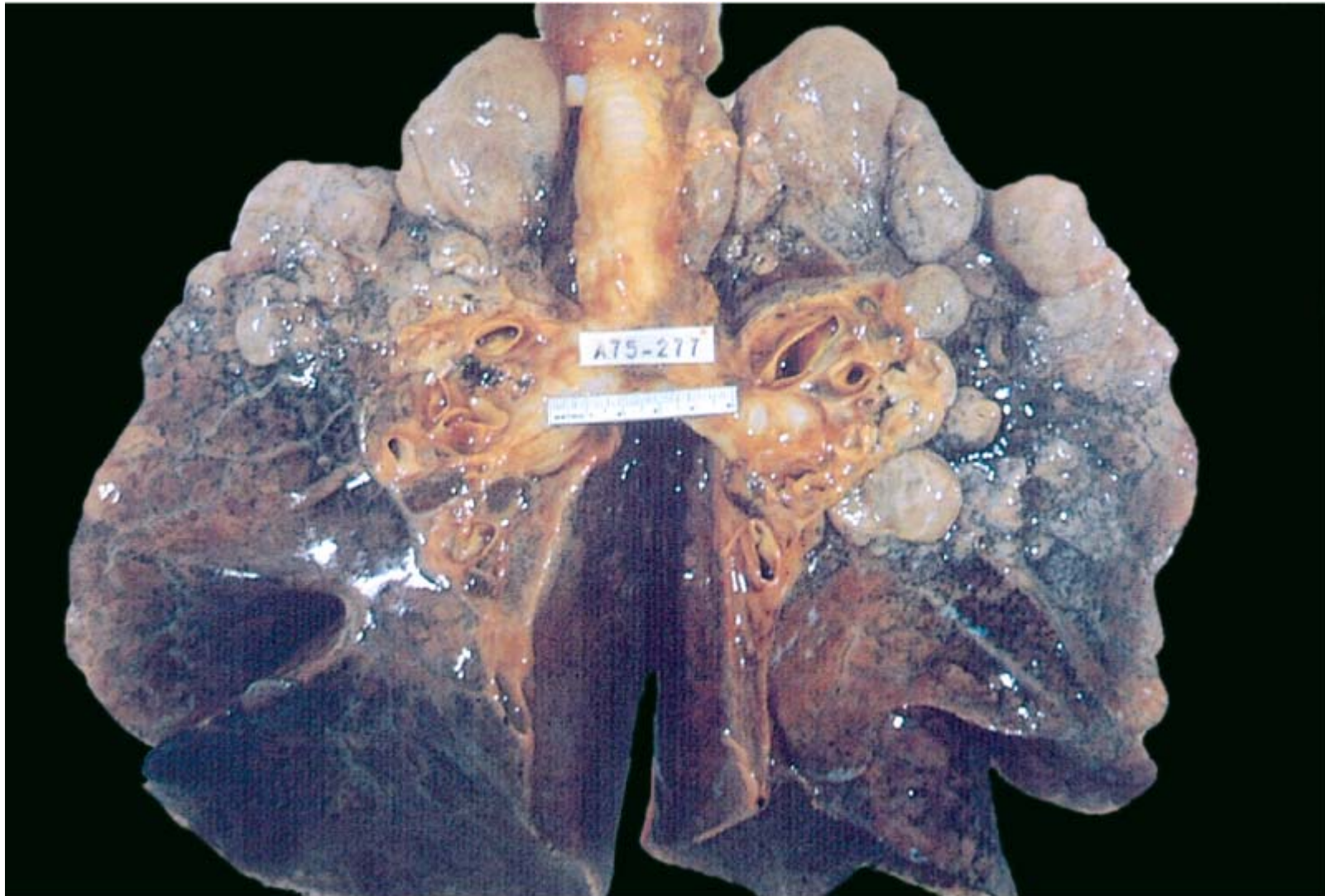
Bullous Emphysema

- Produces large subpleural blebs or bullae (spaces more than 1 cm in diameter in the distended state)
- Most often subpleural, and occur near the apex
- Pneumothorax



© Elsevier 2005

Bullous emphysema with large subpleural bullae (*upper left*).



© Elsevier. Kumar et al: Robbins Basic Pathology 8e - www.studentconsult.com

Bullous emphysema with large apical and subpleural bullae. (From the teaching collection of the Department of Pathology, University of Texas Southwestern Medical School, Dallas, Texas.)

Morphology

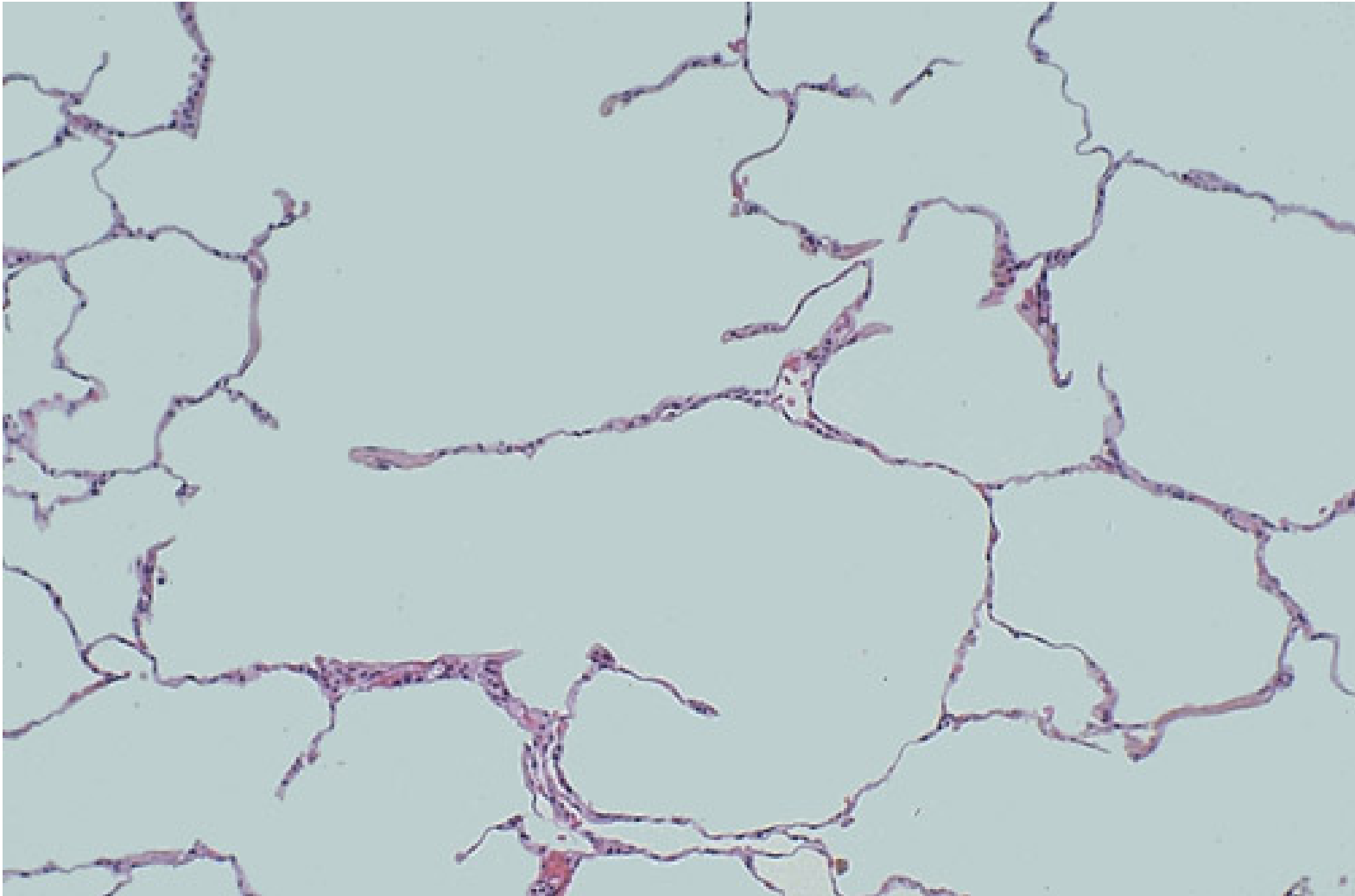
- The diagnosis and classification of emphysema depend largely on the macroscopic appearance of the lung.
- **Panacinar emphysema**
 - Produces pale, voluminous lungs that often obscure the heart when the anterior chest wall is removed at autopsy.
- **Centriacinar emphysema**
 - The upper two-thirds of the lungs is more severely affected than the lower lungs.

Morphology

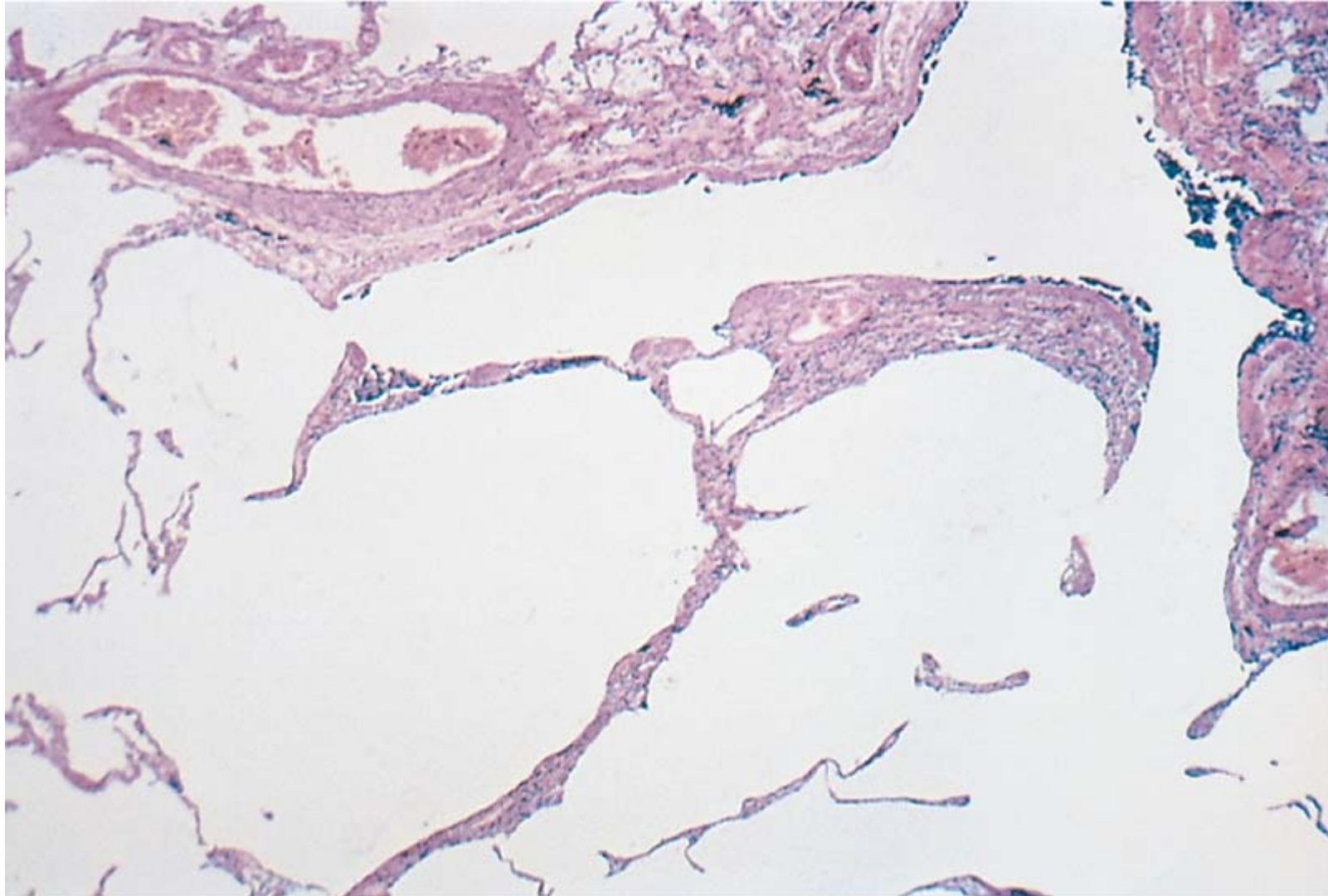
- **Distal Acinar (Paraseptal) Emphysema**
 - Adjacent to the pleurabullae
 - Spontaneous pneumothorax
- **Irregular Emphysema**
 - *The acinus is irregularly involved, is almost invariably associated with scarring*

Microscopy

- Thinning and destruction of alveolar walls
- Adjacent alveoli become confluent, creating large airspaces
- Loss of elastic tissue in the surrounding alveolar septa
- The number of alveolar capillaries is diminished.



Microscopically at high magnification, the loss of alveolar walls with emphysema is demonstrated. Remaining airspaces are dilated.



© Elsevier. Kumar et al: Robbins Basic Pathology 8e - www.studentconsult.com

Pulmonary emphysema. There is marked enlargement of airspaces, with thinning and destruction of alveolar septa. (From the teaching collection of the Department of Pathology, University of Texas Southwestern Medical School, Dallas, Texas.)

Clinical Course

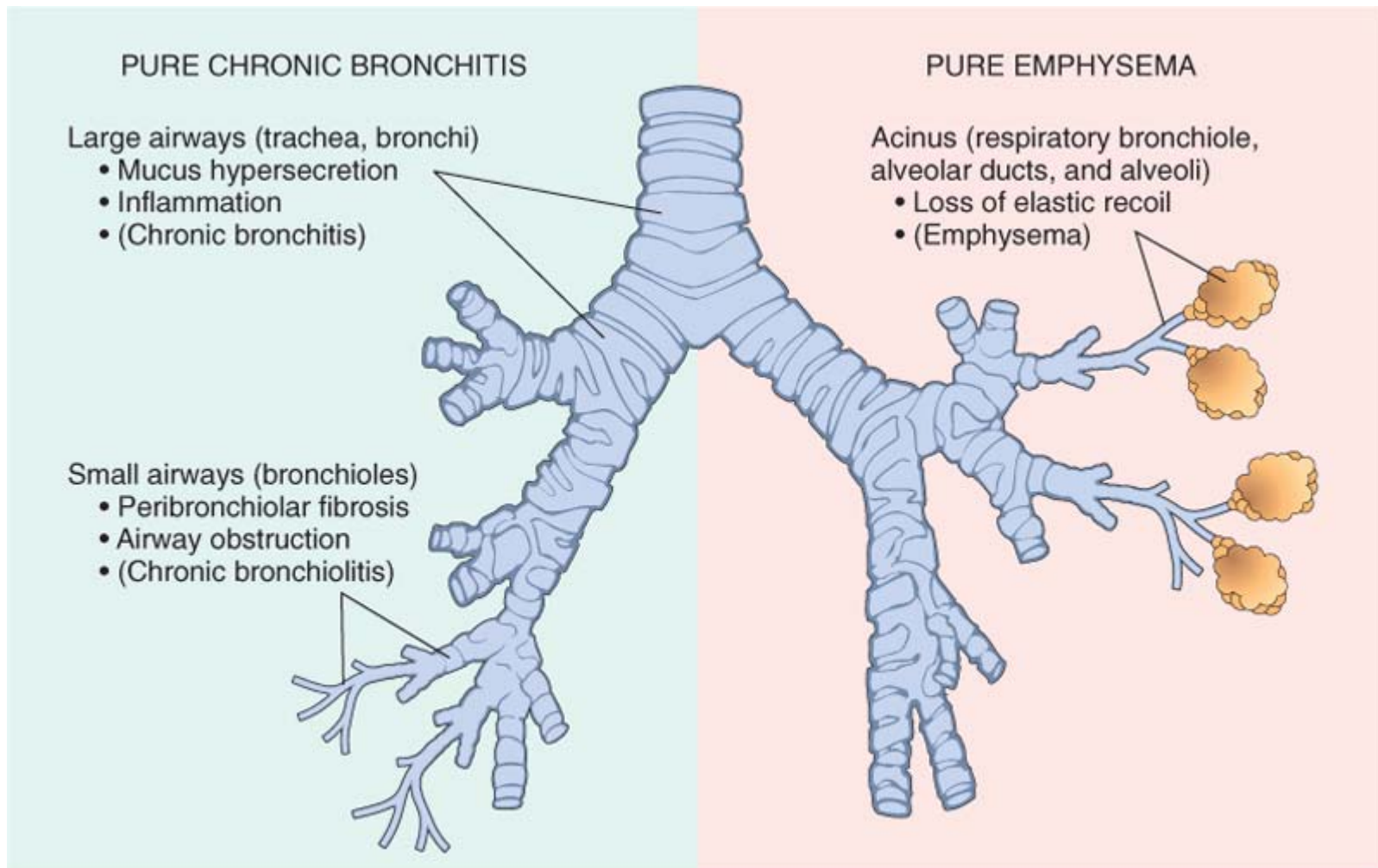
- *Dyspnea* is usually the first symptom
- Steadily progressive
- Cough and wheezing
- Weight loss
- Pulmonary function tests
 - The ratio of FEV1 to FVC is reduced

Complications

- Cor pulmonale
- Pneumothorax
- Respiratory failure

SUMMARY

- Emphysema is a chronic obstructive airway disease characterized by permanent enlargement of airspaces distal to terminal bronchioles.
- Subtypes include centriacinar (most common; smoking related), panacinar (seen in α 1-antitrypsin deficiency), distal acinar, and irregular.
- The two key pathogenic mechanisms are an excess of cellular proteases with low antiprotease levels (protease-antiprotease imbalance), and an excess of reactive oxygen species (oxidant-antioxidant imbalance).
- Most individuals with emphysema demonstrate elements of chronic bronchitis concurrently, since cigarette smoking is an underlying risk factor for both.



© Elsevier. Kumar et al: Robbins Basic Pathology 8e - www.studentconsult.com

Anatomic distribution of pure chronic bronchitis and pure emphysema. In chronic bronchitis the small-airway disease (chronic bronchiolitis) results in airflow obstruction, while the large-airway disease is primarily responsible for the mucus hypersecretion.

Bronchiectasis

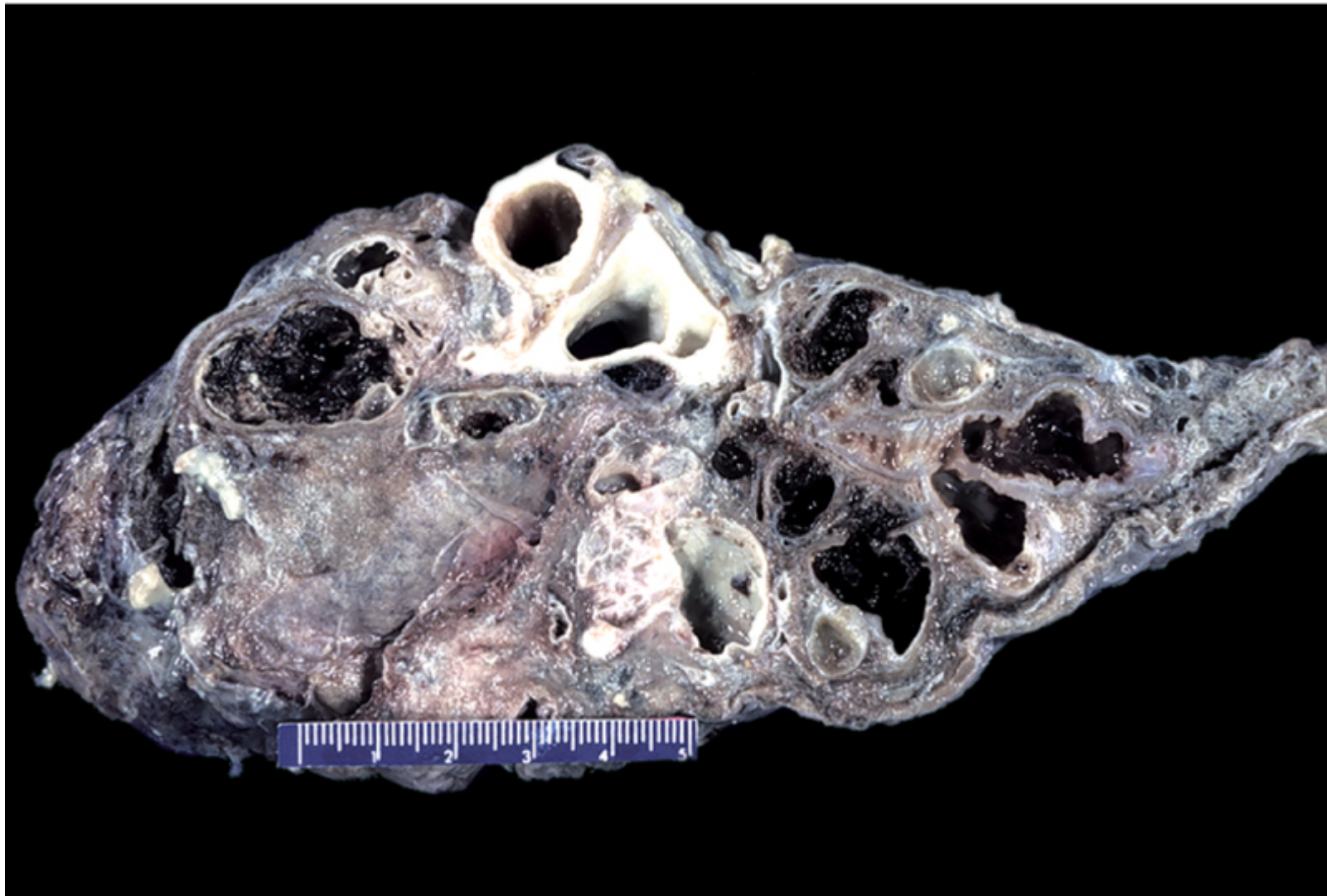
- The permanent dilation of bronchi and bronchioles caused by destruction of the muscle and elastic supporting tissue.
- Resulting from or associated with chronic necrotizing infections.
- Cough and expectoration of copious amounts of purulent sputum

Pathogenesis

- *Obstruction*
- *Chronic persistent infection*
 - Damage to bronchial walls, leading to weakening and dilation.
 - Obstructive secretions, inflammation throughout the wall

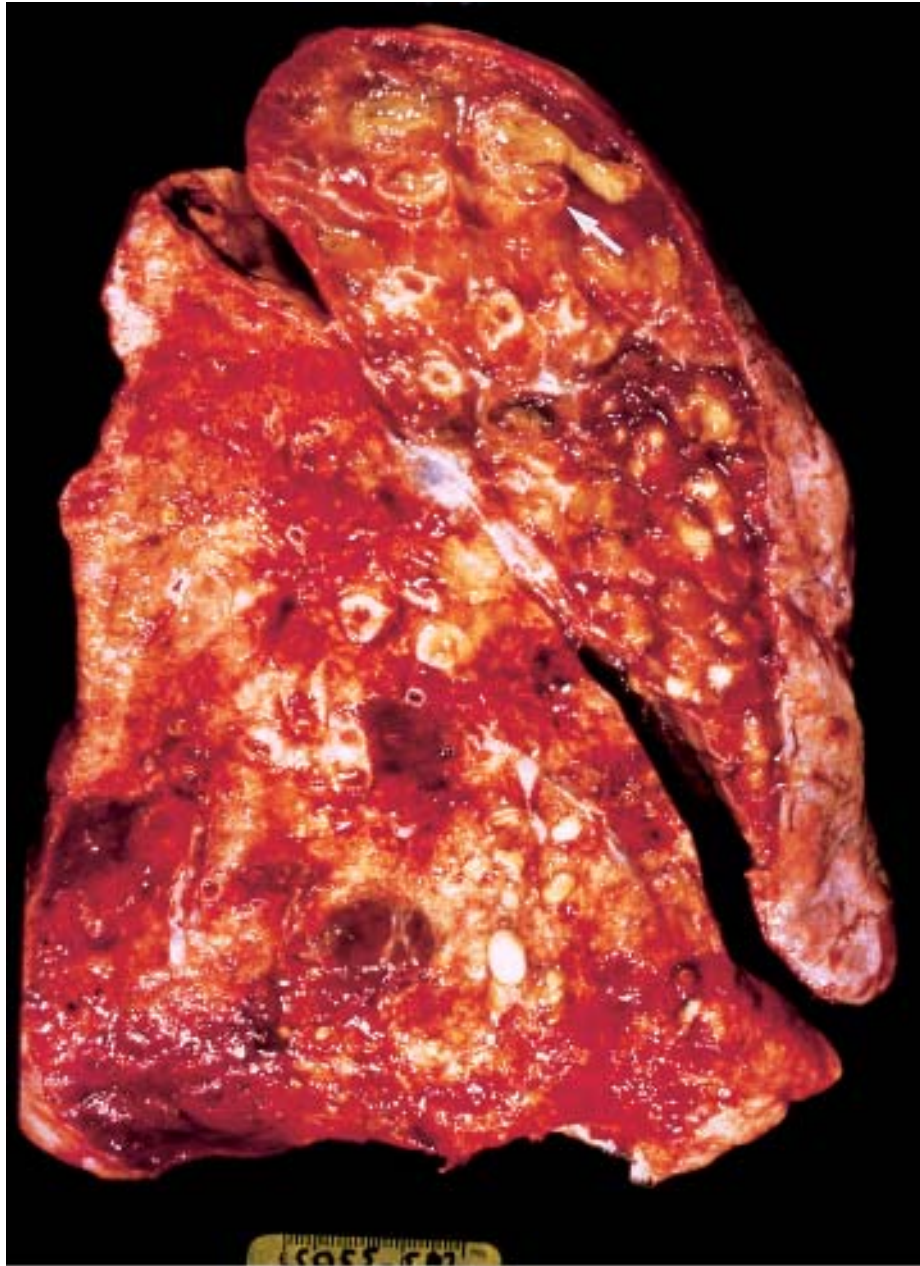
Morphology

- Affects the **lower lobes** bilaterally
- The airways dilated
- Histologically
 - Intense acute and chronic inflammatory exudate within the walls of the bronchi and bronchioles
 - The desquamation of lining epithelium cause extensive areas of ulceration
 - Fibrosis of the bronchial and bronchiolar walls and peribronchiolar fibrosis

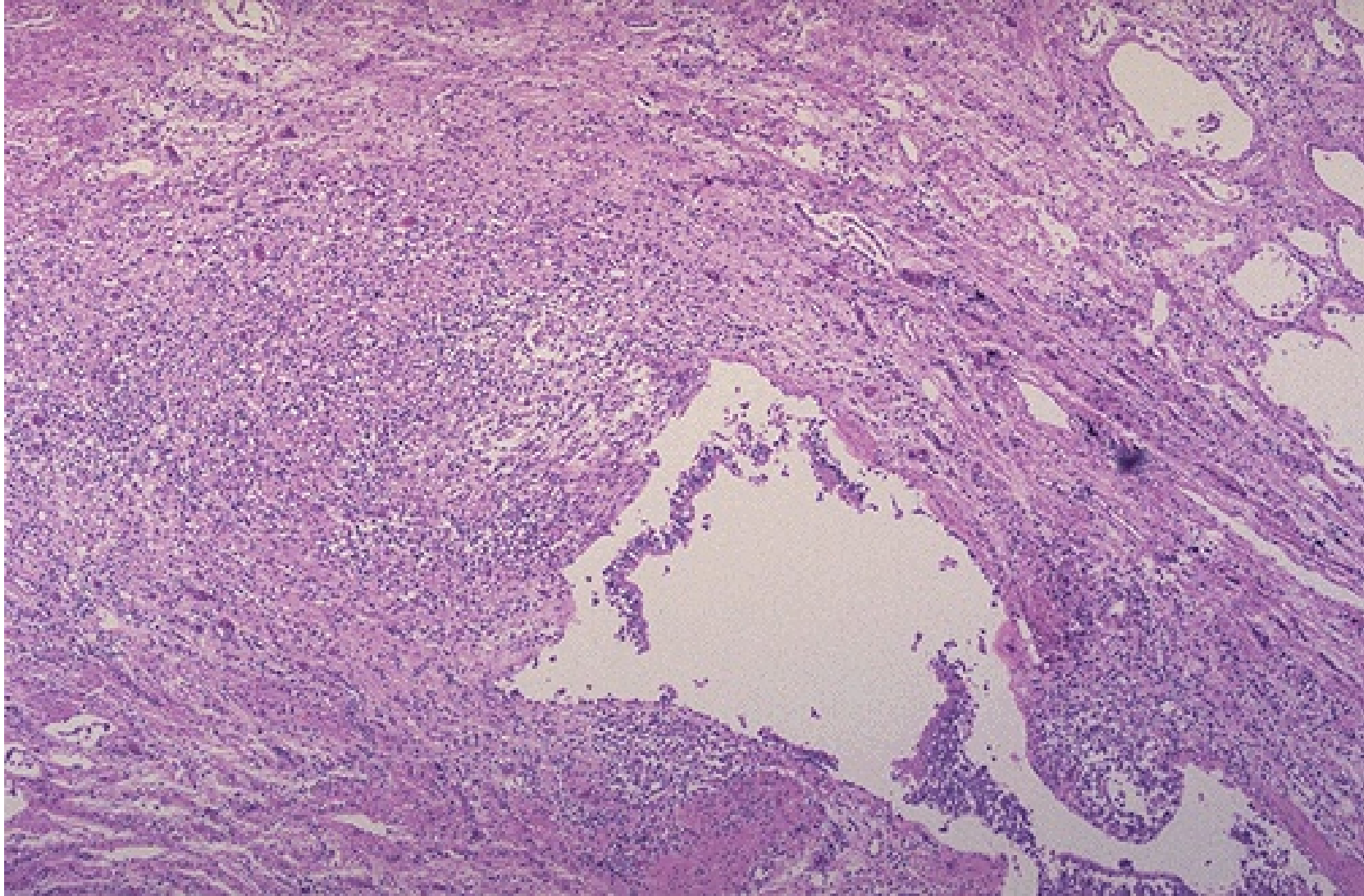


© Elsevier. Kumar et al: Robbins Basic Pathology 8e - www.studentconsult.com

Bronchiectasis. Cross-section of lung demonstrating dilated bronchi extending almost to the pleura. (Courtesy of Dr. Linda Margraf, Department of Pathology, University of Texas Southwestern Medical School, Dallas, Texas.)



Bronchiectasis in a patient with cystic fibrosis, who underwent lung transplantation. Cut surface of lung shows markedly distended peripheral bronchi filled with mucopurulent secretions.



This is the microscopic appearance of bronchiectasis. Bronchiectasis is not a specific disease, but a consequence of another disease process that destroys airways.

Clinical Course

- Severe, persistent cough with expectoration of mucopurulent
 - Fetid, sputum.
 - The sputum may contain flecks of blood
- Hypoxemia, hypercapnia, pulmonary hypertension, and (rarely) cor pulmonale.

Complications

- Lung abscess
- Pyemia--metastatic abscesses
- Pulmonary fibrosis
- Cor pulmonale

The Spectrum of Chronic Obstructive Pulmonary Disease

Clinical Term	Anatomic Site	Major Pathologic Changes	Etiology	Signs/Symptoms
Chronic bronchitis	Bronchus	Mucous gland hyperplasia, hypersecretion	Tobacco smoke, air pollutants	Cough, sputum production
Bronchiectasis	Bronchus	Airway dilation and scarring	Persistent or severe infections	Cough, purulent sputum, fever
Emphysema	Acinus	Airspace enlargement; wall destruction	Tobacco smoke	Dyspnea
<i>Asthma</i>	<i>Bronchus</i>	<i>Smooth muscle hyperplasia, excess mucus, inflammation</i>	<i>Immunologic or undefined causes</i>	<i>Episodic wheezing, cough, dyspnea</i>

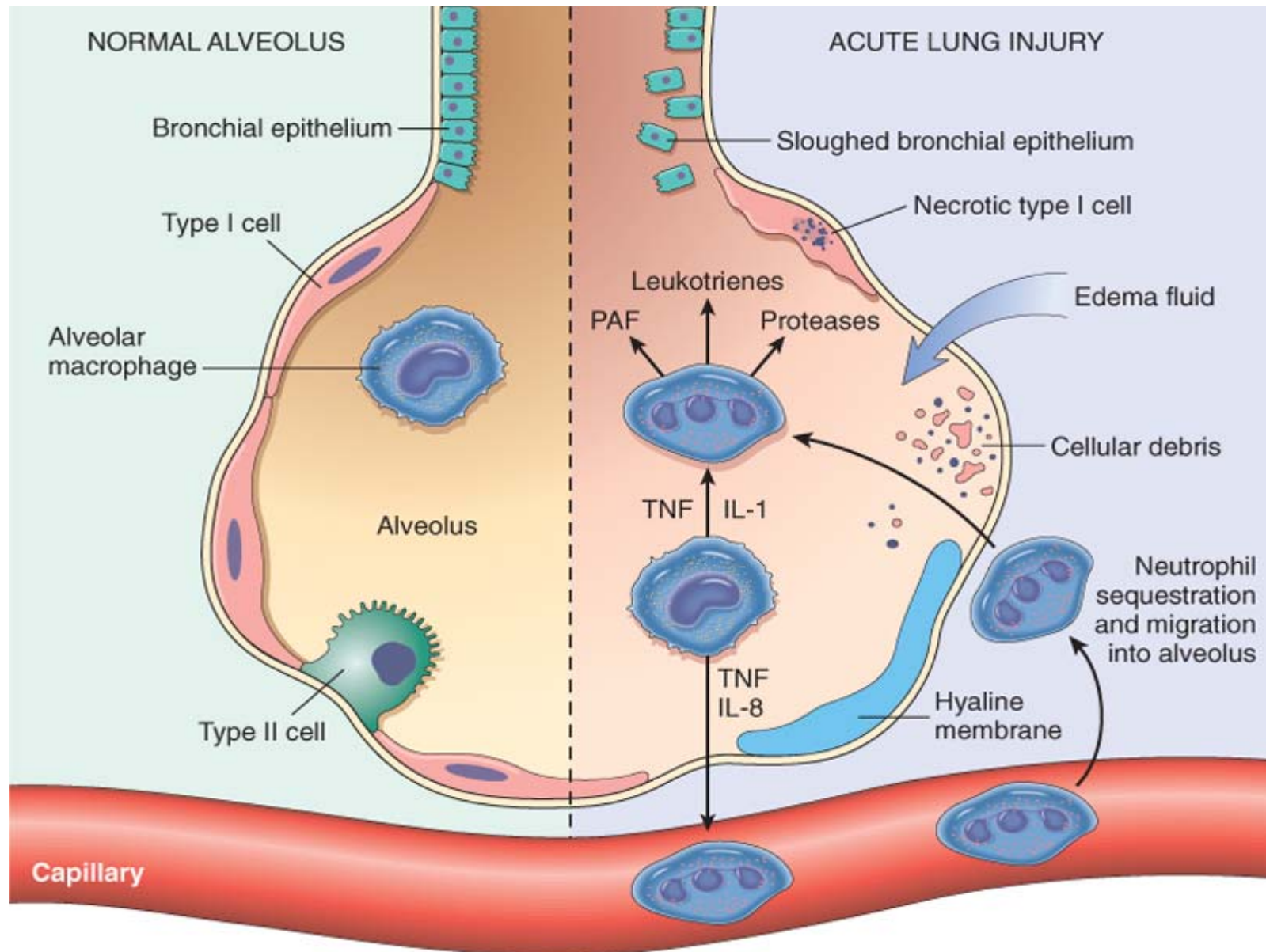


Acute Respiratory Distress Syndrome (ARDS)

- ARDS is a clinical syndrome caused by diffuse alveolar capillary and epithelial damage.
 - Rapid onset of severe life-threatening respiratory insufficiency
 - Cyanosis
 - Severe arterial hypoxemia
 - Extrapulmonary multisystem organ failure
- Diffuse alveolar damage (DAD)

Pathogenesis

- Diffuse damage to the alveolar capillary walls
 - Capillary endothelium
 - Increased vascular permeability
 - Alveolar flooding
 - Loss of diffusion capacity
 - Widespread surfactant abnormalities



© Elsevier. Kumar et al: Robbins Basic Pathology 8e - www.studentconsult.com

The normal alveolus (*left*) compared with the injured alveolus in the early phase of acute lung injury and the acute respiratory distress syndrome.

Clinical Disorders Associated with the Development of Acute Respiratory Distress Syndrome

Direct Lung Injury

Indirect Lung Injury

Common Causes

Pneumonia

Sepsis

Aspiration of gastric contents

Severe trauma with shock

Uncommon Causes

Pulmonary contusion

Cardiopulmonary bypass

Fat embolism

Acute pancreatitis

Near-drowning

Drug overdose

Inhalational injury

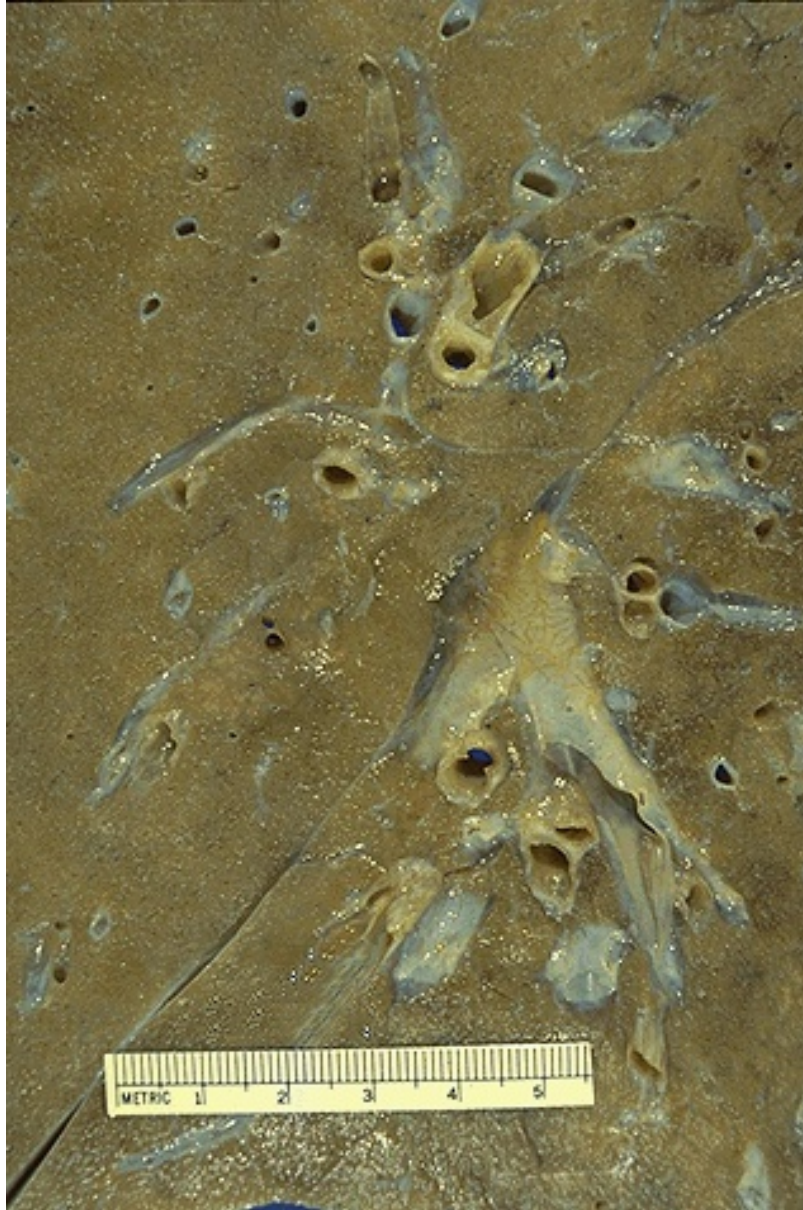Transfusion of blood products

Reperfusion injury after lung transplantation

Uremia

Morphology

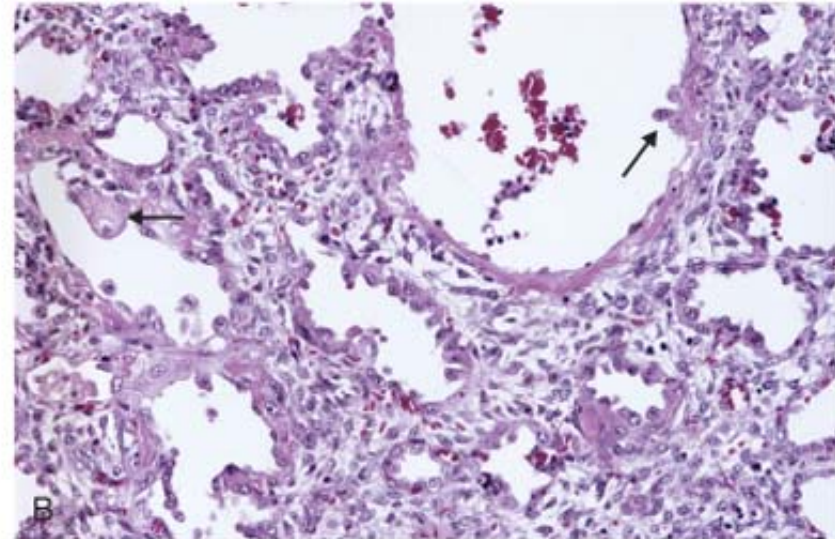
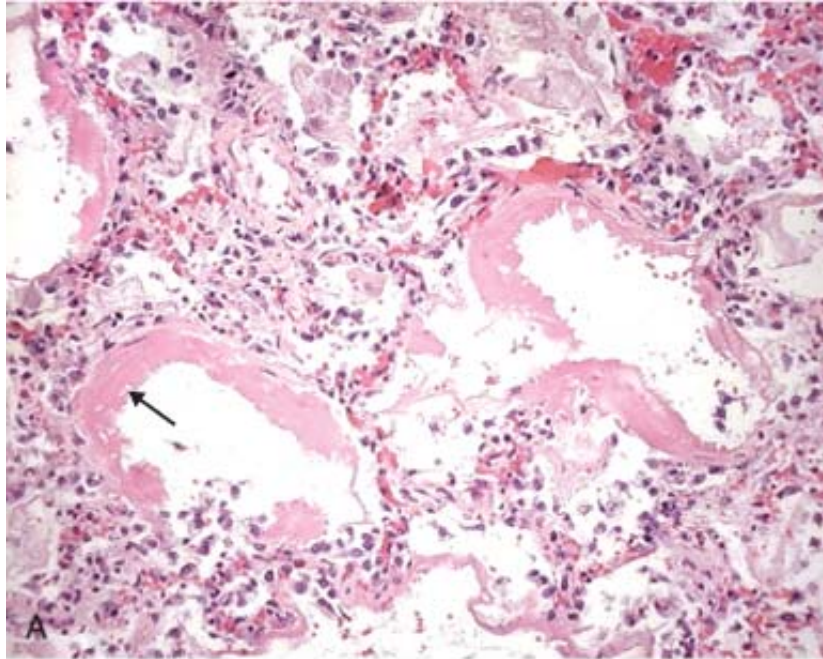
- Heavy, firm, red, and boggy
- Congestion, interstitial and intra-alveolar edema, inflammation, and fibrin deposition
 - Hyaline membrane
 - Morphologically similar to those seen in hyaline membrane disease of neonates



Here is an example of diffuse alveolar damage in which the lung is diffusely firm and rubbery. Clinically, this is known as adult respiratory distress syndrome (ARDS).

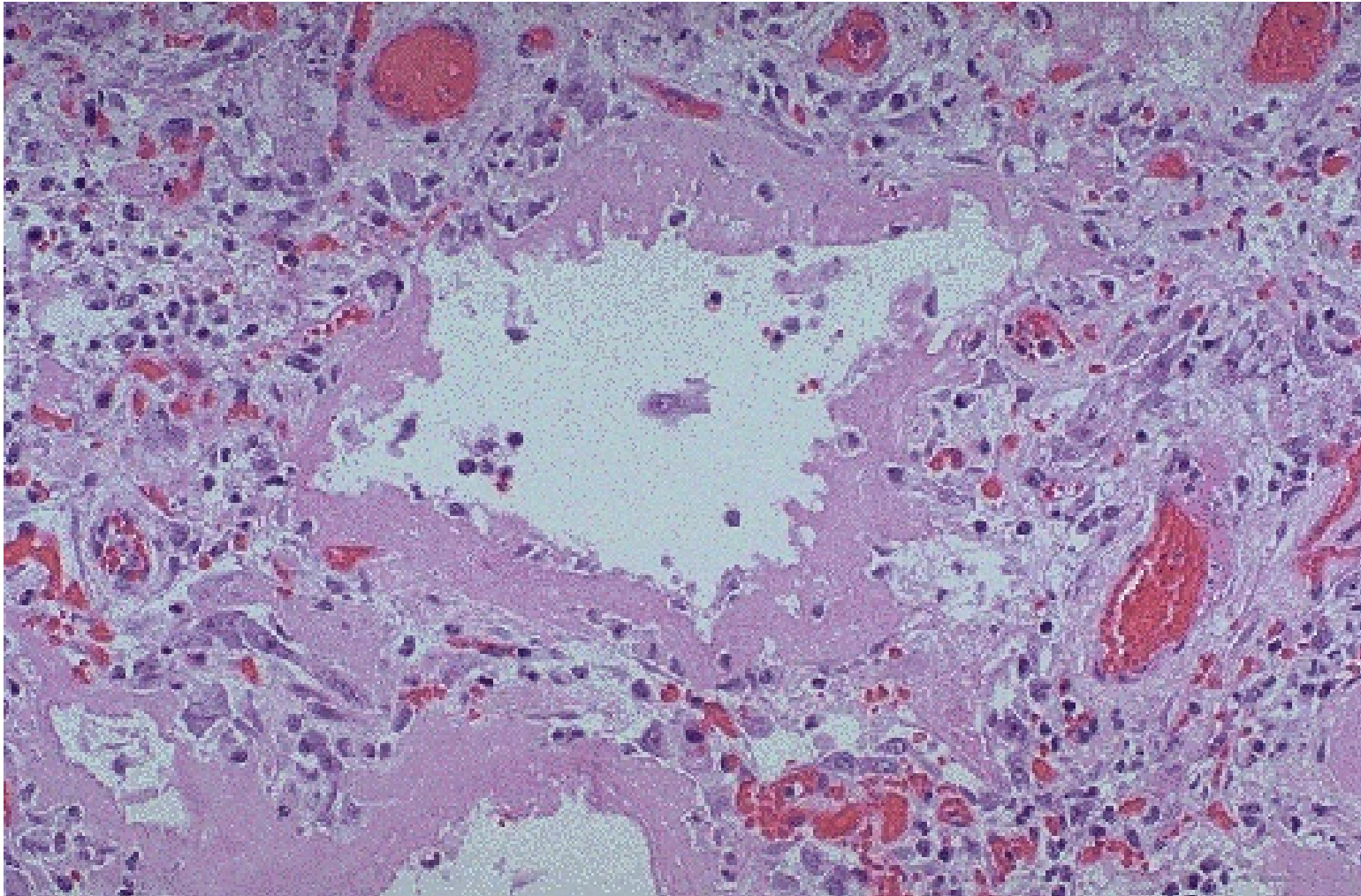


Regardless of the etiology for restrictive lung diseases, many eventually lead to extensive fibrosis. The gross appearance, as seen here in a patient with organizing diffuse alveolar damage, is known as "honeycomb" lung because of the appearance of the irregular air spaces between bands of dense fibrous connective tissue.



© Elsevier. Kumar et al: Robbins Basic Pathology 8e - www.studentconsult.com

A, Diffuse alveolar damage in acute lung injury and ARDS. Some alveoli are collapsed; others are distended. Many are lined by bright pink hyaline membranes (*arrow*). **B**, In the healing stage there is resorption of hyaline membranes with thickened alveolar septa containing inflammatory cells, fibroblasts, and collagen. Numerous atypical type II pneumocytes are seen at this stage (*arrows*), associated with regeneration and repair.



This is the microscopic appearance of diffuse alveolar damage (DAD) in the lung. DAD is simply the final common pathway for a variety of severe lung injuries. In early DAD, there are hyaline membranes, as seen here, lining alveoli. Later, type II pneumocyte proliferation and then interstitial inflammation and fibrosis are seen. High oxygen tensions needed to treat the hypoxia resulting from DAD and its etiologies further potentiates this disease.

Clinical Course

- Profound dyspnea and tachypnea
- Increasing cyanosis and hypoxemia, respiratory failure
- Respiratory acidosis
- Despite improvements in supportive therapy, the mortality rate among the 150,000 ARDS cases seen yearly in the United States is still about 60%.
 - Advanced age
 - Bacteremia (sepsis)
 - The development of multisystem failure

SUMMARY

- ARDS is a clinical syndrome of progressive respiratory insufficiency caused by diffuse alveolar damage in the setting of sepsis, severe trauma, and diffuse pulmonary infections.
- There is an imbalance of pro- and anti-inflammatory mediators causing acute inflammatory injury to the alveolar epithelium and capillary endothelium.
- Neutrophils and their products have a crucial role in the pathogenesis of ARDS.
- The characteristic histologic picture is that of alveolar edema, epithelial necrosis, accumulation of neutrophils, and presence of hyaline membranes lining the alveolar ducts.



Pulmonary Infections

- Pneumonia can result whenever these **defense mechanisms** are impaired or whenever the **resistance of the host** in general is lowered.
 - *Loss or suppression of the cough reflex*
 - *Injury to the mucociliary apparatus*
 - *Interference with the phagocytic or bactericidal action of alveolar macrophages*
 - *Pulmonary congestion and edema*
 - *Accumulation of secretions*

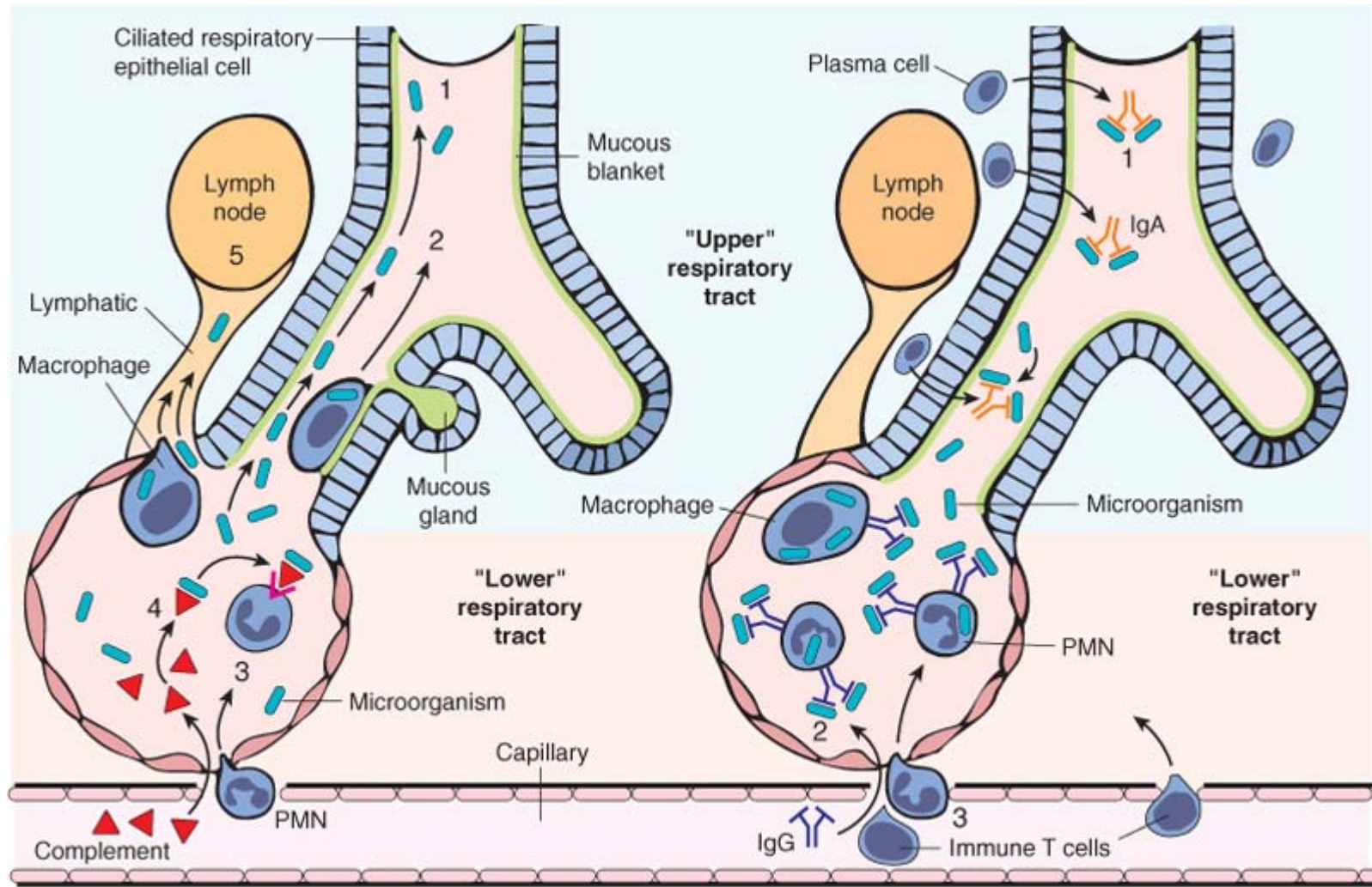
Pulmonary Host Defenses

Location	Host Defense Mechanism
Upper Airways	
Nasopharynx	Nasal hair
	Turbinates
	Mucociliary apparatus
	Immunoglobulin A (IgA) secretion
Oropharynx	Saliva
	Sloughing of epithelial cells
	Local complement production
	Interference from resident flora

Reproduced from Mandell GL, et al. (eds): Mandell, Douglas and Bennett's Principles and Practice of Infectious Diseases, 5th ed. Philadelphia, Churchill Livingstone, p 718.

Pulmonary Host Defenses

Conducting Airways	
Trachea, bronchi	Cough, epiglottic reflexes
	Sharp-angled branching of airways
	Mucociliary apparatus
	Immunoglobulin production (IgG, IgM, IgA)
Lower Respiratory Tract	
Terminal airways, alveoli	Alveolar lining fluid (surfactant, Ig, complement, fibronectin)
	Cytokines (interleukin 1, tumor necrosis factor)
	Alveolar macrophages
	Polymorphonuclear leukocytes
	Cell-mediated immunity



A. INNATE IMMUNE DEFENSES

B. ADAPTIVE IMMUNE DEFENSES

© Elsevier. Kumar et al: Robbins Basic Pathology 8e - www.studentconsult.com

Lung defense mechanisms.

Pneumonia

- Etiological classification
 - Bacterial pneumonia
 - Viral pneumonia
 - Fungal pneumonia
 - etc.
- Anatomical classification
 - Lobar pneumonia
 - Lobular pneumonia
 - Interstitial pneumonia

Pulmonary Infections or Pneumonia

- *Pneumonia can be very broadly defined as any infection in the lung.* It may present as acute, fulminant clinical disease or as chronic disease with a more protracted course.

Pathogenesis

- *Streptococcus Pneumoniae*
 - *The most common cause of acute pneumonia.*
 - *Examination of Gram-stained sputum is an important step in the diagnosis of acute pneumonia.*
 - Pneumococcal pneumonias respond readily to penicillin treatment, but there are increasing numbers of penicillin-resistant strains of pneumococci.
- *Haemophilus Influenzae*
 - A major cause of life-threatening acute lower respiratory tract infections and meningitis in young children.
- *Moraxella Catarrhalis*

Pathogenesis

- *Staphylococcus Aureus*
- *Klebsiella Pneumoniae*
- *Pseudomonas Aeruginosa*
- *Legionella Pneumophila*

Lobular Pneumonia or Bronchopneumonia

- Bronchopneumonia implies a patchy distribution of inflammation that generally involves more than one lobe.
- This pattern results from an initial infection of the bronchi and bronchioles with extension into the adjacent alveoli.
- It is a threat chiefly to the vulnerable infants, the aged, and those suffering from chronic debilitating illness or immunosuppression.

Pathogenesis

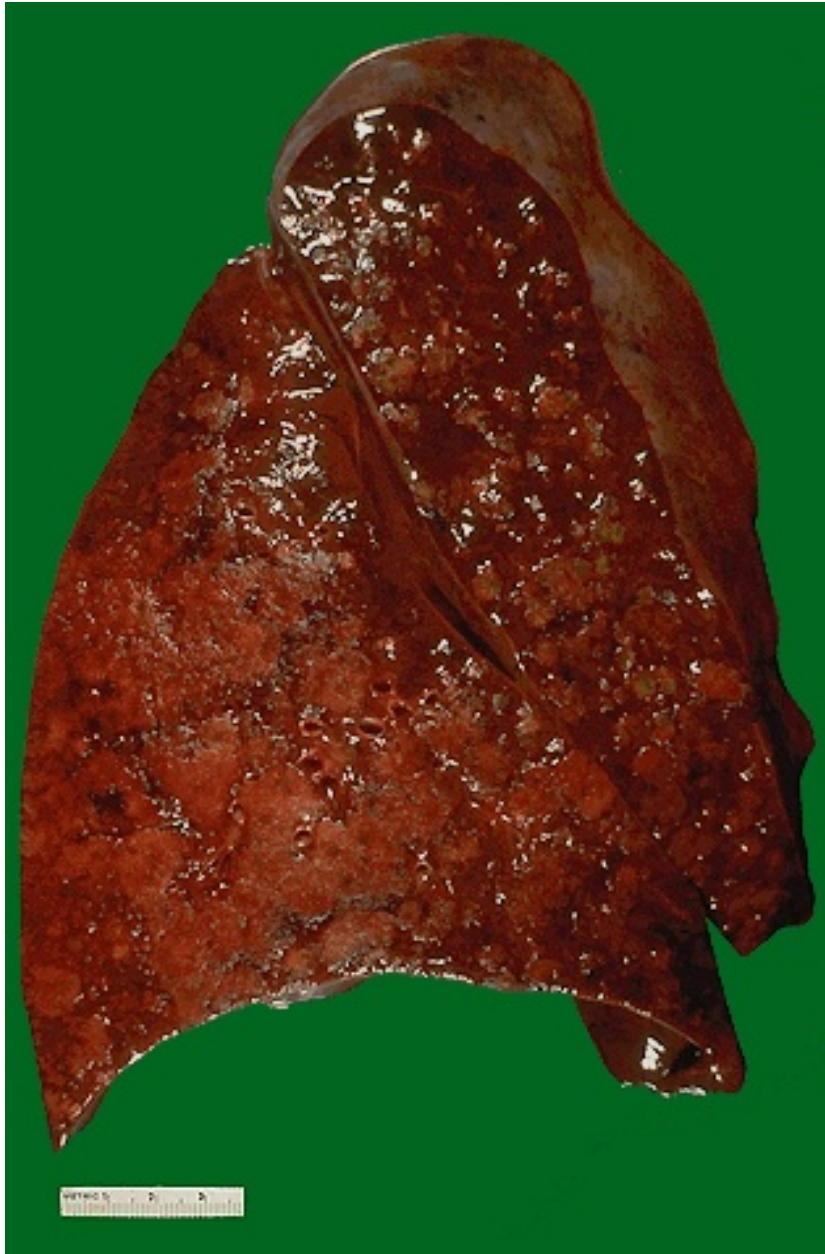- Whooping cough
- Measles
- Chronic bronchitis
- Alcoholism
- Malnutrition
- Ccarcinomatosis
- *Staphylococci, streptococci, haemophilus influenza, proteus species*

Pathogenesis

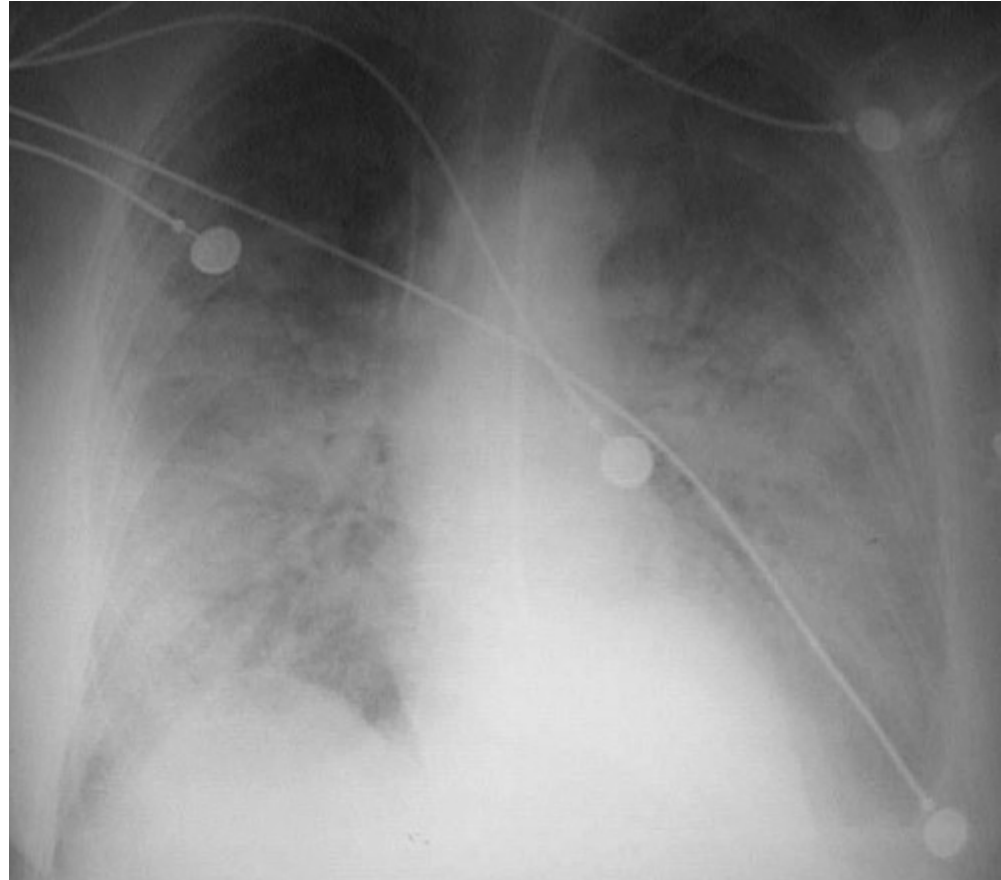
- *Hypostatic pneumonia*
 - The patient with pulmonary edema from cardiac failure or heavy uremia, et al, is particularly vulnerable.
- *Aspiration pneumonia*
 - The patient in coma or apoplexy, heavy anesthesia and so on is particularly vulnerable.

Morphology

- Consolidated areas of acute suppurative inflammation
- Patchy
- Slightly elevated, dry, granular, gray-red to yellow, and poorly delimited at their margins
- Pleural involvement is less common than in lobar pneumonia.
- Histologically
 - Focal suppurative exudate that fills the bronchi, bronchioles, and adjacent alveolar spaces.



The cut surface of this lung demonstrates the typical appearance of a bronchopneumonia with areas of tan-yellow consolidation. Remaining lung is dark red because of marked pulmonary congestion. Bronchopneumonia (lobular pneumonia) is characterized by patchy areas of pulmonary consolidation. These areas become almost confluent in the left lower lobe on the bottom left of the photograph. The areas of consolidation are firmer than the surrounding lung.



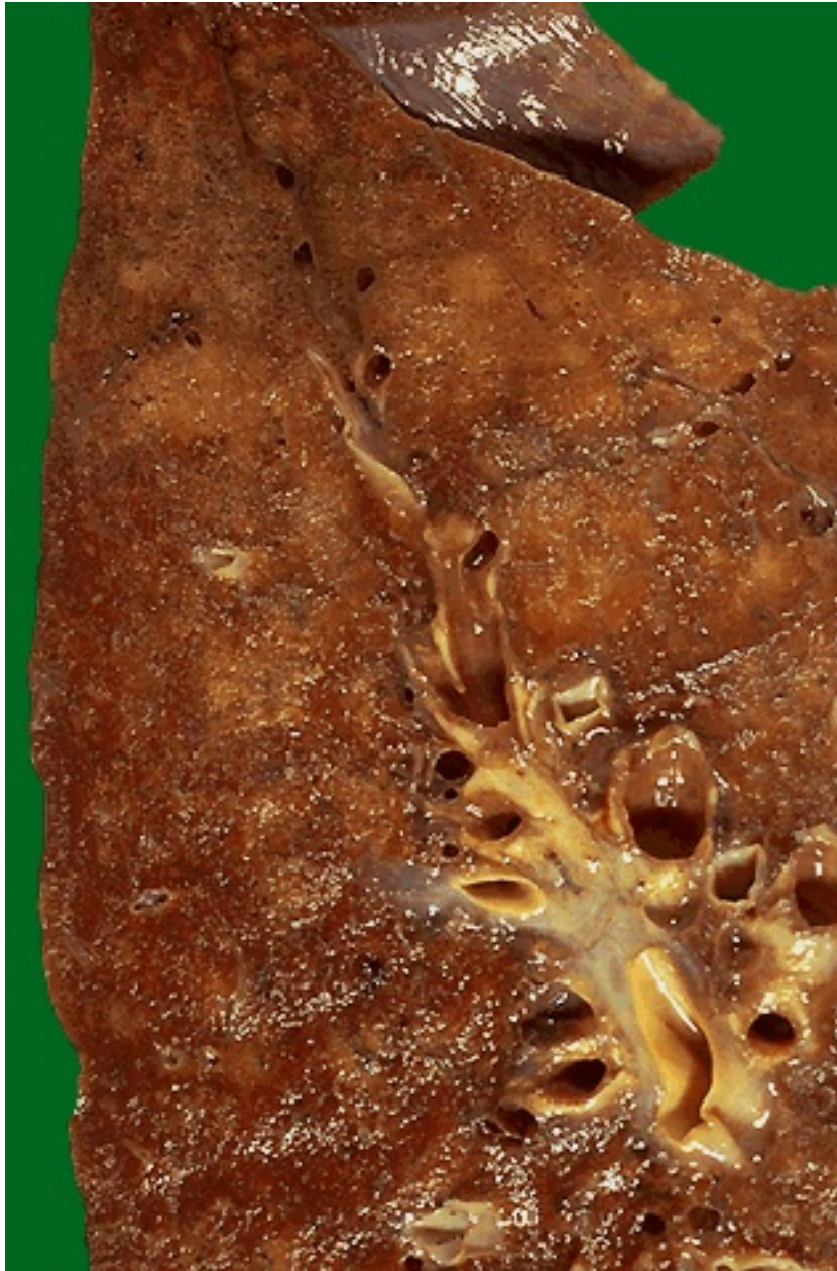This radiograph demonstrates patchy infiltrates consistent with a bronchopneumonia from a bacterial infection. Typical organisms include *Streptococcus pneumoniae*, *Staphylococcus aureus*, *Pseudomonas aeruginosa*, *Hemophilus influenzae*, *Klebsiella pneumoniae*, among others.



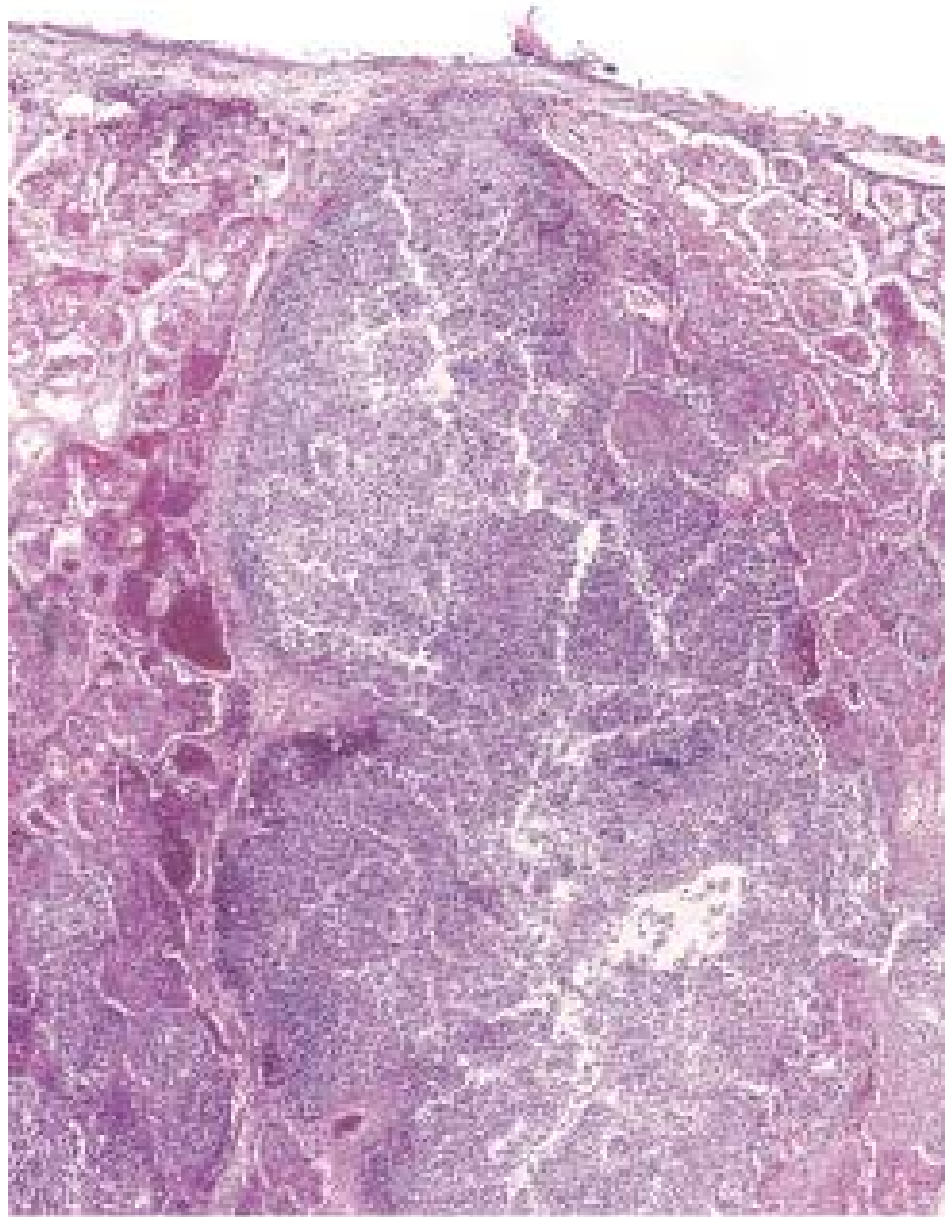
Bronchopneumonia.
Gross section of lung
showing patches of
consolidation
(*arrows*).



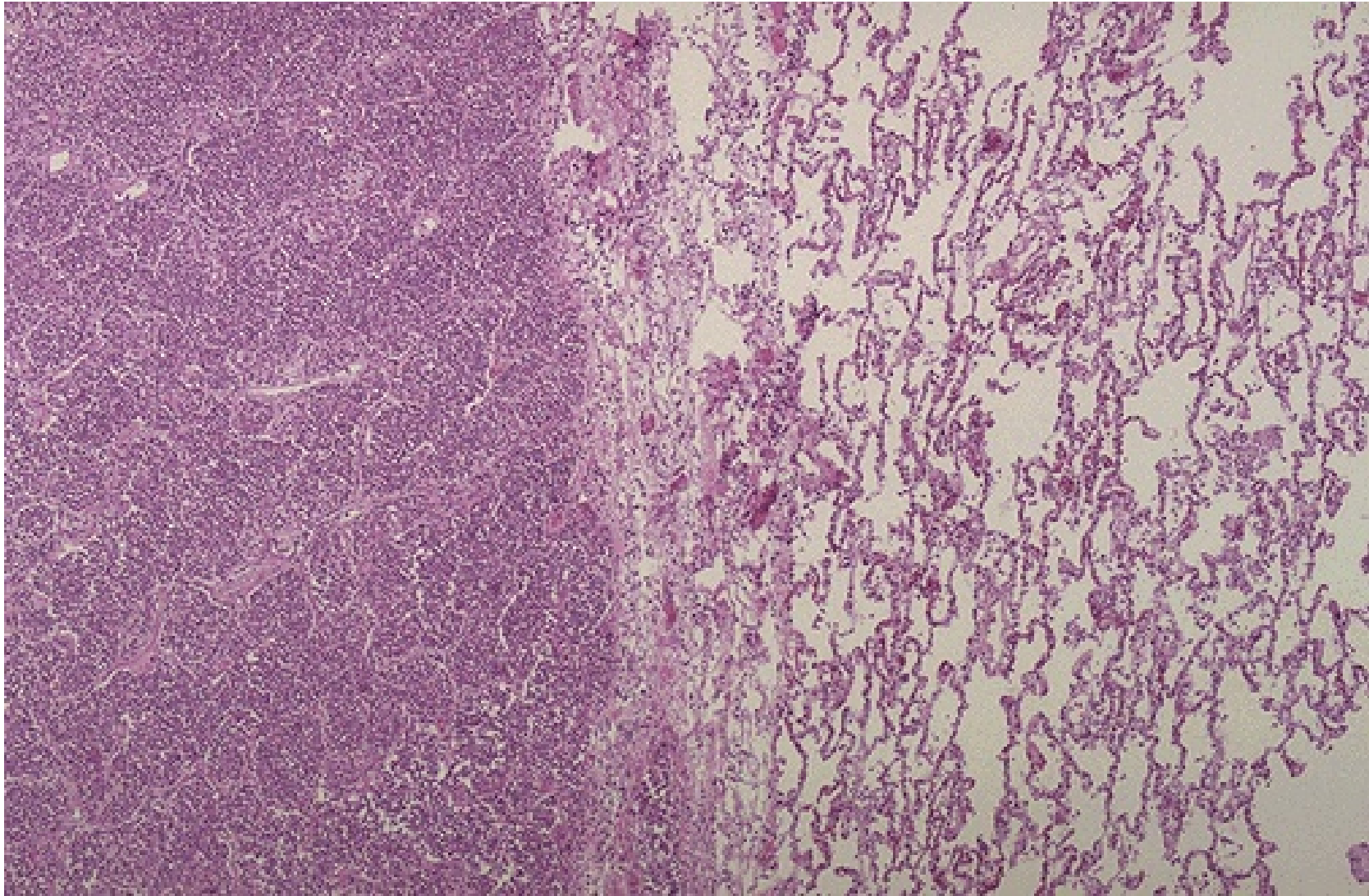
At higher magnification, the pattern of patchy distribution of a bronchopneumonia is seen. The consolidated areas here very closely match the pattern of lung lobules (hence the term "lobular" pneumonia). A bronchopneumonia is classically a "hospital acquired" pneumonia seen in persons already ill from another disease process. Typical bacterial organisms include: Staphylococcus aureus, Klebsiella, E. coli, Pseudomonas.



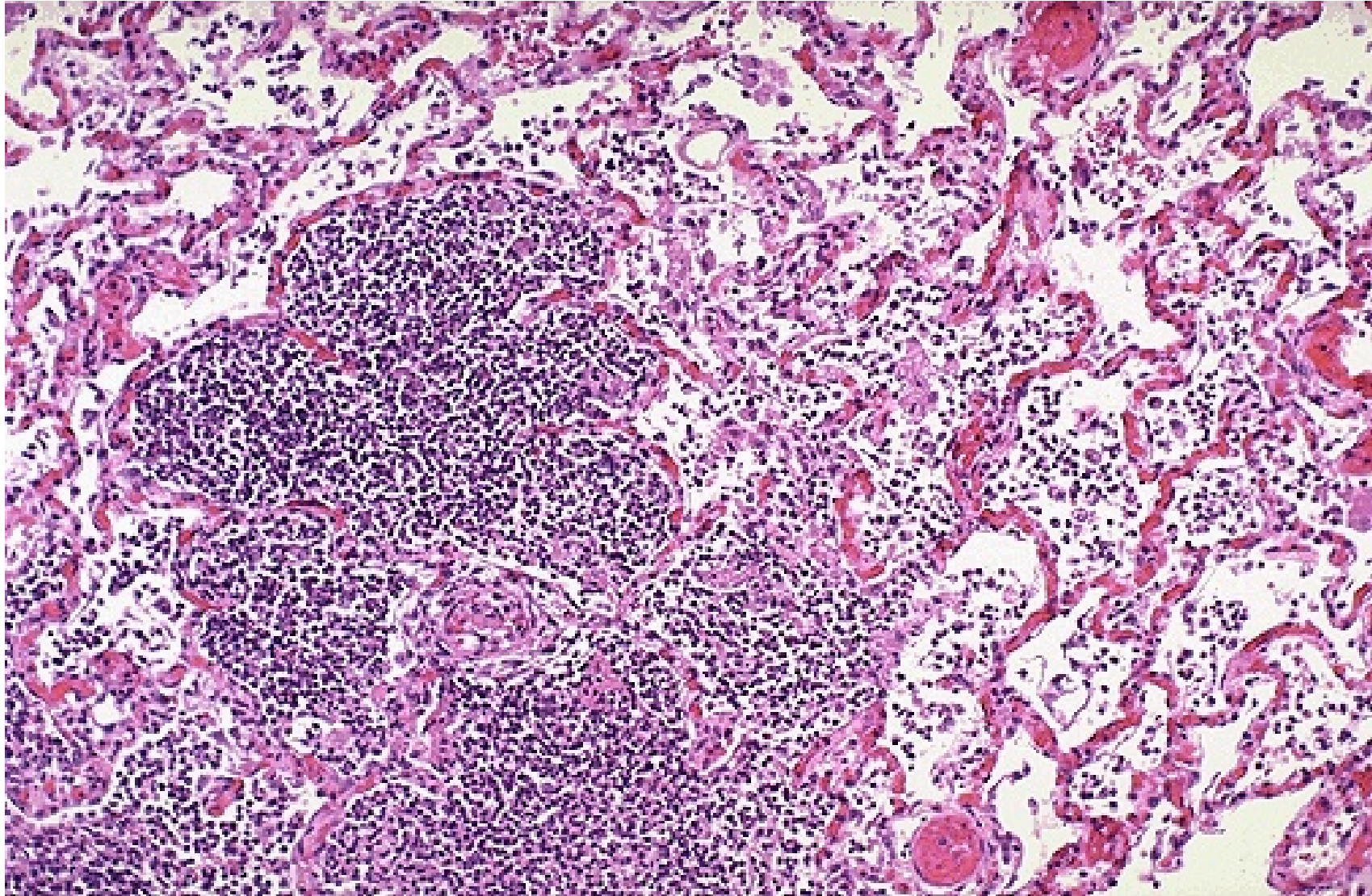
This bronchopneumonia is more subtle, but there are areas of lighter tan consolidation. The hilum is seen at the lower right with radiating pulmonary arteries and bronchi. Many bronchopneumonias follow an earlier viral pneumonia, particularly in older persons in the winter months when influenza is more common.



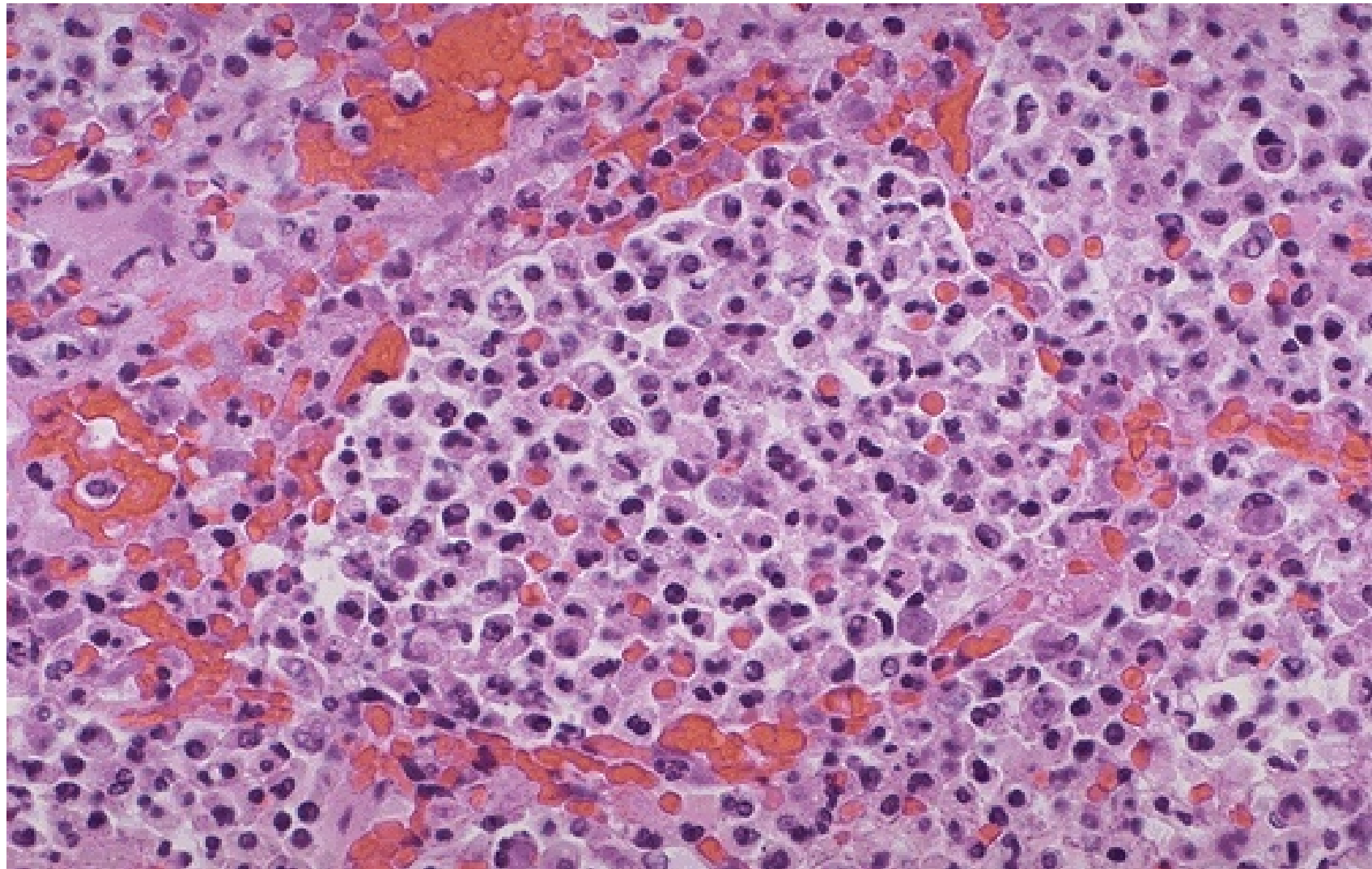
Pyemic lung abscess in the center of section with complete destruction of underlying parenchyma within the focus of involvement.



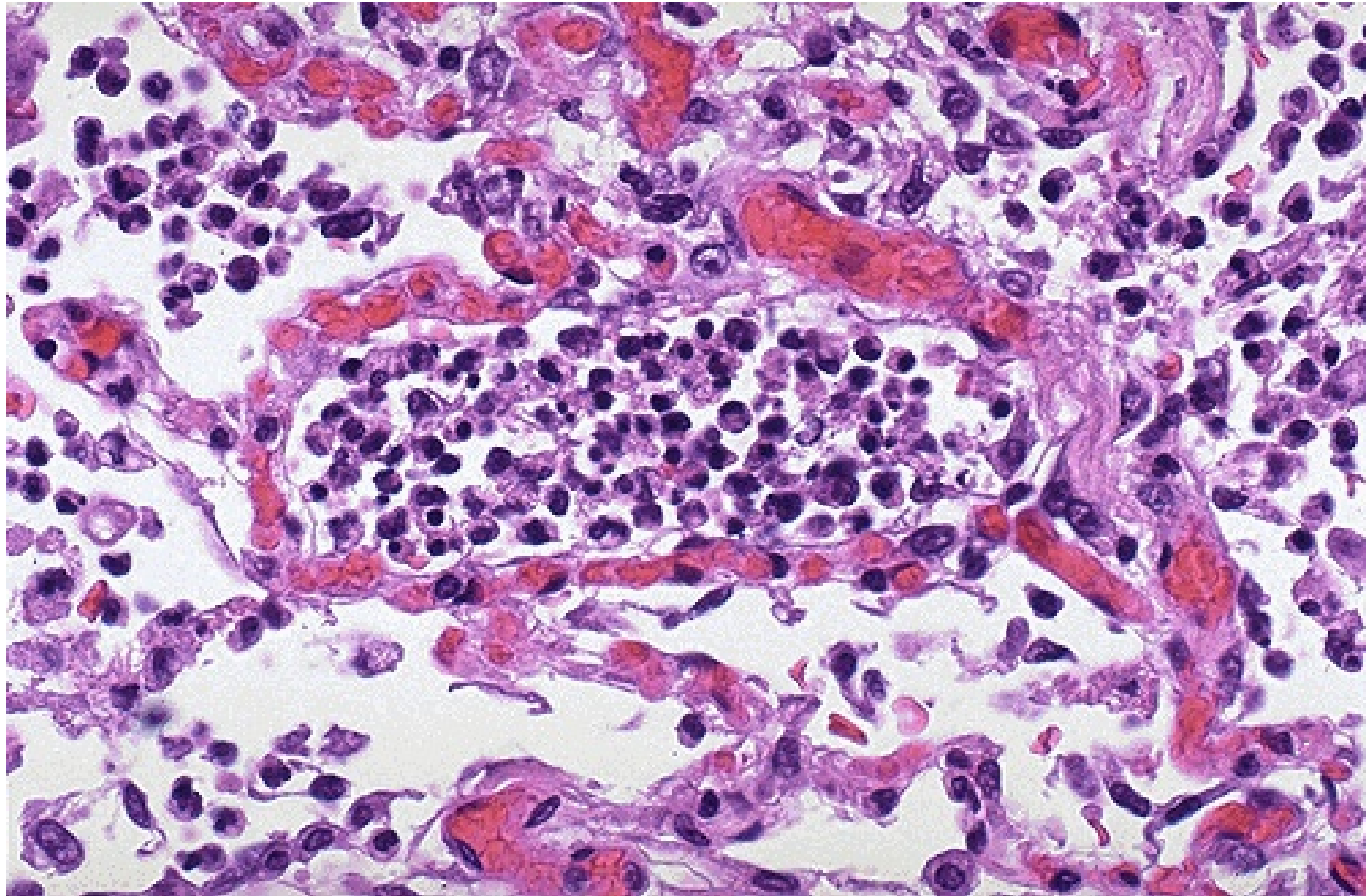
At the left the alveoli are filled with a neutrophilic exudate that corresponds to the areas of consolidation seen grossly with the bronchopneumonia.



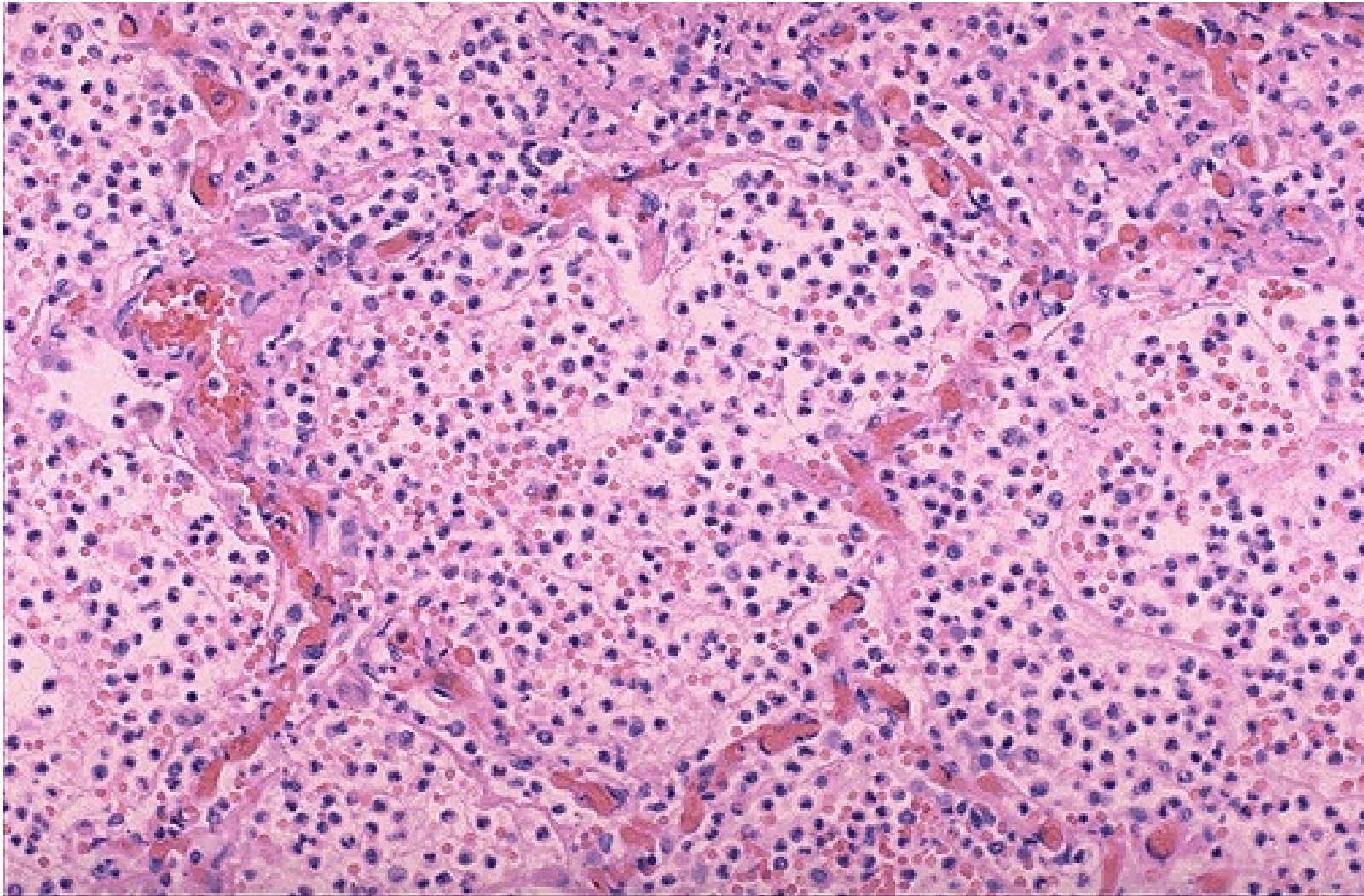
The alveolar structure is still maintained, which is why a pneumonia often resolves with minimal residual destruction or damage to the lung.



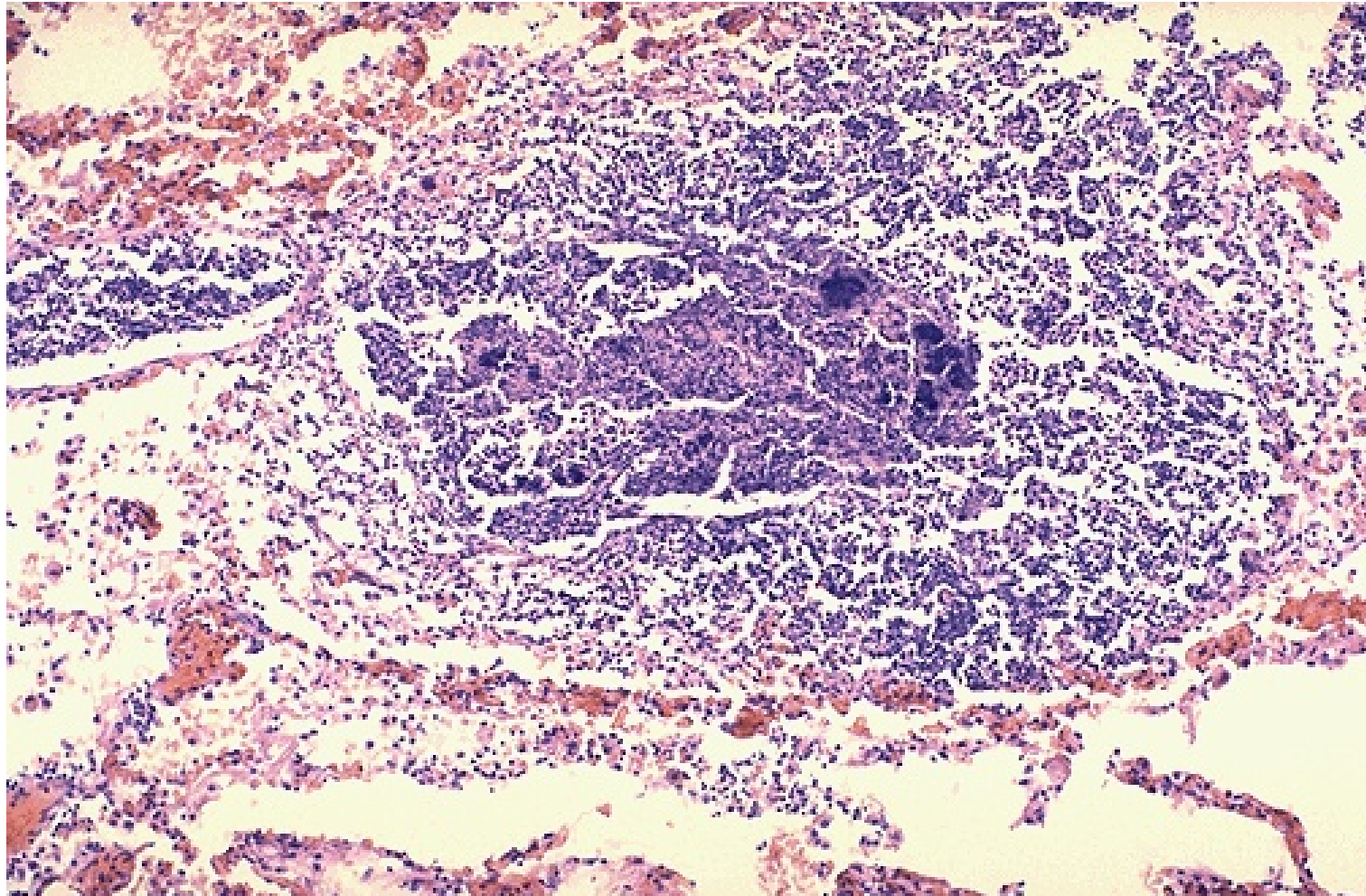
At high magnification, the alveolar exudate of mainly neutrophils is seen. The surrounding alveolar walls have capillaries that are dilated and filled with RBC's. This exudate gives rise to the productive cough of purulent yellow sputum seen with bacterial pneumonias.



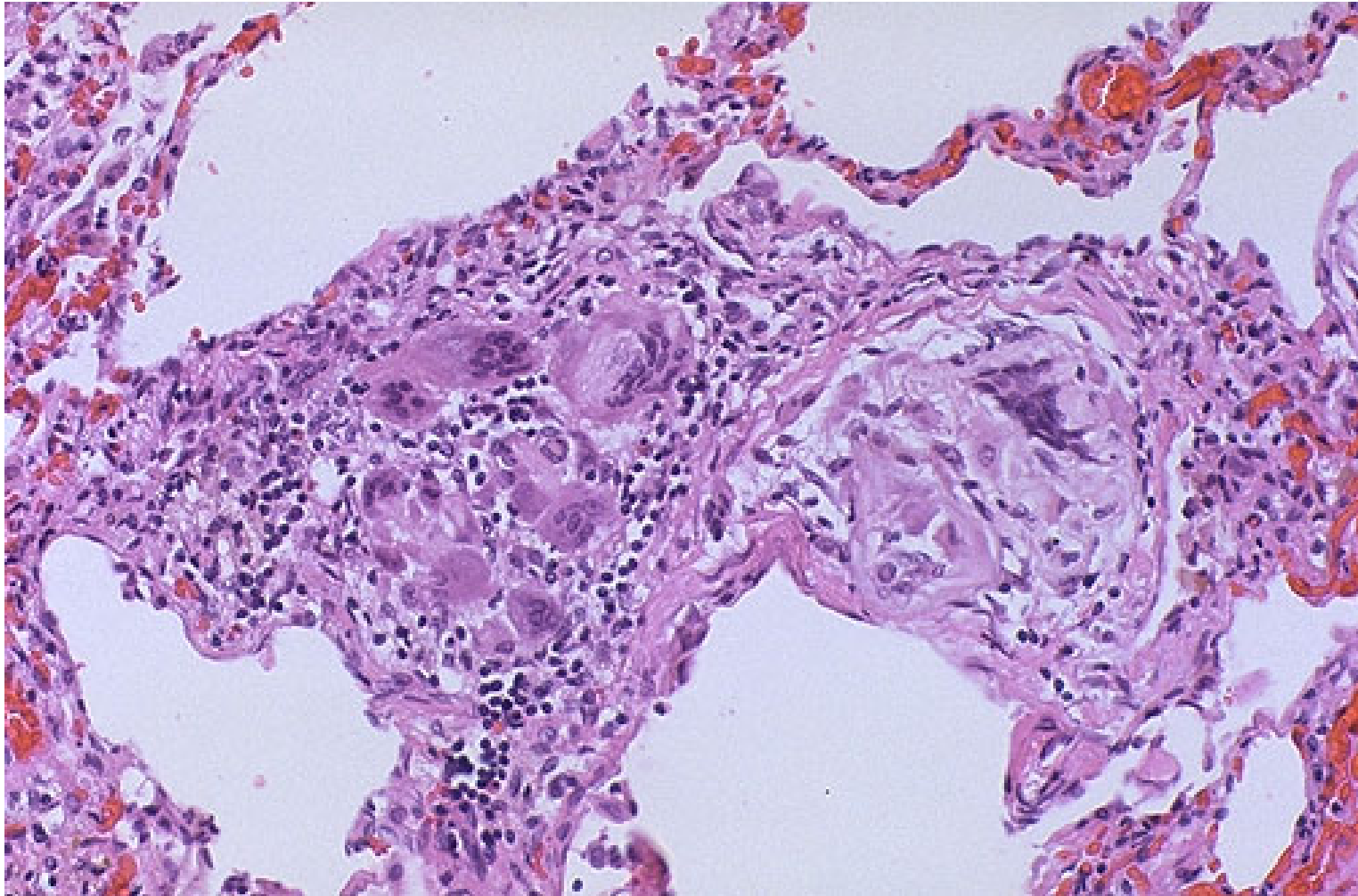
The PMN's seen here are in alveoli, indicative of an acute bronchopneumonia of the lung. The PMN's form an exudate in the alveoli. This patient had a "productive" cough because large amounts of purulent sputum were produced. The source, the neutrophilic alveolar exudate, is seen here.



At medium power magnification, numerous neutrophils fill the alveoli in this case of acute bronchopneumonia in a patient with a high fever. *Pseudomonas aeruginosa* was cultured from sputum. Note the dilated capillaries in the alveolar walls from vasodilation with the acute inflammatory process.



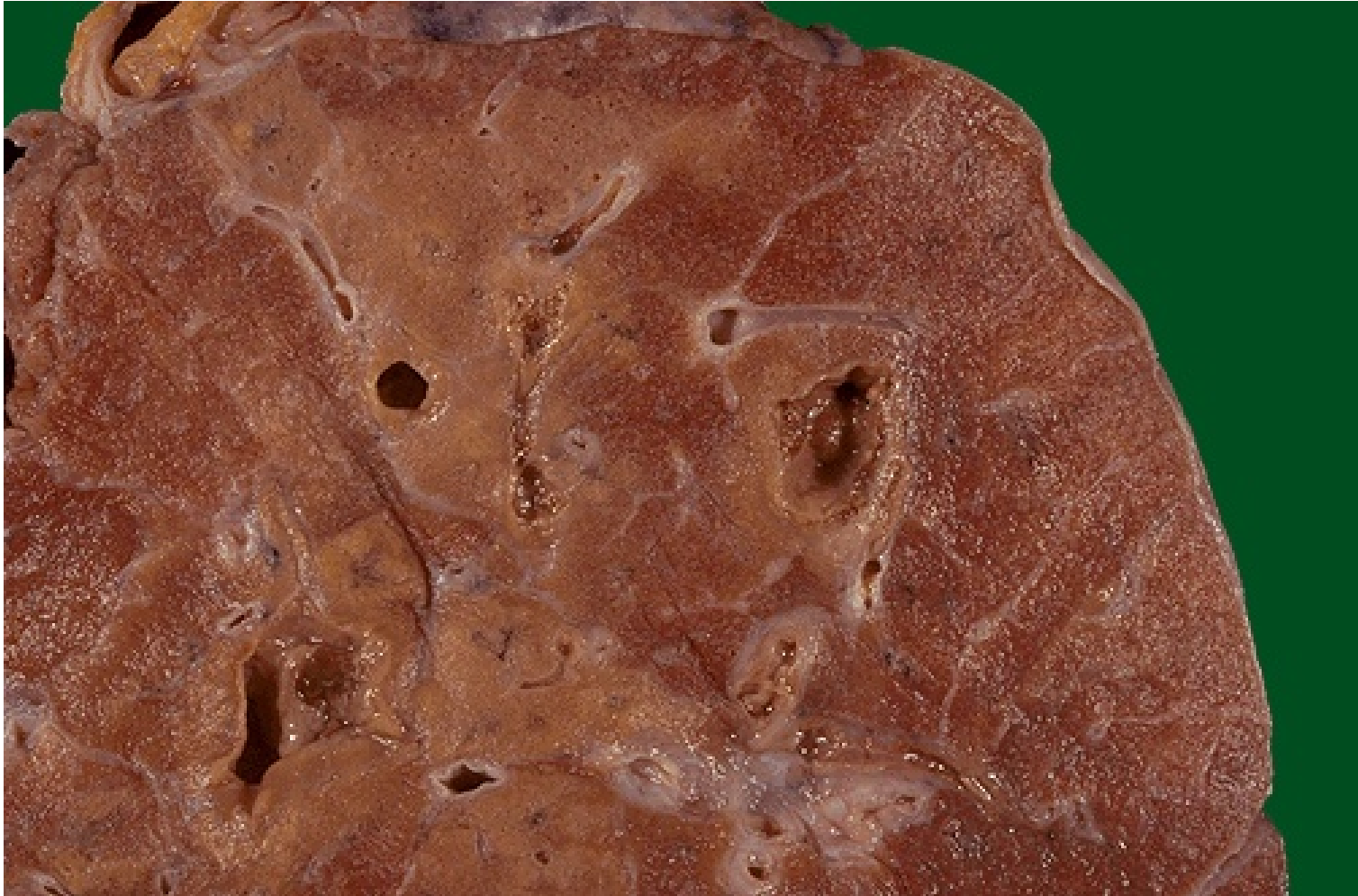This more focal abscess containing a neutrophilic exudate as well as dark blue bacterial colonies suggests aspiration or hematogenous spread of infection to the lung. Aspirated material from the oral-pharyngeal region contains bacterial flora. Hematogenous spread of infection to lungs could occur from septicemia or from infective endocarditis involving the right side of the heart.



There is a localized foreign body giant cell response to the aspirated material seen here at high magnification. Aspirated material may also produce inflammation from chemical irritation, as with gastric contents.

Clinical Course

- Abscess formation
 - tissue destruction and necrosis
- Empyema
 - Suppurative material may accumulate in the pleural cavity
- Fibrosis
 - Organization of the intra-alveolar exudate
- Meningitis, arthritis, or infective endocarditis



This is an abscessing bronchopneumonia in which several abscesses with irregular, rough-surfaced walls are seen within areas of tan consolidation. Lung abscesses, if large enough, will contain liquefied necrotic material and purulent exudate that often results in an air-fluid level by chest radiograph in the abscess.

Lobar Pneumonia


- The contiguous airspaces of part or all of a lobe are homogeneously filled with an exudate that can be visualized on radiographs as a lobar or segmental consolidation.
- *Streptococcus pneumoniae* is responsible for more than 90% of lobar pneumonias.

Pathogenesis

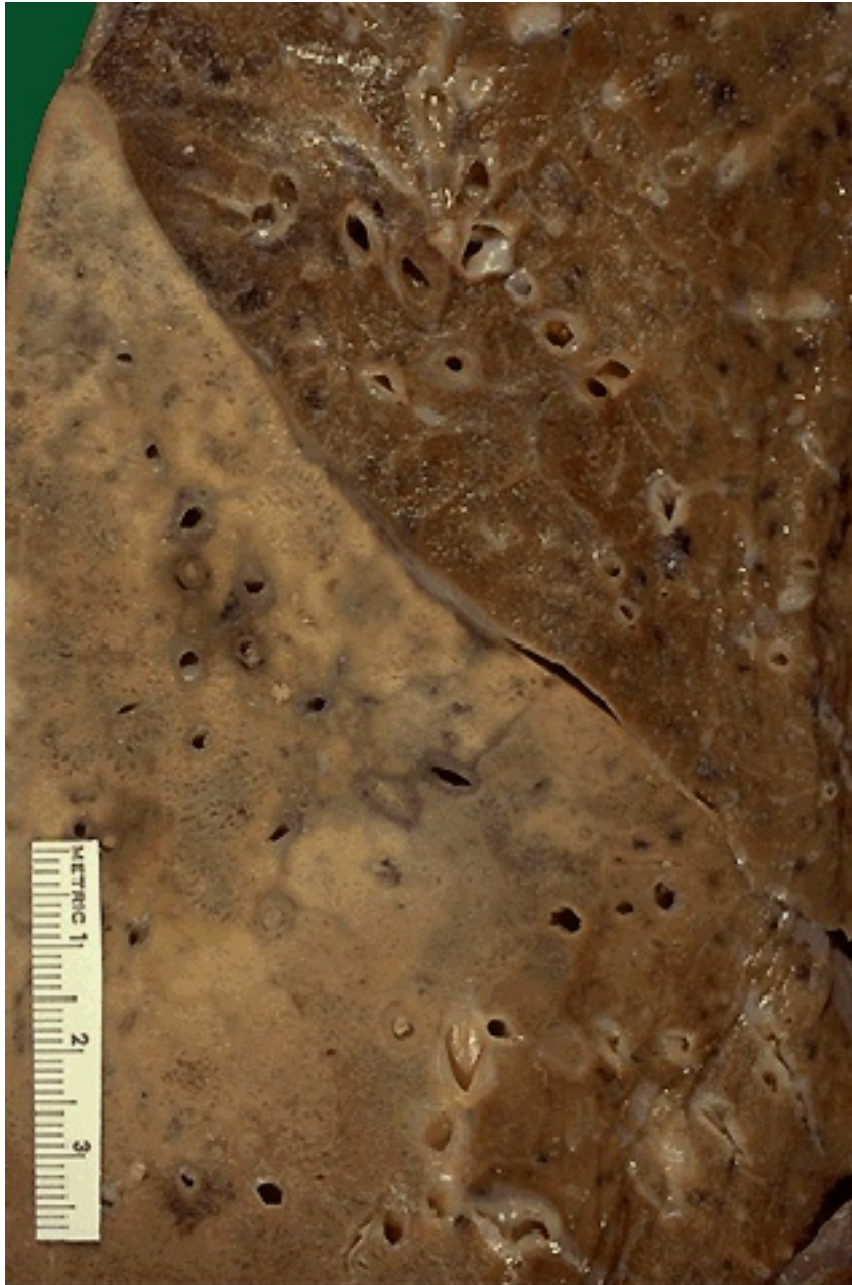
- >90% *S. pneumoniae*
- The sudden onset
- Fibrinous exudates

Morphology

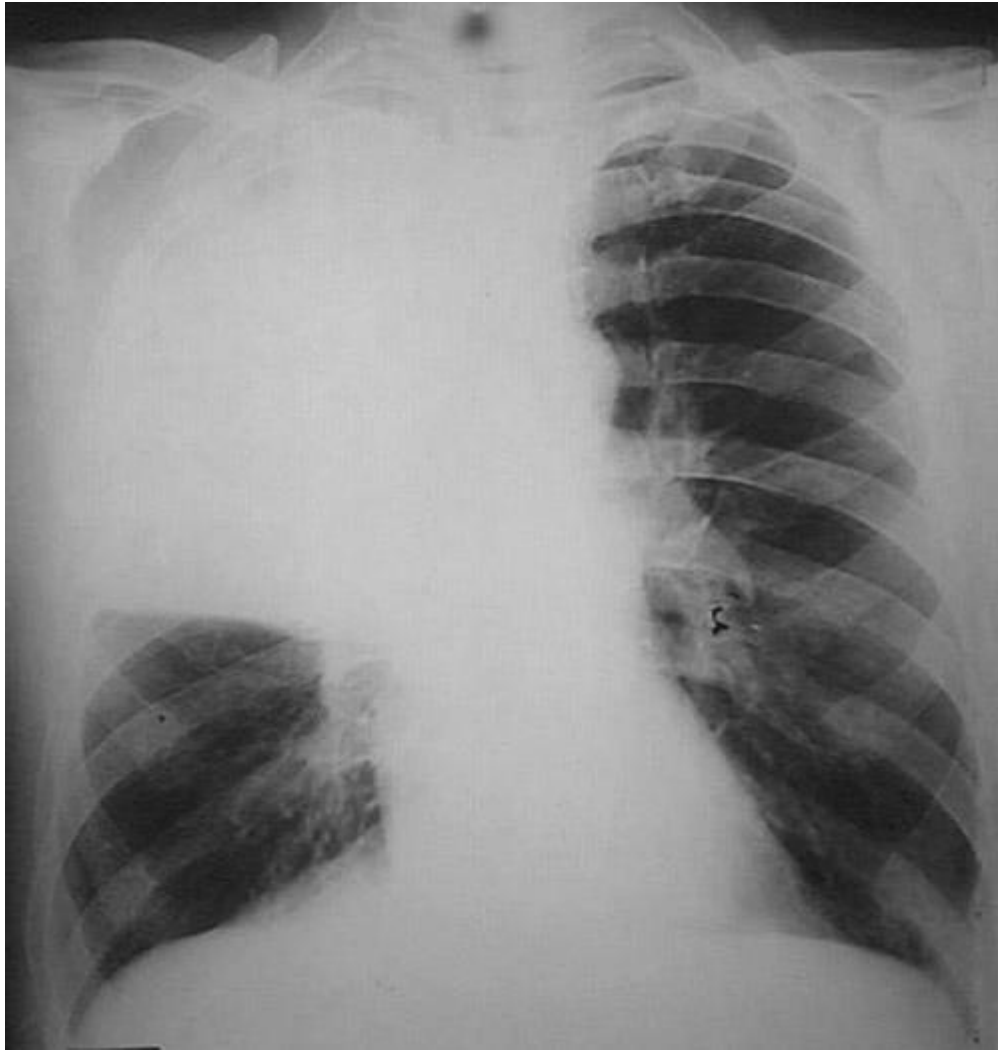
- Four stages of the inflammatory response
 - Congestion
 - Red hepatization
 - Gray hepatization
 - Resolution



This is a lobar pneumonia in which consolidation of the entire left upper lobe has occurred. This pattern is much less common than the bronchopneumonia pattern. In part, this is due to the fact that most lobar pneumonias are due to *Streptococcus pneumoniae* (pneumococcus) and for decades, these have responded well to penicillin therapy so that advanced, severe cases are not seen as frequently. However, pneumococci, like most other bacteria, are developing more resistance to antibiotics. Severe pneumococcal pneumonia still occurs, even in young to middle aged persons (not just the very young and the very old) and has a mortality rate of 20%!



A closer view of the lobar pneumonia demonstrates the distinct difference between the upper lobe and the consolidated lower lobe. Radiographically, areas of consolidation appear as infiltrates.



Chest x-ray demonstrating complete right upper lobe consolidation, consistent with a lobar pneumonia.

Stage of Congestion

- The lung is heavy, boggy, and red.
- It is characterized by vascular engorgement, intra-alveolar fluid with few neutrophils, and often the presence of numerous bacteria.

Stage of Red Hepatization

- Massive confluent exudation with red cells (congestion), neutrophils, and fibrin filling the alveolar spaces.
- The lobe now appears distinctly red, firm, and airless, with a liver-like consistency, hence the term *hepatization*.

Stage of Gray Hepatization

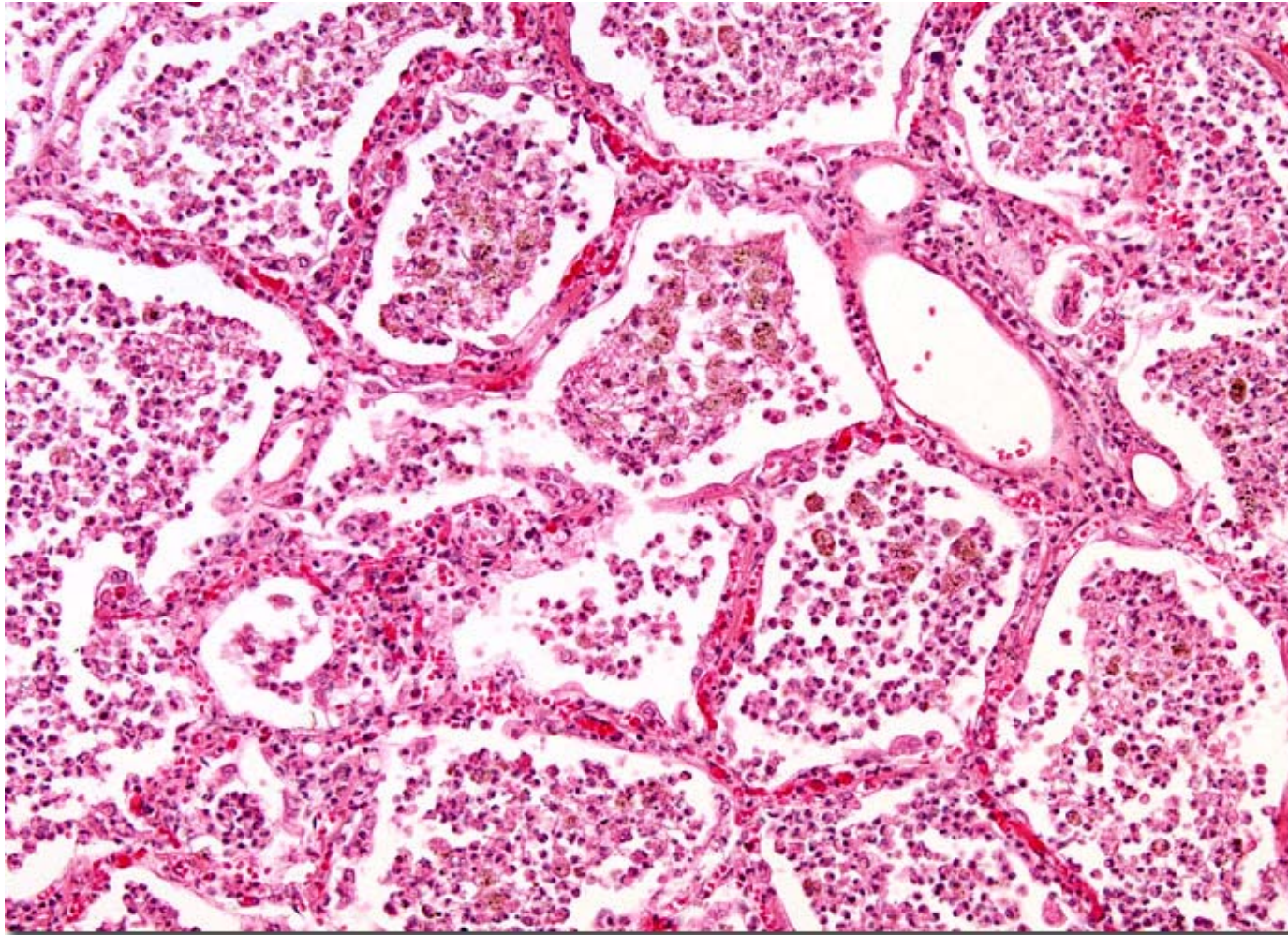
- Progressive disintegration of red cells
- The persistence of a fibrinosuppurative exudate.
- The gross appearance
 - A grayish brown, dry surface



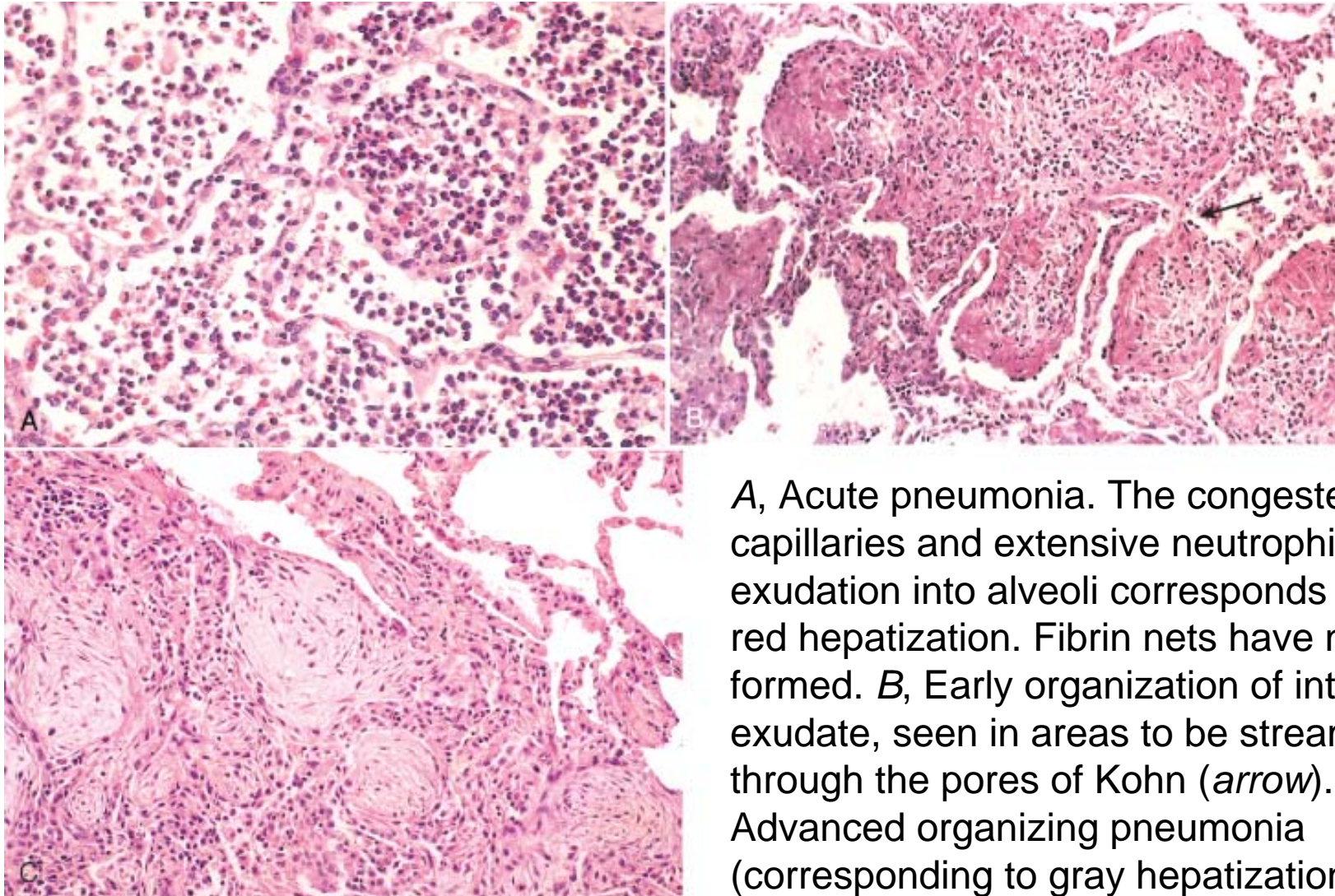
Lobar pneumonia-gray hepatization, gross photograph. The lower lobe is uniformly consolidated.

Stage of Resolution

- The consolidated exudate within the alveolar spaces undergoes progressive enzymatic digestion to produce a granular, semifluid, debris that is resorbed, ingested by macrophages, coughed up, or organized by fibroblasts growing into it.



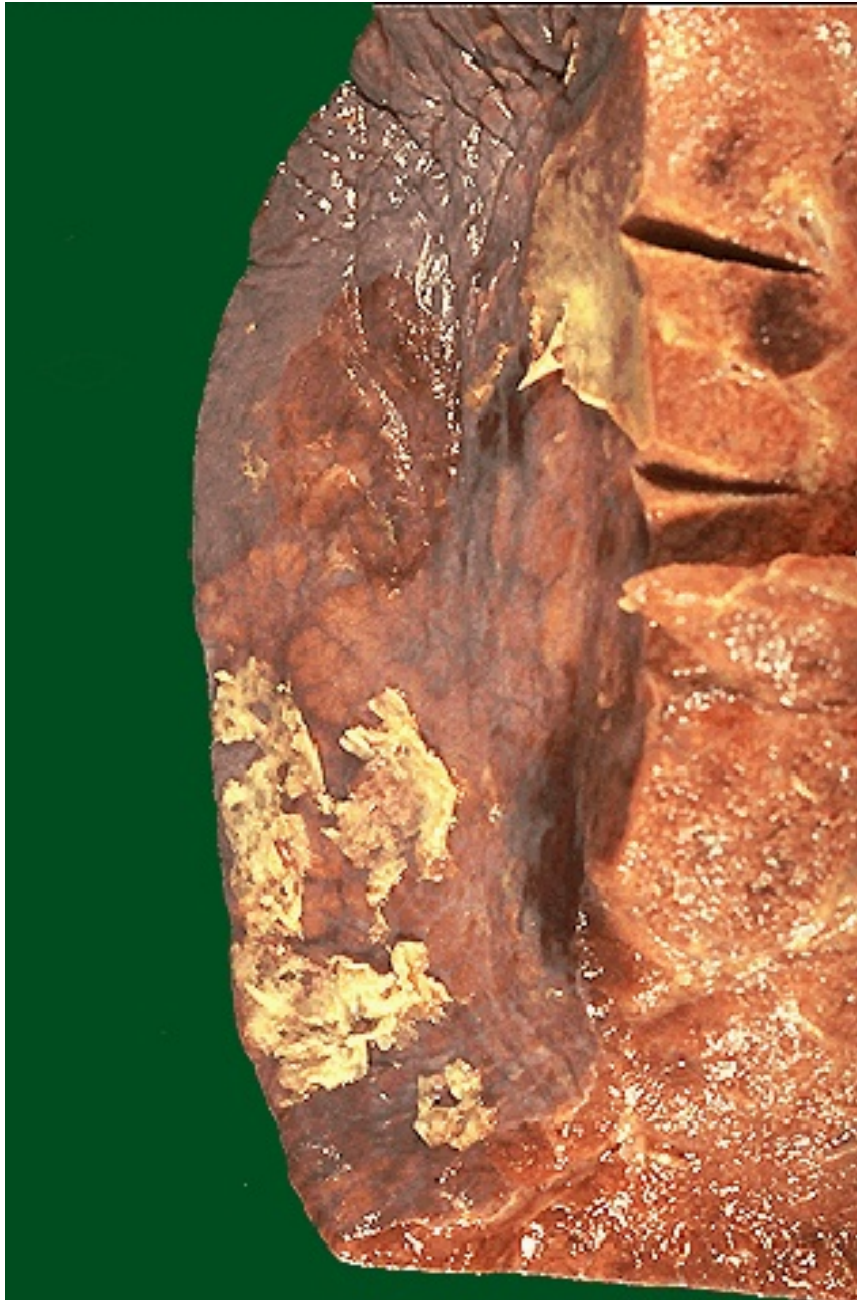
Pneumonia is a disease characterized by inflammation and congestion of the lungs. Infection with any of a variety of microorganisms is the typical cause, but sometime the condition is related to an allergic reaction or inhalation of fluid, food, or certain gases. When pneumonia is restricted to a single lobe of the lung or to a portion of a lobe, it is referred to as lobar pneumonia.



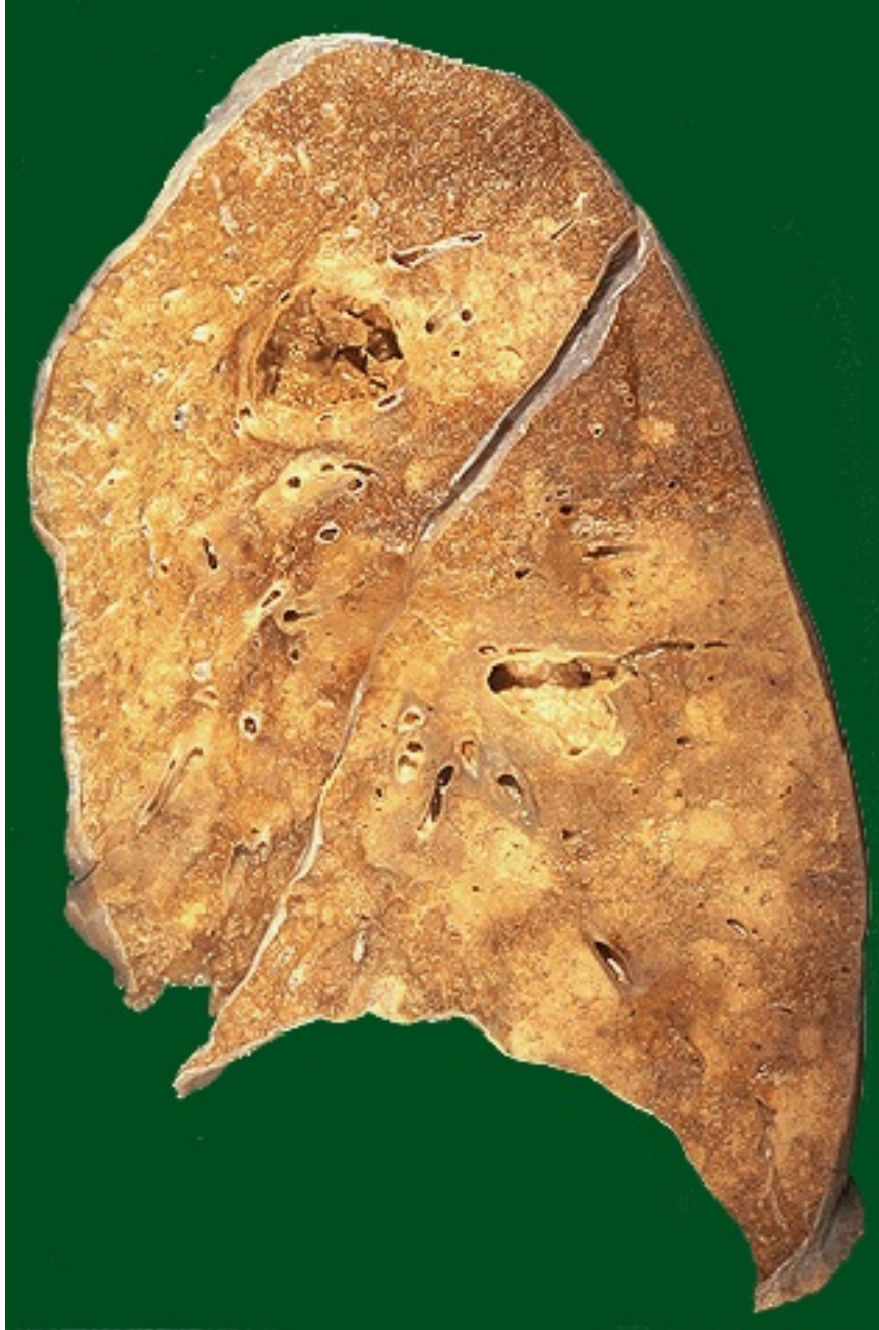A, Acute pneumonia. The congested septal capillaries and extensive neutrophil exudation into alveoli corresponds to early red hepatization. Fibrin nets have not yet formed. B, Early organization of intra-alveolar exudate, seen in areas to be streaming through the pores of Kohn (*arrow*). C, Advanced organizing pneumonia (corresponding to gray hepatization), featuring transformation of exudates to fibromyxoid masses richly infiltrated by macrophages and fibroblasts.

Complications

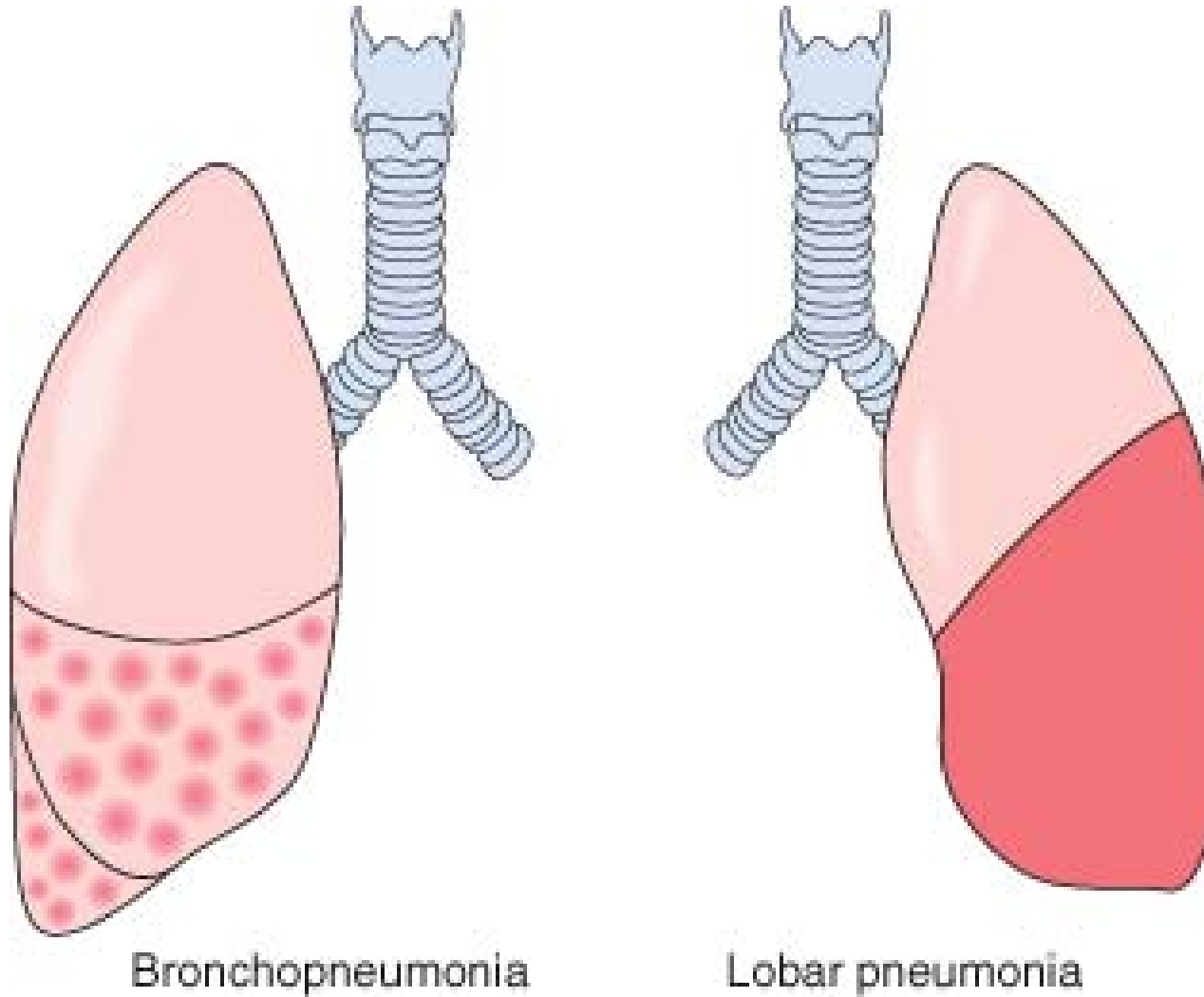
- Carnification
 - Organization of intra alveolar fibrinous exudates instead of resorption may convert areas of the lung into solid fibrous tissue.
- Tissue destruction and necrosis
- Fibrinous or fibrinopurulent pleuritis



The pleural surface at the lower left demonstrates areas of yellow-tan purulent exudate. Pneumonia may be complicated by a pleuritis. Initially, there may just be an effusion into the pleural space. There may also be a fibrinous pleuritis. However, bacterial infections of lung can spread to the pleura to produce a purulent pleuritis. A collection of pus in the pleural space is known as empyema.



Seen here are two lung abscesses, one in the upper lobe and one in the lower lobe of this left lung. An abscess is a complication of severe pneumonia, most typically from virulent organisms such as *S. aureus*. Abscesses are complications of aspiration, where they appear more frequently in the right posterior lung.



© Elsevier 2005

Comparison of bronchopneumonia and lobar pneumonia.

Interstitial Pneumonia

- An inflammatory process involving the interstitial tissue of the lungs.
- Unlike “typical” acute pneumonias, sputum production was modest, there were no physical findings of consolidation, the white cell count was only moderately elevated, and bacteria and influenza viruses could not be isolated.

Mycoplasma Pneumonia

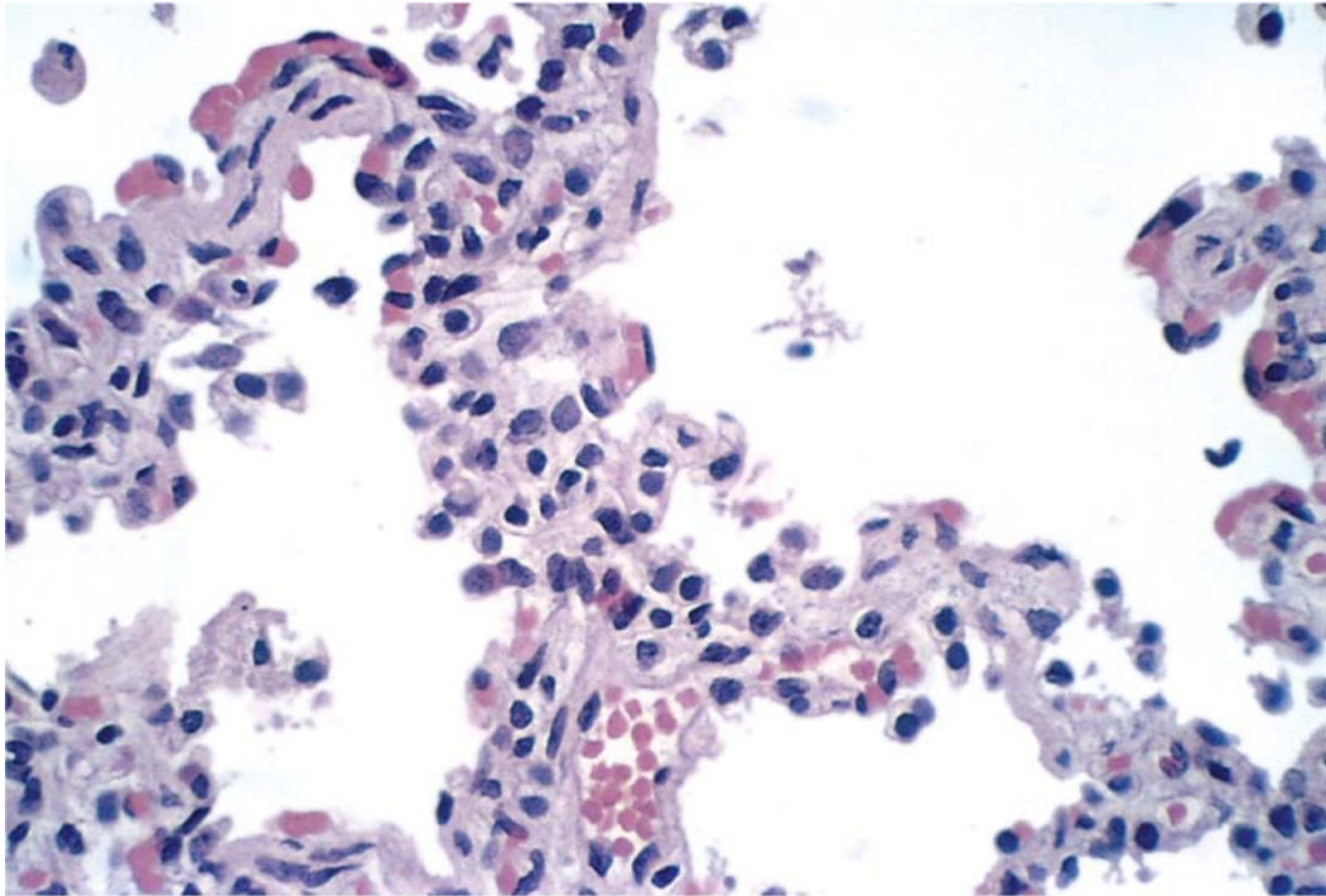
- *Mycoplasma* infections are particularly common among children and young adults.
- Other etiologic agents are viruses, including influenza virus types A and B, the respiratory syncytial viruses, adenovirus, rhinoviruses, rubeola, and varicella viruses.

Morphology

- Quite patchy or may involve whole lobes bilaterally or unilaterally.
- Red-blue, congested, and subcrepitant.
- The pleura is smooth, and pleuritis or pleural effusions are infrequent.

Histologic Pattern

- Inflammatory reaction, virtually localized within the walls of the alveoli.
- The alveolar septa are widened and edematous and usually have a mononuclear inflammatory infiltrate of lymphocytes, histiocytes, and occasionally plasma cells.



© Elsevier. Kumar et al: Robbins Basic Pathology 8e - www.studentconsult.com

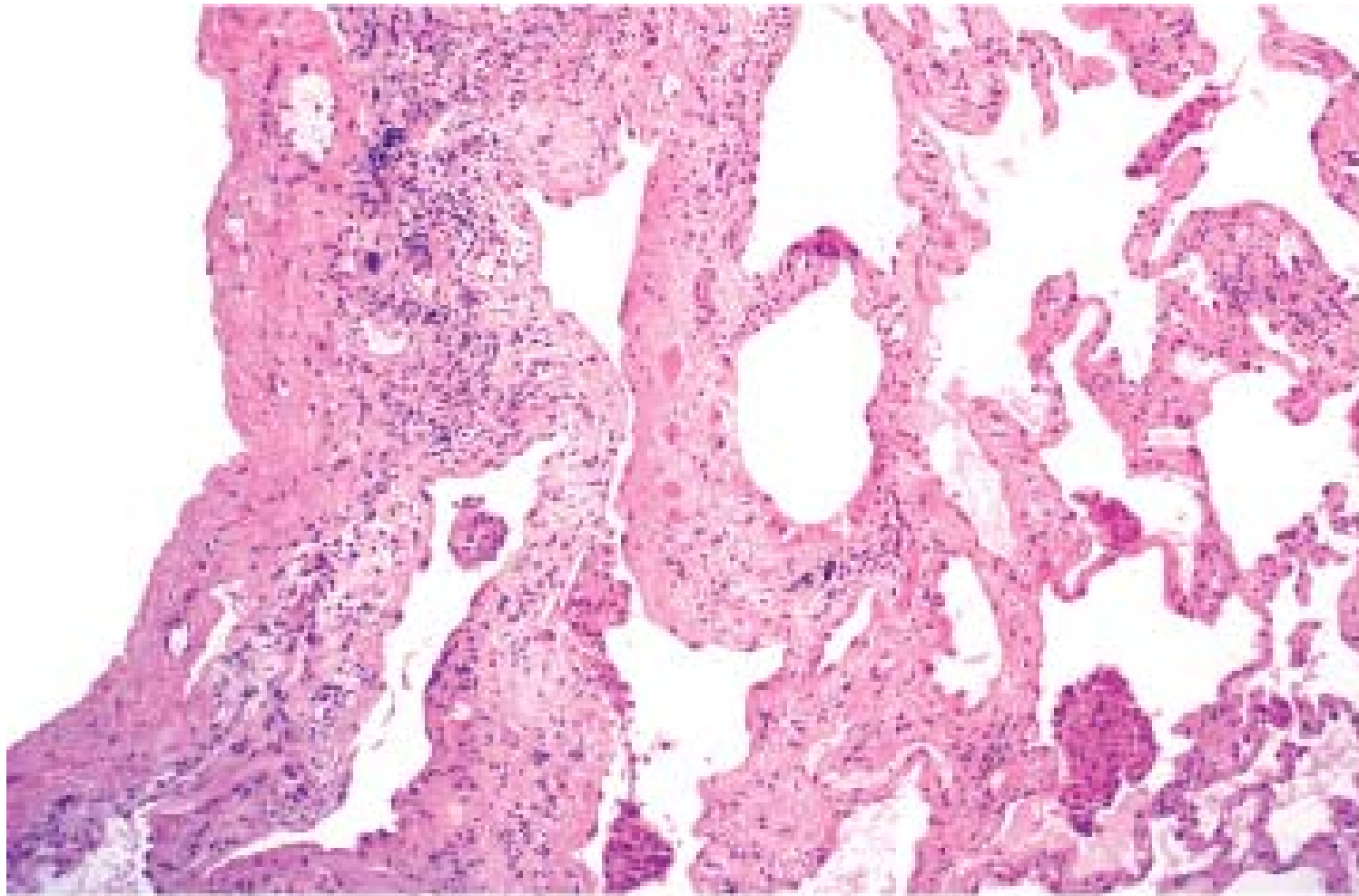
Atypical pneumonia. The thickened alveolar walls are heavily infiltrated with mononuclear leukocytes.

Clinical Course

- Severe upper respiratory tract infections or *as chest colds*.
- Fever, headache, muscle aches, and pains in the legs.

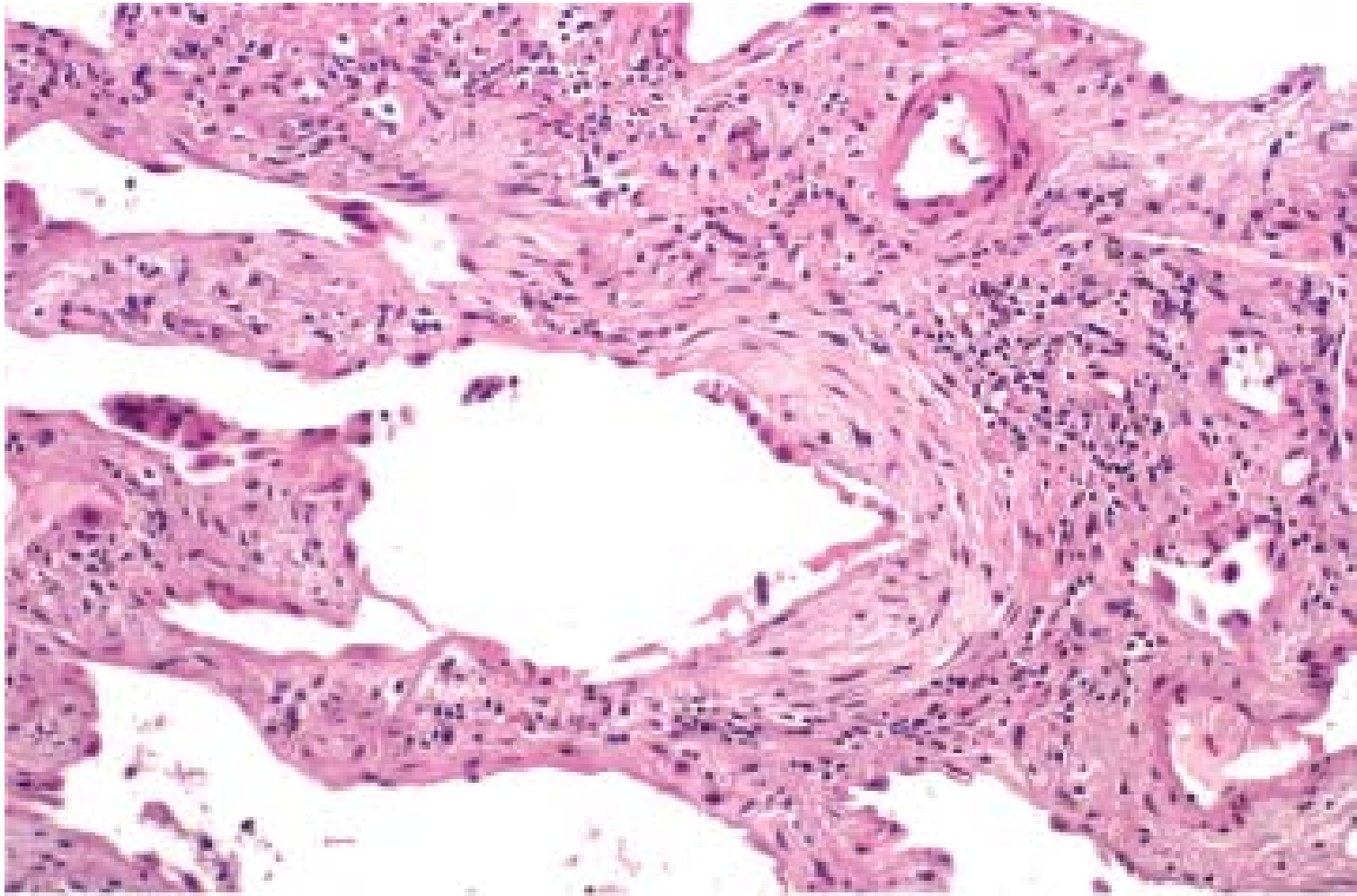
Viral Pneumonia

- Mucosal hyperemia and swelling with a predominantly lymphomonocytic and plasmacytic infiltration.
- Overproduction of mucus secretions.
 - **Inclusion bodies** within cytoplasm or nucleus of the epithelial cells of bronchioles and alveoli.



© Elsevier 2005

Usual interstitial pneumonia. The fibrosis, which varies in intensity, is more pronounced in the subpleural region.



© Elsevier 2005

Usual interstitial pneumonia. Fibroblastic focus with fibers running parallel to surface and bluish myxoid extracellular matrix .

Severe Acute Respiratory Syndrome (SARS)

- Coronavirus (SARS-CoV)
- Viremia
- Fever, myalgias, headache, chills, and occasionally diarrhea
- Dry cough and dyspnea
- Diffuse alveolar damage and multinucleated giant cells

SUMMARY

- *S. pneumoniae* (pneumococcus) is the most common cause of community-acquired acute pneumonia, and the distribution of inflammation is usually lobar.
- Morphologically, lobar pneumonias evolve through four stages: congestion, red hepatization, gray hepatization, and resolution.
- Other common causes of acute pneumonias in the community include *H. influenzae* and *M. catarrhalis*, *S. aureus*, *K. pneumoniae*, *P. aeruginosa* and *L. pneumophila*.
- In contrast to acute pneumonias, *atypical pneumonias* are characterized by respiratory distress out of proportion to the clinical and radiologic signs, and inflammation that is predominantly confined to alveolar septa, with generally clear alveoli.



Silicosis

- Silicosis is currently the most prevalent chronic occupational disease in the world.
- Crystalline silica
-

Pathogenesis

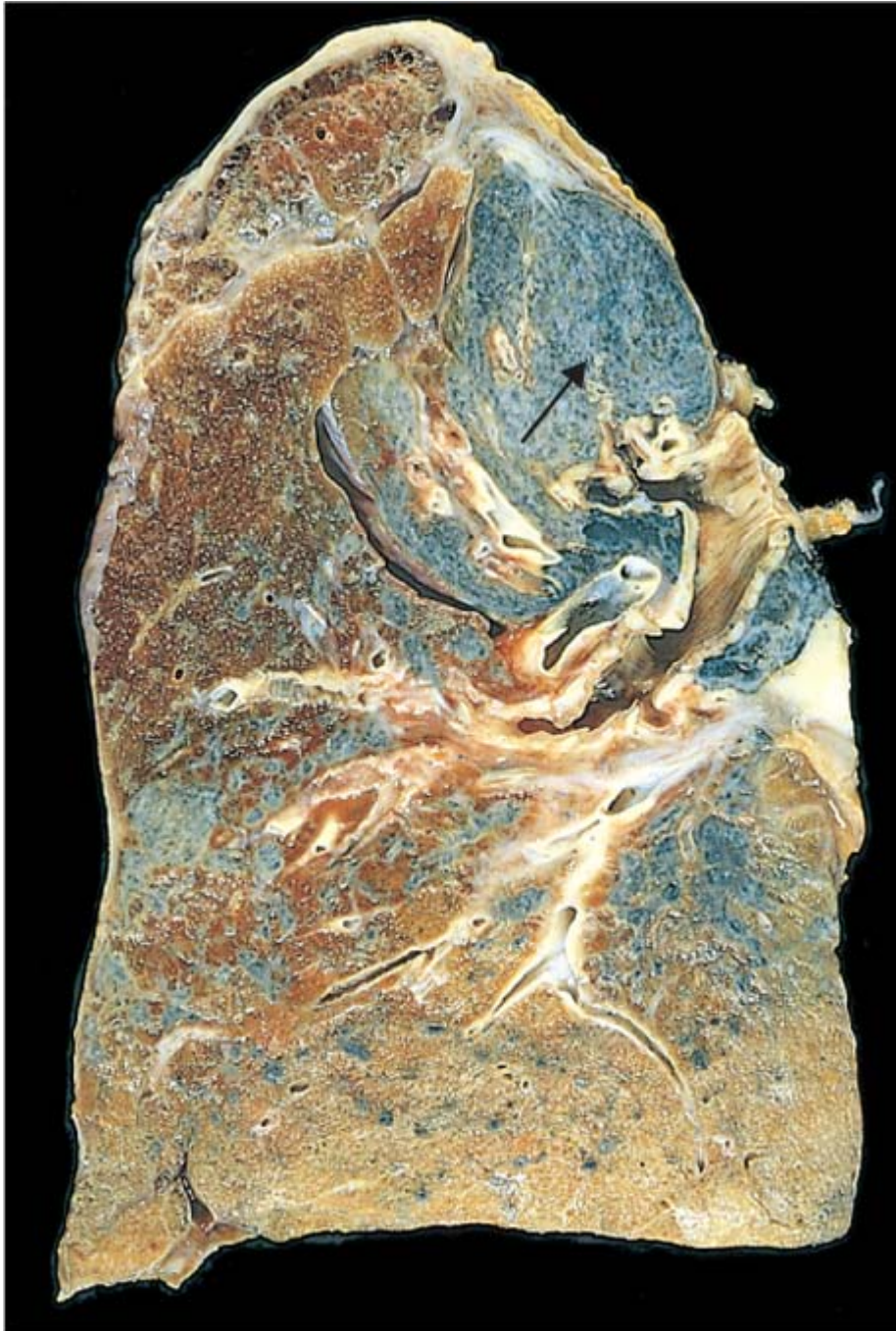- Ingested silica particles cause activation and release of mediators by pulmonary macrophages.
 - IL-1
 - TNF
 - Fibronectin
 - Lipid mediators
 - Oxygen-derived free radicals
 - Fibrogenic cytokines

Morphology

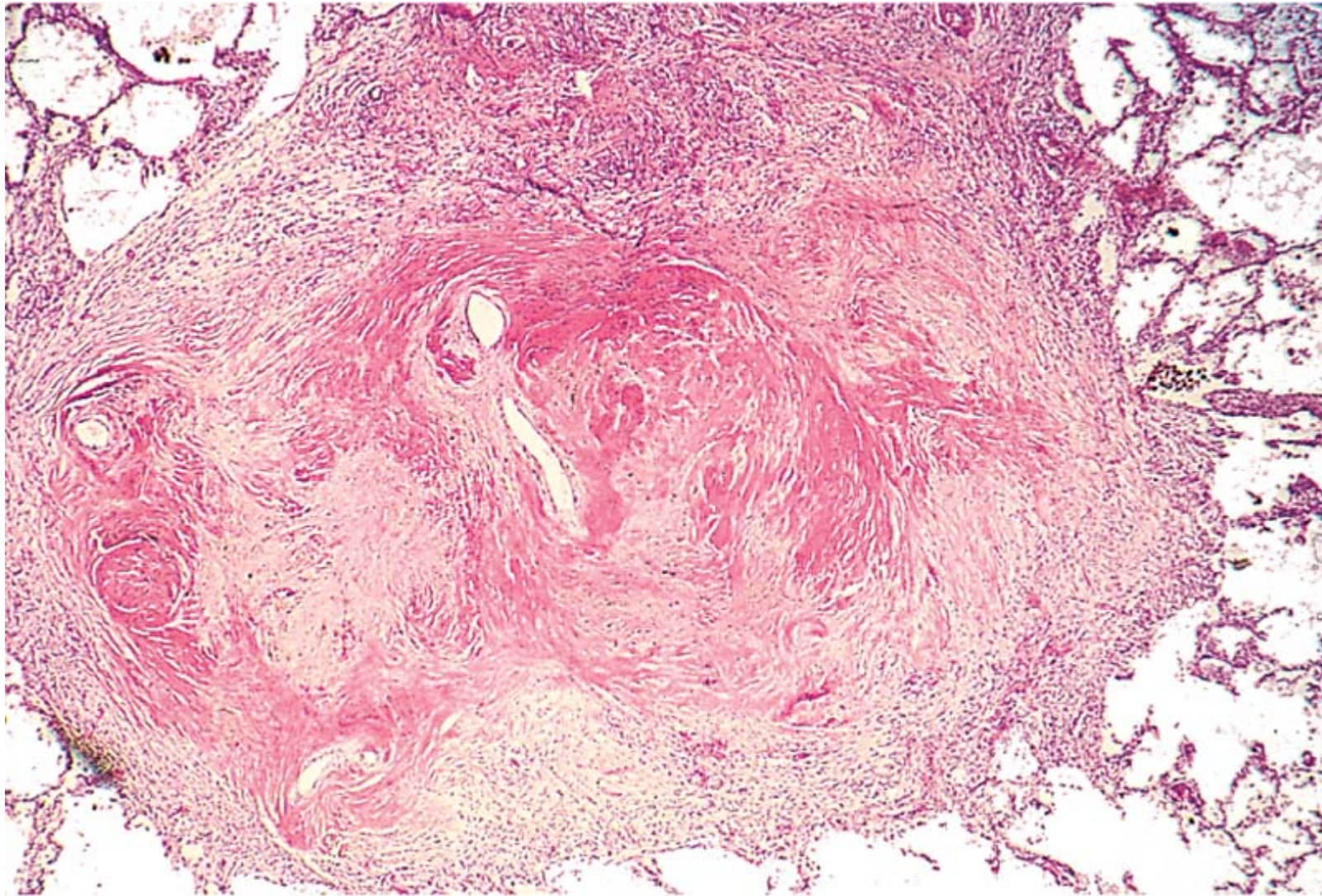
- Silicotic nodules
 - Tiny, barely palpable, discrete, pale-to-blackened (if coal dust is also present) nodules in the upper zones of the lungs
 - Concentrically arranged hyalinized collagen fibers surrounding an amorphous center.
 - “Whorled” appearance
 - By polarized microscopy reveals weakly birefringent silica particles, primarily in the center of the nodules.

Morphology

- Individual nodules may coalesce into hard, collagenous scars, with eventual progression to PMF.
- The intervening lung parenchyma may be compressed or overexpanded, and a honeycomb pattern may develop.
- Fibrotic lesions may also occur in the hilar lymph nodes and pleura.



Advanced silicosis seen on transection of lung. Scarring has contracted the upper lobe into a small dark mass (*arrow*). Note the dense pleural thickening. (Courtesy of Dr. John Godleski, Brigham and Women's Hospital, Boston, Massachusetts.)



© Elsevier. Kumar et al: Robbins Basic Pathology 8e - www.studentconsult.com

Several coalescent collagenous silicotic nodules. (Courtesy of Dr. John Godleski, Brigham and Women's Hospital, Boston, Massachusetts.)

Clinical Course

- Silicosis is usually detected in routine chest radiographs performed on asymptomatic workers.
- Pulmonary hypertension and cor pulmonale
- Silicosis is associated with an increased susceptibility to tuberculosis.
- The relationship between silica and *lung cancer* has been a contentious issue.

Complications

- Tuberculosis
- Cor pulmonale
- Emphysema

SUMMARY

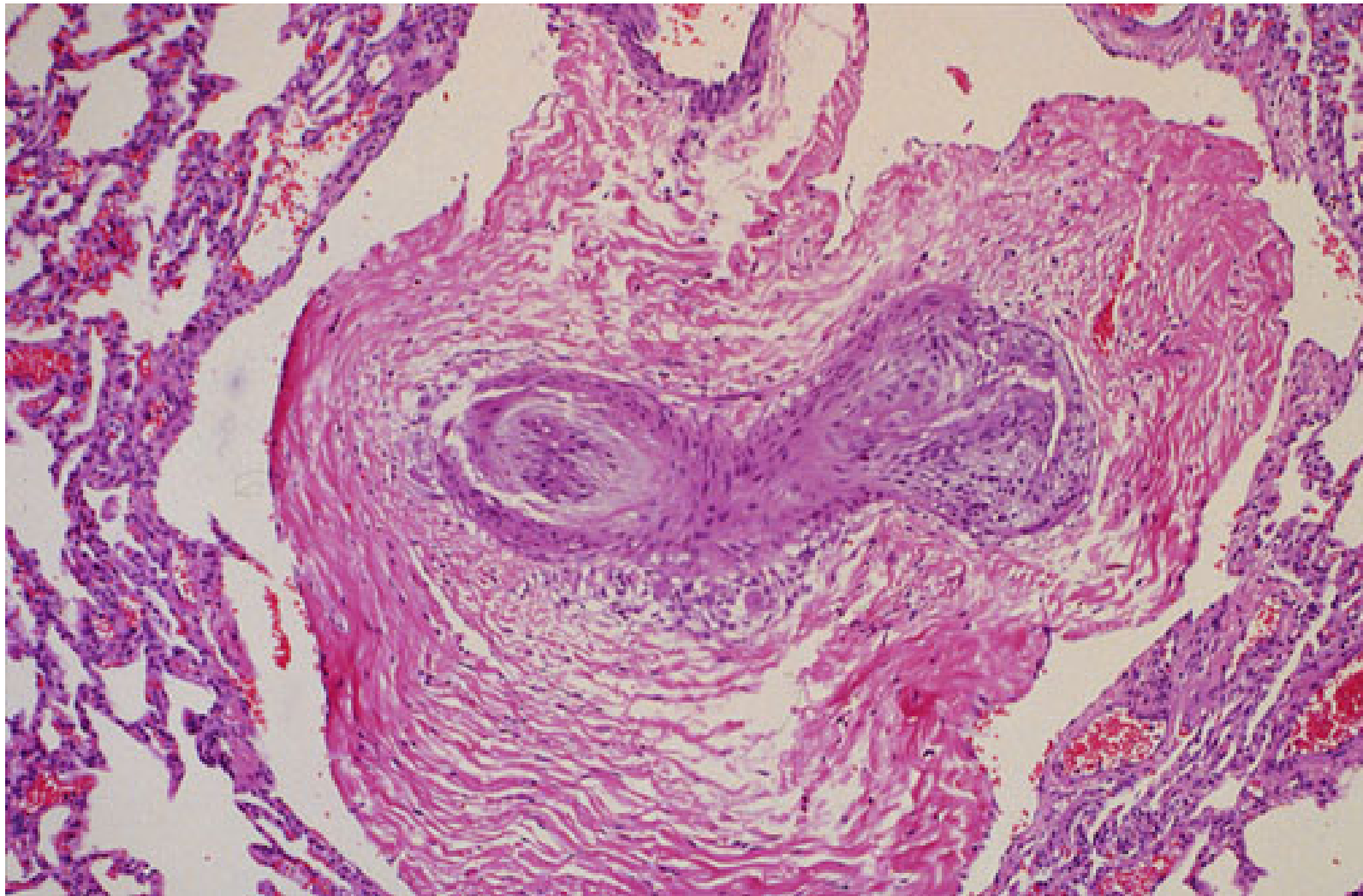
- Silicosis is the most common pneumoconiosis in the world, and crystalline silica (e.g., quartz) is the usual suspect.
- The manifestations of silicosis can range from asymptomatic silicotic nodules to PMF; individuals with silicosis also have an increased susceptibility to tuberculosis.
- The relationship between silica exposure and subsequent lung cancer is controversial.

Cor pulmonale (Pulmonary Hypertensive Heart Disease)

- Right ventricular hypertrophy, dilation, and potentially failure secondary to pulmonary hypertension caused by disorders of the lungs or pulmonary vasculature.
- *Acute cor pulmonale*
 - Follow massive pulmonary embolism.
- *Chronic cor pulmonale*
 - Right ventricular hypertrophy (and dilation) secondary to prolonged pressure overload caused by obstruction of the pulmonary arteries or arterioles or compression or obliteration of septal capillaries.

Pathogenesis

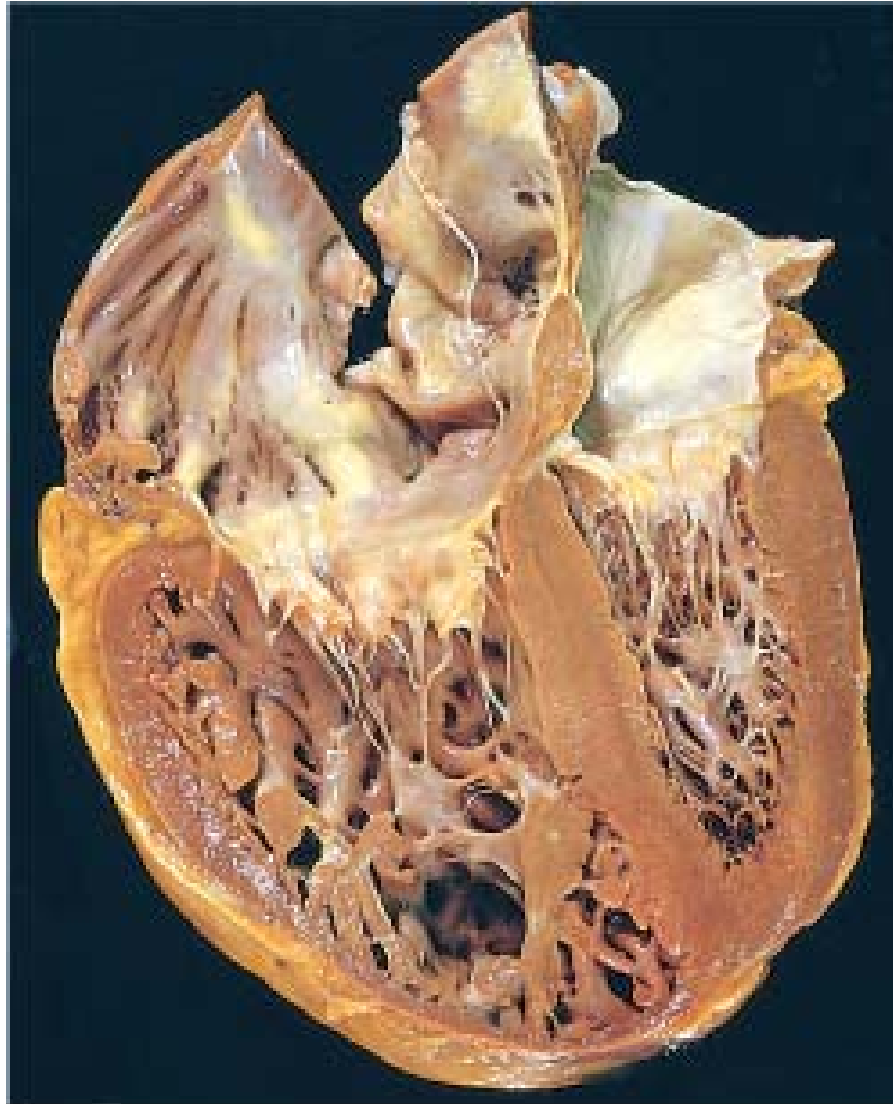
- Diseases of the Pulmonary Parenchyma
 - Chronic obstructive pulmonary disease
- Diseases of the Pulmonary Vessels
 - Primary pulmonary hypertension
- Disorders Affecting Chest Movement
 - Marked obesity
- Disorders Inducing Pulmonary Arterial Constriction
 - Metabolic acidosis



The loss of normal lung parenchyma leads to pulmonary hypertension that leads to thickening of the small arteries along with reduplication to form a plexiform lesion, as seen here in a peripheral pulmonary artery.

Morphology

- The right ventricle and atrium may also be dilated.
- The right ventricular wall thickens, sometimes up to 1.0 cm or more.
- Thickening of the muscle bundles in the outflow tract.



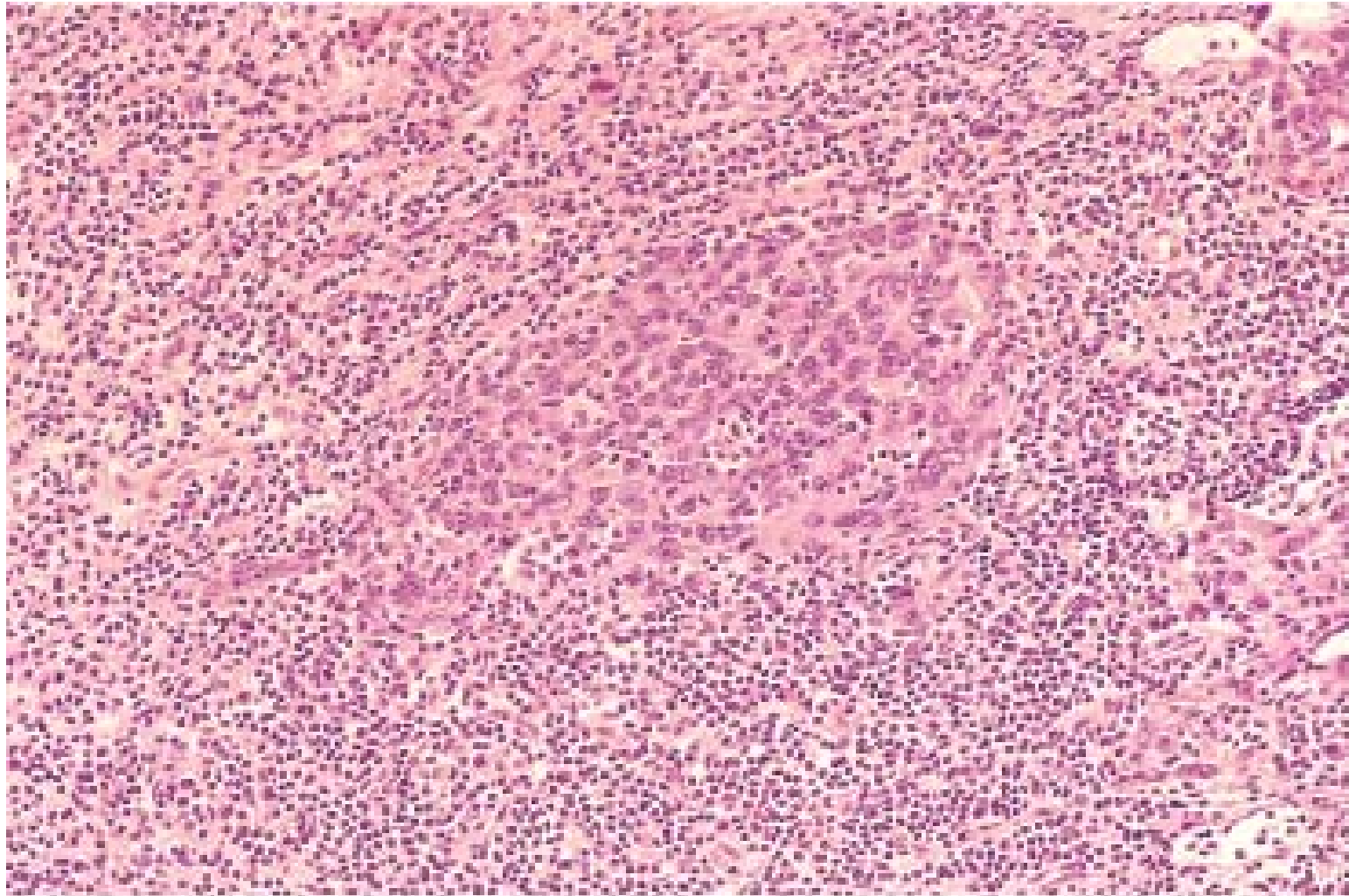
Chronic cor pulmonale, characterized by a markedly dilated and hypertrophied right ventricle, with thickened free wall and hypertrophied trabeculae (apical four-chamber view of heart, right ventricle on left). The shape of the left ventricle (to the right) has been distorted by the right ventricular enlargement.

Nasopharyngeal Carcinoma

- Distinctive geographic distribution
- Close anatomic relationship to lymphoid tissue
- Association with EBV infection

Three patterns

- Keratinizing squamous cell carcinoma
- Nonkeratinizing squamous cell carcinoma
- Undifferentiated carcinoma



© Elsevier 2005

Nasopharyngeal carcinoma, lymphoepithelioma type. The syncytium-like nests of epithelium are surrounded by lymphocytes. (Courtesy of Dr. James Gulizia, Brigham and Women's Hospital, Boston, MA.)

Lung cancer

- Lung cancer is currently the most frequently diagnosed major cancer in the world and the most common cause of cancer mortality worldwide.
- Cancer of the lung occurs most often between ages 40 and 70 years, with a peak incidence in the fifties or sixties.
- The 5-year rate for all stages combined is only 15%.

Etiology and Pathogenesis

- Cigarette smoking
 - Passive smoking increases the risk of developing lung cancer to approximately twice that of nonsmokers.
- Industrial Hazards
- Air Pollution
- Molecular Genetics

Precursor Lesions

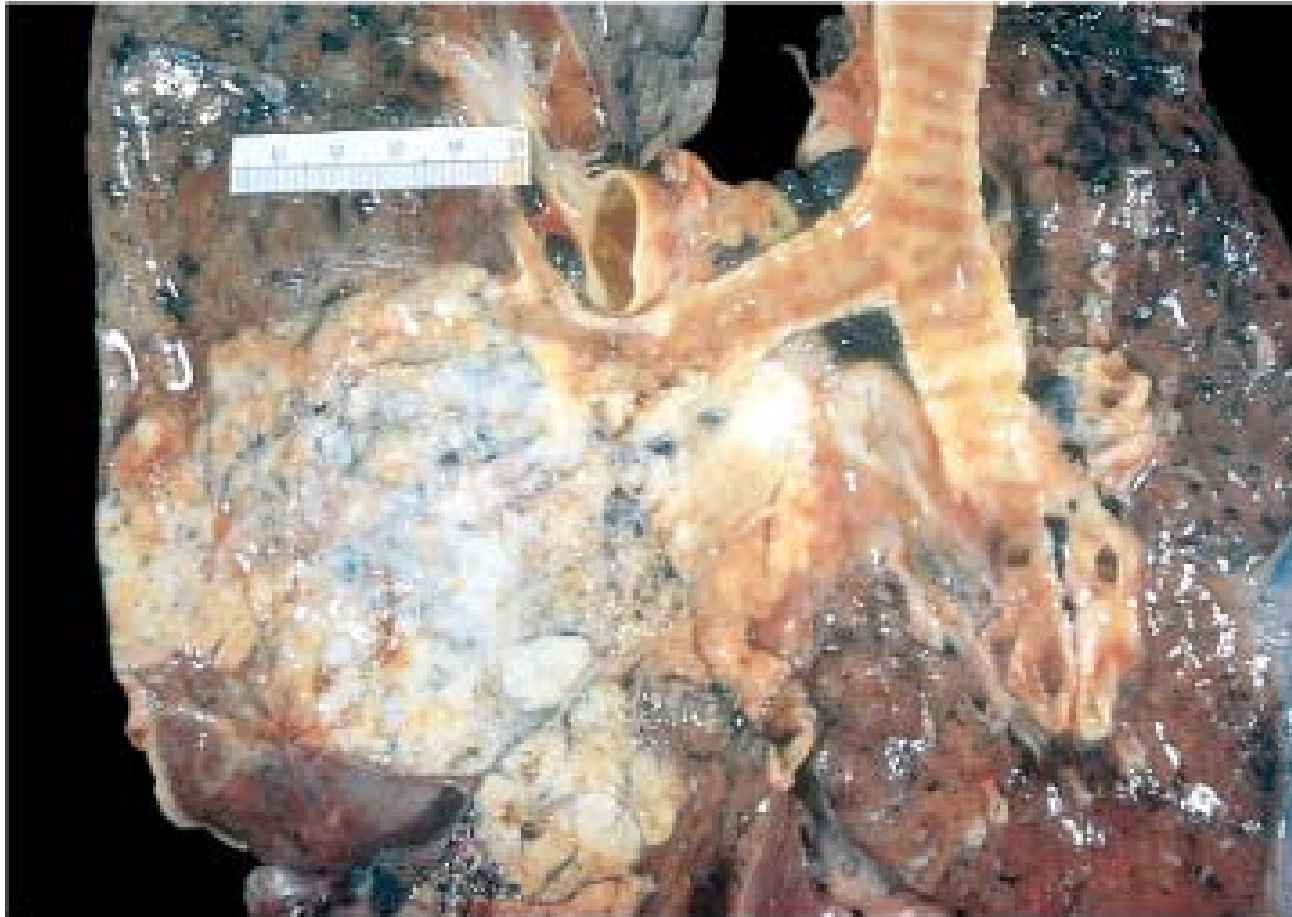- Squamous dysplasia and carcinoma in situ
- Atypical adenomatous hyperplasia
- Diffuse idiopathic pulmonary neuroendocrine cell hyperplasia

Classification

- Squamous cell carcinoma (25% to 40%)
- Adenocarcinoma (25% to 40%)
- Small cell carcinoma (20% to 25%)
- Large cell carcinoma (10% to 15%)

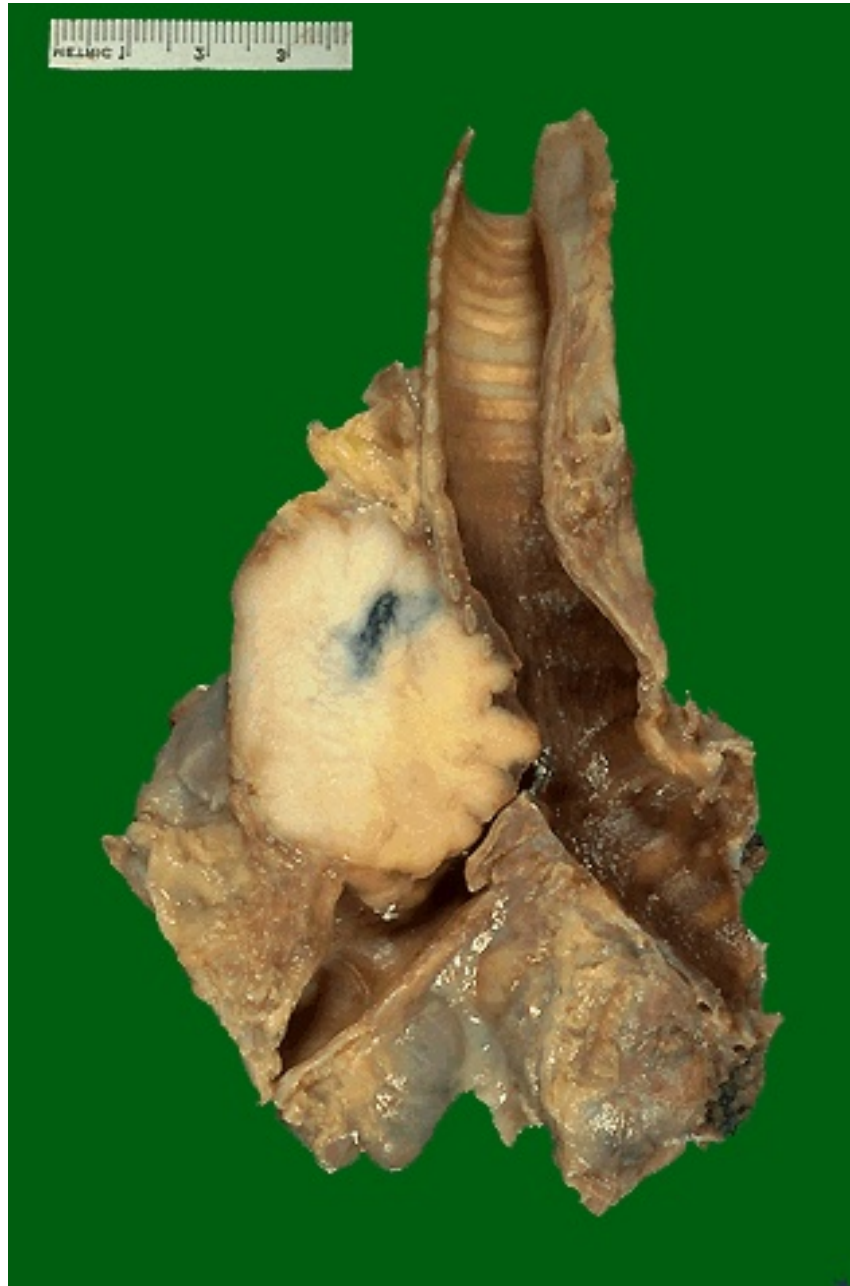Histologic Classification of Malignant Epithelial Lung Tumors

Squamous cell carcinoma
Small cell carcinoma
Combined small cell carcinoma
Adenocarcinoma
Acinar; papillary, bronchioloalveolar, solid, mixed subtypes
Large cell carcinoma
Large cell neuroendocrine carcinoma
Adenosquamous carcinoma
Carcinomas with pleomorphic, sarcomatoid, or sarcomatous elements
Carcinoid tumor
Typical, atypical
Carcinomas of salivary gland type
Unclassified carcinoma

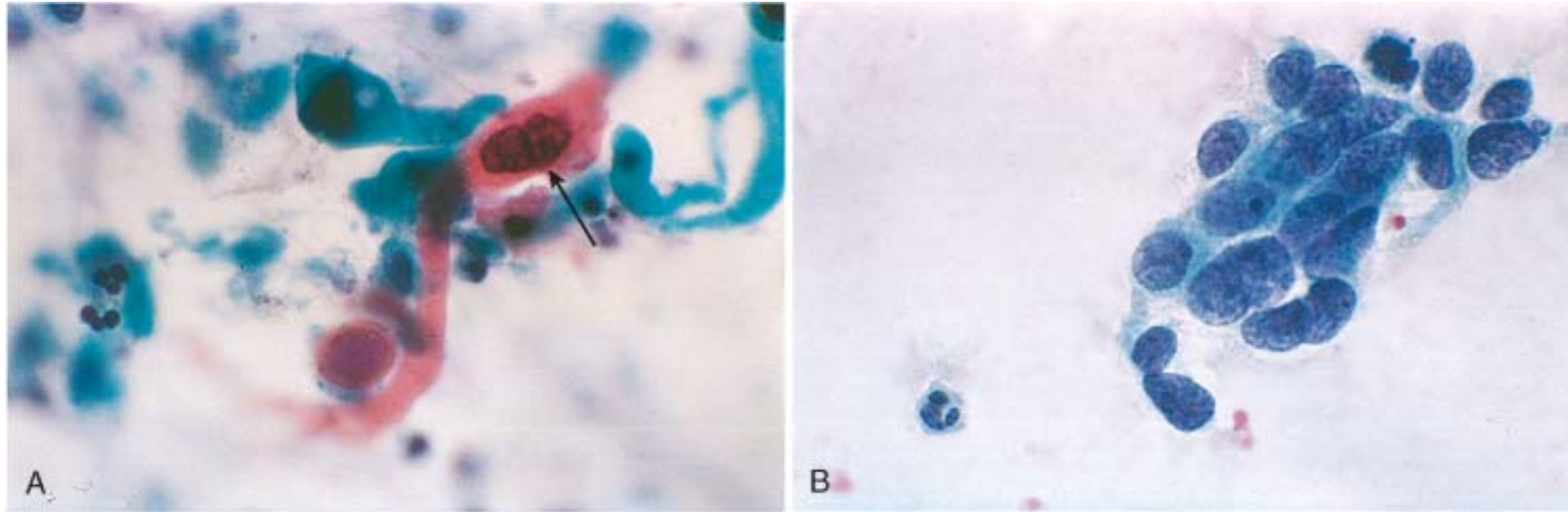


© Elsevier 2005

Lung carcinoma. The gray-white tumor tissue is seen infiltrating the lung substance. Histologically, this large tumor mass was identified as a squamous cell carcinoma.

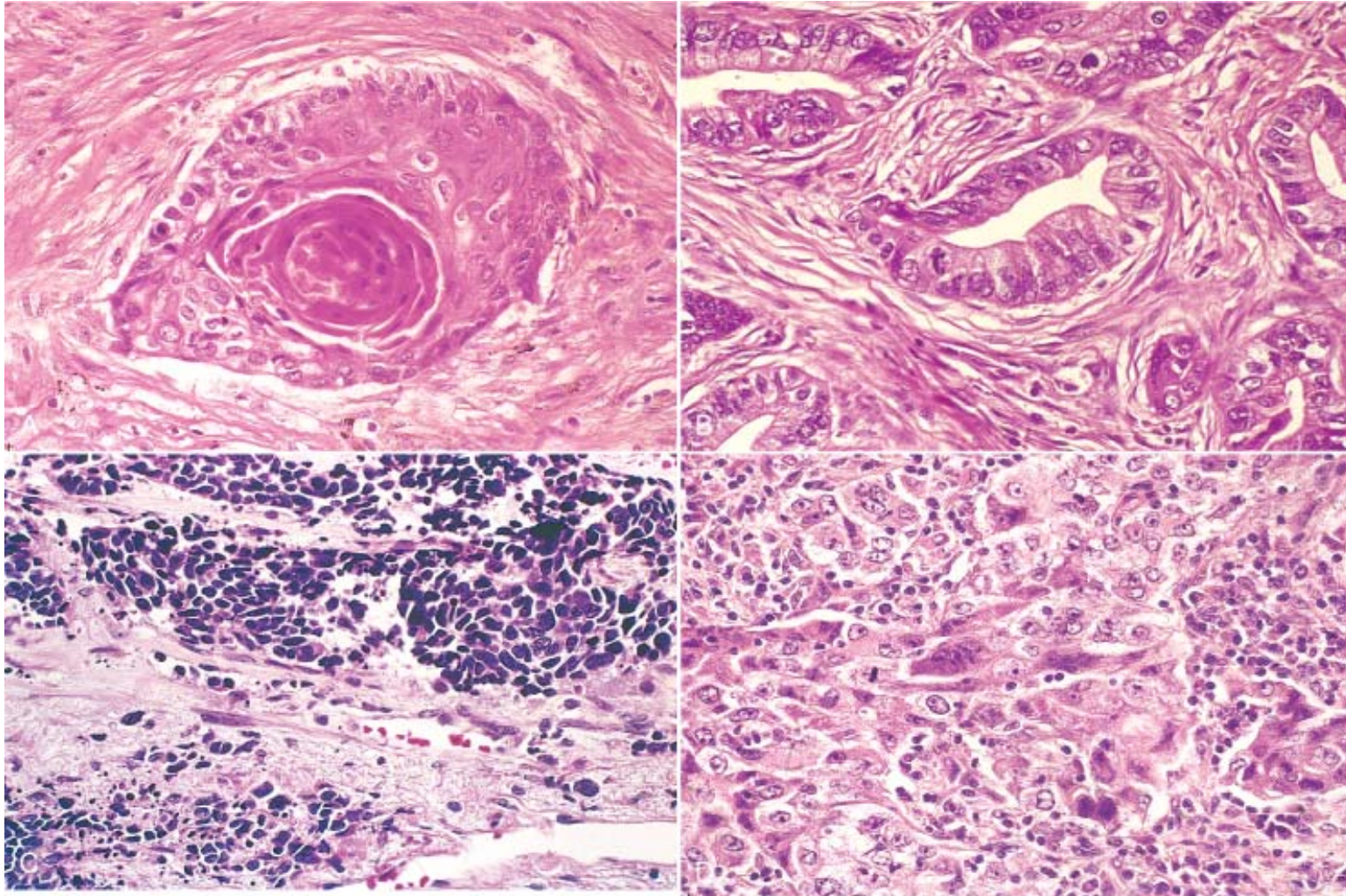


This is a squamous cell carcinoma of the lung that is arising centrally in the lung (as most squamous cell carcinomas do). It is obstructing the right main bronchus. The neoplasm is very firm and has a pale white to tan cut surface.



© Elsevier 2005

Cytologic diagnosis of lung cancer is often possible. *A*, A sputum specimen shows an orange-staining, keratinized squamous carcinoma cell with a prominent hyperchromatic nucleus (*arrow*). *B*, A fine-needle aspirate of an enlarged lymph node shows clusters of tumor cells from a small cell carcinoma, with molding and nuclear atypia characteristic of this tumor; note the size of the tumor cells compared with normal polymorphonuclear leukocytes in the left lower corner.



© Elsevier 2005

Histologic appearance of lung carcinoma. *A*, Well-differentiated squamous cell carcinoma showing keratinization. *B*, Gland-forming adenocarcinoma. *C*, Small cell carcinoma with islands of small deeply basophilic cells and areas of necrosis. *D*, Large cell carcinoma, featuring pleomorphic, anaplastic tumor cells and absence of squamous or glandular differentiation.

Local Effects of Lung Tumor Spread

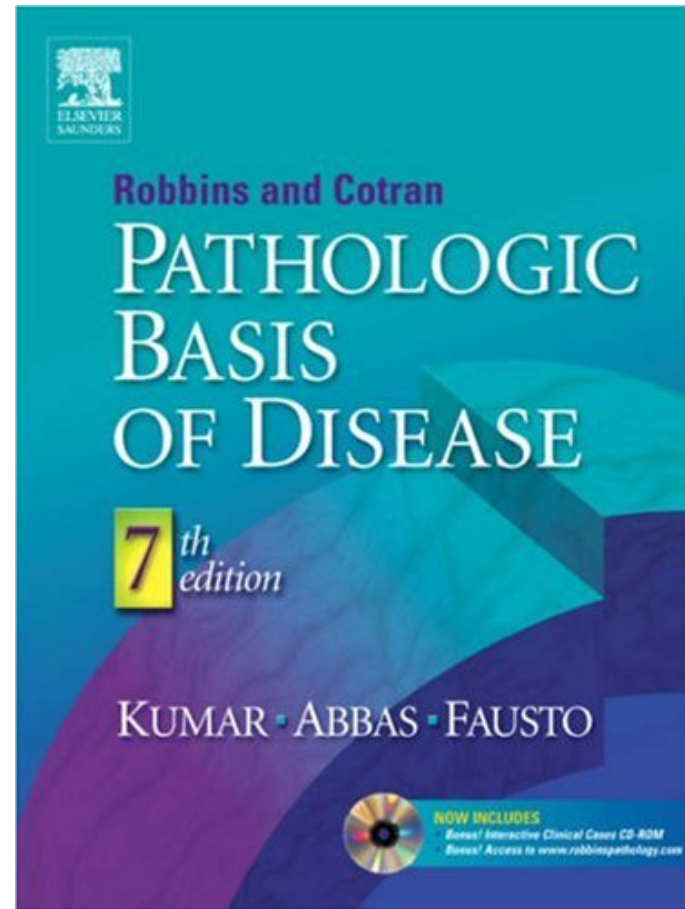

Clinical Feature	Pathologic Basis
Pneumonia, abscess, lobar collapse	Tumor obstruction of airway
Lipid pneumonia	Tumor obstruction; accumulation of cellular lipid in foamy macrophages
Pleural effusion	Tumor spread into pleura
Hoarseness	Recurrent laryngeal nerve invasion
Dysphagia	Esophageal invasion
Diaphragm paralysis	Phrenic nerve invasion
Rib destruction	Chest wall invasion
SVC syndrome	SVC compression by tumor
Horner syndrome	Sympathetic ganglia invasion
Pericarditis, tamponade	Pericardial involvement

SUMMARY

- The four major histologic subtypes are adenocarcinomas (most common), squamous cell carcinoma, large-cell carcinoma, and small-cell carcinoma (SCLC).
- Smoking is most important risk factor for lung cancer; adenocarcinomas are most common cancers to arise in women and nonsmokers.
- Precursor lesions include squamous dysplasia (for squamous cancer) and atypical adenomatous hyperplasia (for some adenocarcinomas).
- Bronchioloalveolar carcinomas are a subtype of adenocarcinomas characterized by absence of stromal invasion and growth along preexisting structures. Lung cancers, particularly SCLCs, can cause *paraneoplastic syndromes*.

Advanced Reading

- <http://10.10.10.151/Able.Acc2.Web/PageCourseDetail.aspx?ID=7387&isbulid=1>
- <http://10.71.121.151/pathology/>
- <http://library.med.utah.edu/WebPath/webpath.html>



<http://www.studentconsult.com/default.cfm>

<http://www.robbinspathology.com/default.cfm>