

## Determination of *Coxiella burnetii* in bovine foetuses using PCR and immunohistochemistry

M. OZKARACA<sup>1</sup>, S. CERIBASI<sup>2</sup>, A.O. CERIBASI<sup>2</sup>, A. KILIC<sup>3</sup>, S. ALTUN<sup>1</sup>,  
S. COMAKLI<sup>1</sup>, H. ONGOR<sup>2</sup>

<sup>1</sup>Faculty of Veterinary Medicine, Ataturk University, Erzurum, Turkey

<sup>2</sup>Faculty of Veterinary Medicine, Firat University, Elazig, Turkey

<sup>3</sup>Sivrice Vocational High School, Firat University, Elazig, Turkey

**ABSTRACT:** This study was aimed at detection of *Coxiella burnetii* in bovine foetuses using polymerase chain reaction (PCR) and immunohistochemistry (IHC) and at an estimation of its frequency in Eastern Turkey. Stamp, Giemsa, and Gimenez stains were used in addition to PCR and IHC to determine the presence of *C. burnetii* in samples from 70 bovine foetuses. While the staining methods did not detect the agent by direct visualisation of *C. burnetii* on smears, PCR and IHC identified its presence in two of the foetuses. The distribution of antigens in these two foetuses was, in decreasing order of concentration, in the spleen, the thymus, the lungs, the liver, and the kidneys. We conclude that *C. burnetii* diagnosis in bovine foetuses can be reliably performed using PCR and IHC. In addition, the frequency of 1.42% of *C. burnetii* positivity in bovine foetuses reported here was the first time that the presence of this agent was determined in Eastern Turkey.

**Keywords:** Q fever; diagnostic method; IHC; cow; Eastern Turkey

*Coxiella burnetii* is an obligatory intracellular pathogen that causes a disease that leads to abortion in sheep, goats, and cattle (Rady et al. 1985; Maurin and Raoult 1999; Bildfell et al. 2000; Sanchez et al. 2006). Such abortions may occur along with other problems including low birth weight, death of new-born cattle, failure to expel the placenta, endometritis, and infertility (Plommet et al. 1973; Behymer et al. 1976; Bildfell et al. 2000). The infectious agent is reported to be present in the blood, lungs, spleen, and liver during the early stages, while in the chronic phase it moves to glandular breast tissue and the placenta (Kim et al. 2005; Borriello and Galiero 2012). In the placenta, it has been found in trophoblasts and mononuclear cells (Bildfell et al. 2000). *C. burnetii* is reported to be transmitted by environmental contamination with placental secretions, vaginal mucus, faeces, milk, and similar products from infected animals (Berri et al. 2000; Rodolakis et al. 2007).

*C. burnetii* has a membrane similar to that of Gram-negative bacteria and does not take up the Gram stain (Maurin and Raoult 1999). *C. burnetii* is generally stained using the Gimenez method in both clinical specimens and laboratory cultures (Gimenez

1964). Methods such as egg embryo examination, cell culture, laboratory animal experimentation, PCR, IHC, and *in situ* hybridisation are typically used to isolate or identify the agent (Maurin and Raoult 1999; Bildfell et al. 2000; Jensen et al. 2007).

Serological studies testing for the presence of *C. burnetii* in cattle have found prevalence rates around the world varying from 3.4% to 84% (Adesiyun et al. 1984; Behymer et al. 1985; Marrie et al. 1985; Houwers and Richardus 1987; McQuiston et al. 2002). However, studies on the presence of *C. burnetii* in bovines in Turkey remain somewhat limited (Seyitoglu et al. 2006; Kirkan et al. 2008).

This study was aimed at identifying the presence of *C. burnetii* in samples from 70 bovine aborted foetuses using PCR and IHC, and at estimating its frequency in Eastern Turkey.

### MATERIAL AND METHODS

**Study sample.** The study population consisted of 70 bovine abortions collected in Elazig and neighbouring districts in 2012 and 2013.

**Infectious agent staining and isolation.** Foetal tissue samples (from brain, liver, lungs, and spleen) were homogenised with a sterile mortar and pestle with phosphate-buffered saline (PBS) containing 1000 UI/ml each of penicillin and streptomycin sulphate. The homogenates were centrifuged for 15 min at 4000 rpm in a refrigerated centrifuge at 4 °C. The supernatant was passed through 0.45 µm pore filters, transferred to 1 ml sterile cryovials, and kept at –80 °C. For the isolation of *C. burnetii*, 0.2 ml of the supernatant were inoculated into the yolk sacs of 6- to 8-day-old chicken egg embryos and incubated for 4–13 days at 37 °C. After the fourth day, eggs that displayed embryonal death were opened and preparations were made from the yolk sac membranes. The samples were then stained using the Stamp, Giemsa, and Gimenez methods. The yolks of the dead egg embryos were removed and used for DNA extraction. The isolates obtained were identified using PCR.

**DNA isolation and PCR.** The QIAamp DNA Extraction Kit (Qiagen tissue kit) was used to extract DNA from the collected samples. DNA was isolated from the yolk sacs and pooled organ tissue suspensions following the manufacturer's instructions for the QIAamp kit. The tissue samples were centrifuged for 15 min at 4000 rpm after homogenisation with PBS containing 1000 UI/ml each of penicillin and streptomycin sulphate, following which they were kept at –40 °C until the bacterial suspension could be analysed. At the time of analysis, 200 µl aliquots were transferred into 1.5 ml Eppendorf tubes and 180 µl of buffer ATL and 20 µl of proteinase K were added. This suspension was incubated for 3 h at 56 °C and then vortexed. Then, 200 µl of buffer AL were added and the suspension was incubated for 10 min at 70 °C, and then vortexed for 15 s. Following vortexing, 200 µl of ethanol were added and the suspension was vortexed and transferred to QIAamp minispin column tubes and centrifuged for 1 min at 8000 rpm. The supernatant was discarded following centrifugation. The QIAamp minispin column was placed inside a new collection tube, 500 µl of buffer Aw1 was added, and the tubes were centrifuged for 1 min at 8000 rpm. Then, 500 µl of buffer Aw2 was added after the removal of the supernatant and the tubes were centrifuged at 14 000 rpm for 3 min. The column tubes were then placed inside new microcentrifuge tubes, 200 µl of elution buffer were added, and they were centrifuged for 1 min at 8000 rpm before being frozen at –20 °C until PCR analysis was performed.

The 50 µl PCR reactions contained 25 µl of PCR master mix (2×) (Thermoscientific, Catalog No: K0171), 1 µM of each primer, 18 µl of water, and 5 µl of target DNA. A genus-specific primer pair based on the repetitive area of the transposon of the *C. burnetii* strain, consisting of *trans*-1:5'-TGG TAT TCT TGC CGA TGA C-3' and *trans*-2:5'-GAT CGT AAC TGC TTA ATA AAC CG-3' was used (Hoover et al. 1992). The PCR thermocycling program began with five initial cycles in which the annealing temperature decreased by one degree each cycle, starting with pre-heating at 95 °C for 2 min, then 30 s at 94 °C, 1 min of annealing at 66–61 °C, and synthesis for 1 min at 72 °C. Cycles after this consisted of denaturation at 94 °C for 30 s, hybridisation at 61 °C for 30 s, and synthesis at 72 °C for 1 min; this was repeated for a total of 40 cycles, after which samples were incubated at 72 °C for a further 10 min. The resulting PCR products were then subjected to electrophoresis in a 1.5% agarose gel at 70 V for 1 h. Following electrophoresis, the gel was stained with ethidium bromide and the results read by ultraviolet (UV) transillumination. The presence of a 687-bp band in the PCR product was considered as positive for *C. burnetii*.

**Positive control:** The *C. burnetii* reference strain used as a positive control was provided by Dr. Mustapha Berri, Institute National de la Recherche Agronomique (INRA), France.

**Histologic examination.** Tissues samples were fixed in 10% buffered formalin and prepared according to common methods; paraffin blocks were sliced to a thickness of 5 µm in a microtome and studied using light microscopy following haematoxylin-eosin staining.

**Immunohistochemistry.** Paraffin-embedded sections prepared from abort samples (tissue from the lungs, liver, brain, spleen, thymus, kidneys, and muscle) were immunochemically stained using a streptavidin-biotin-peroxidase complex method. A commercially available kit (Dako LSAB) was used for immunohistochemistry. Following deparaffinisation and rehydration, 5-µm-thick lung sections were maintained for 10 min in a 3% hydrogen peroxide solution to block endogenous peroxidase activity. The tissues were then incubated consecutively for 5 min each in two separate PBS solutions. Subsequently, they were treated for 15 min in a microwave oven with a ready-to-use antigen retrieval solution, then cooled to room temperature, incubated for 10 min in the blocking solution, and

doi: 10.17221/138/2015-VETMED

finally incubated for 30 min at 37 °C in anti-*C. burnetii* hyperimmune serum (1/500). The aborted tissues used as controls were incubated in distilled water only, then washed with PBS. After 15 min of this treatment, the control tissues were placed in streptavidin for 10 min, washed again with PBS, and incubated for 5 min in DAB chromogen. Tissues were then counterstained with Mayer’s haematoxylin solution and sealed in mounting medium. The anti-*C. burnetii* hyperimmune serum was obtained from Dr. Hasan Ongor (Department of Veterinary Microbiology, Firat University, Turkey).

The immunopositivity observed with light microscopy was semi-quantitatively estimated using the following scale: absent (–), mild (+), moderate (++), and intense (+++).

**RESULTS**

**Infectious agent staining**

Eggs with observed embryonal death were opened and preparations were made from the yolk sac membranes. The samples were stained using the Stamp, Giemsa, and Gimenez methods. No *C. burnetii* strain could be isolated in direct smears from the pooled samples from foetal tissues, but *C. burnetii* DNA was detected in the yolk sacs of embryonated eggs after passaging. Stained smears of the yolk sacs were examined to ensure the absence of bacterial contamination and to demonstrate the presence of *C. burnetii*. The presence of large masses of red-coloured coccobacilli was seen in Gimenez-stained yolk sac impressions. The isolates were further confirmed using PCR.

**DNA isolation and PCR**

PCR on DNA extracted from a suspension of the pooled tissue samples from 70 aborted foetuses did not detect *C. burnetii* DNA. However, PCR performed with DNA extracted from egg yolk preparations gave positive reactions for *C. burnetii* DNA

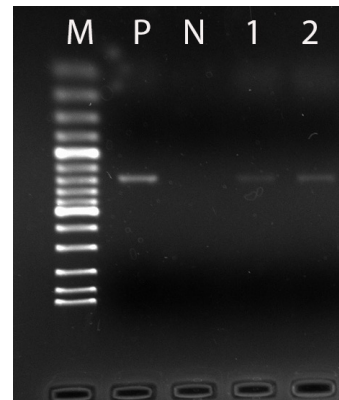


Figure 1. Appearance of *C. burnetii* PCR products on an agarose gel stained with ethidium bromide. M = 100 bp DNA ladder; P = positive control, N = negative control; 1–2 = positive samples

in two of the 70 abortions (1.42%). We detected 687-bp positive bands by agarose gel electrophoresis of the PCR reactions (Figure 1).

**Histopathological findings**

Upon examination, samples from two of the bovine foetuses were found to be *C. burnetii*-positive. Spleen haemorrhage, thymus hyperaemia, and severe bronchopneumonia were observed (Figures 2–4). The livers showed multifocal inflammatory cell infiltration and degenerative or necrotic parenchymal cell collections of varying severity (Figure 5). The kidneys exhibited severe interstitial nephritis, proximal tubular cell necrosis and desquamation, and tubular dilation (Figure 6).

**Immunohistochemistry**

*C. burnetii* was detected using IHC in two out of 70 (1.42%) aborted bovine foetuses. The organ distribution of *C. burnetii* positivity is summarised in Table 1.

Immune positivity was intense in the spleen, moderate in the thymus and lung, and mild in the liver and the kidneys. Immune positivity was mainly concentrated in the lymphoid cells of the spleen and thymus (Figures 7 and 8), and in the in-

Table 1. Distribution of *C. burnetii* in various organs of two aborted bovine foetuses

	Spleen	Thymus	Lung	Liver	Kidney	Muscle	Brain
Sample 1	+++	++	+	+	–	–	–
Sample 2	+++	+	++	+	+	–	–



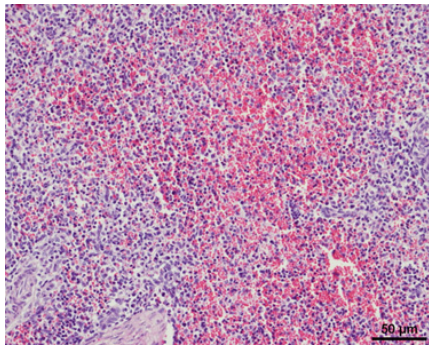


Figure 2. Haemorrhage in spleen, H-E

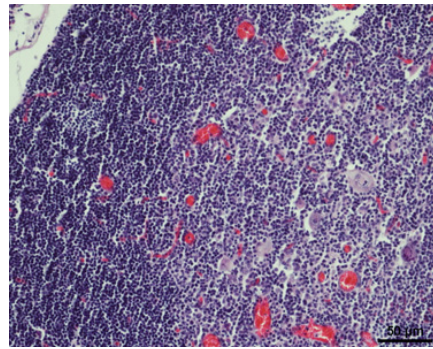


Figure 3. Hyperaemia in thymus, H-E

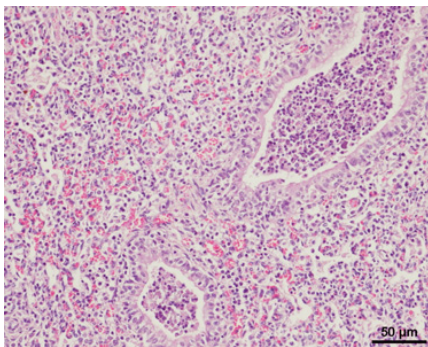


Figure 4. Bronchopneumonia in lung, H-E

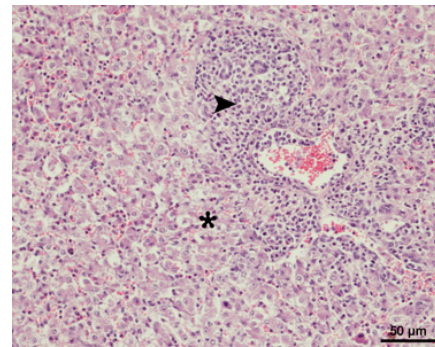


Figure 5. Degenerative-necrotic changes (\*) and inflammatory cell infiltration (arrowhead) in liver, H-E

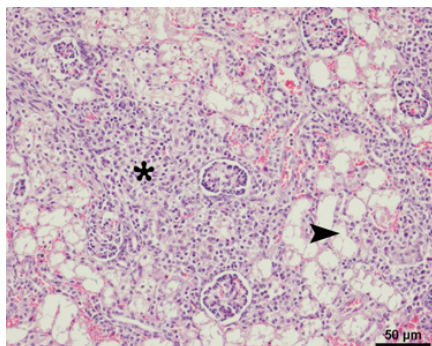


Figure 6. Severe interstitial nephritis (\*) and tubular necrosis (arrowhead) in kidney, H-E

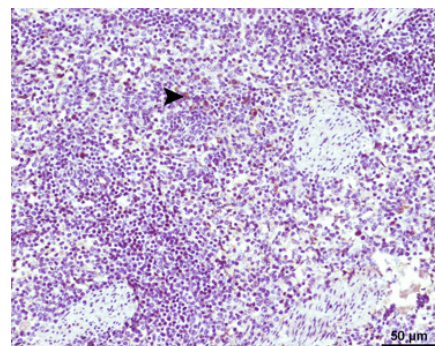


Figure 7. Immunopositivity in lymphoid cells of spleen (arrowhead), IHC

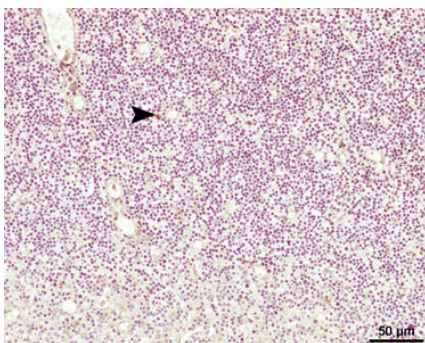


Figure 8. Immunopositivity in lymphoid cells of thymus (arrowhead), IHC

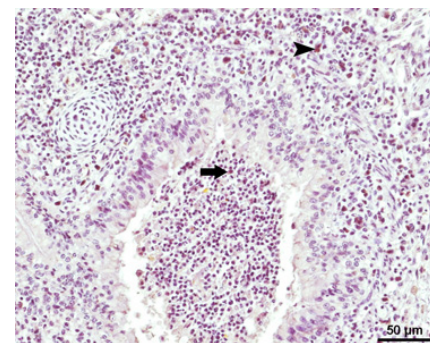


Figure 9. Immunopositivity in inflammatory exudate (arrow) and peribronchial area (arrowhead) of lung, IHC



doi: 10.17221/138/2015-VETMED

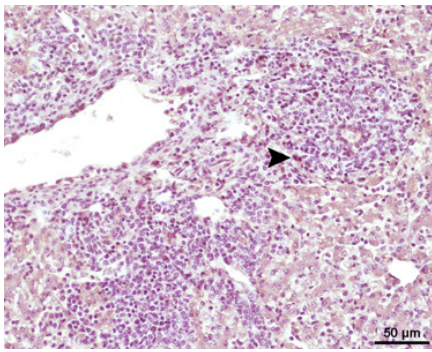


Figure 10. Immunopositivity in periportal cell infiltration (arrowhead) of liver, IHC

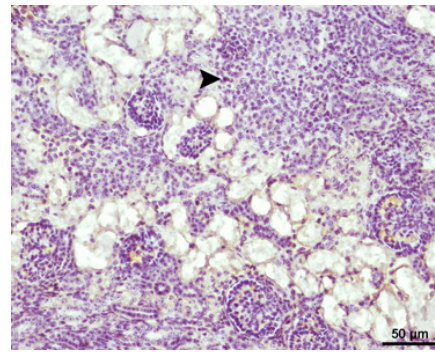


Figure 11. Immunopositivity in inflammatory cell infiltration (arrowhead) of intertubular in kidney, IHC

terstitial, peribronchiolar, and luminal bronchiolar mononuclear cells of the lungs (Figure 9).

Mild immune positivity was present in the hepatic periportal areas (Figure 10), and the inflammatory interstitial renal infiltrates (Figure 11).

## DISCUSSION

A limited number of studies have been performed examining the presence of *C. burnetii* in bovine, ovine, and caprine abortions in different countries (Sanchez et al. 2006; Szeredi et al. 2006; Jensen et al. 2007; Hazlett et al. 2013). Sheep abortions were positive for the presence of *C. burnetii* in 3.7% of cases in Germany (Plagemann 1989), 1% in Switzerland (Chanton-Greutmann et al. 2002), and 2% in Hungary (Szeredi et al. 2006). The prevalence in goat fetuses was 1% in Hungary (Szeredi et al. 2006), 10% in Switzerland (Chanton-Greutmann et al. 2002), and 0.1% in the USA (Moeller 2001). Positivity for the agent was also found in 17.2% of bovine abortions in Portugal (Clemente et al. 2009) and 11.6% in Italy (Parisi et al. 2006). A frequency of 1.42% *C. burnetii* positivity in bovine fetuses in Eastern Turkey was determined in this study. The variation among the different results may be due to differences among animal husbandry methods, other regional differences, or the application of vaccination programs.

While previous studies on *C. burnetii* prevalence have been performed in Turkey, no prior report was found on the presence of this agent in bovine abortions. Existing studies were performed on materials such as blood, milk, or abomasal contents. A study by Kirkan et al. (2008) examining 138 bovine blood samples using PCR detected *C. burnetii* in

six samples (4.3%). Positivity by immune serology and PCR was determined in 14 of 400 milk samples (3.5%) in a study by Ongor (2004). Dogru et al. (2010) reported no *C. burnetii* DNA in milk samples from seropositive sheep and cattle. As for the study on abomasal contents in 102 bovine, 45 ovine, and five caprine abortions by Gunaydin et al. (2015), the positivity rates for *C. burnetii* DNA were 3.92% ( $n = 4$ ), 11.11% ( $n = 5$ ), and 40% ( $n = 2$ ), respectively. We investigated the presence of *C. burnetii* in visceral samples of 70 bovine abortions collected from animal husbandry companies. Examinations were performed both by isolation on chicken embryo eggs and by PCR. PCR on egg yolk preparations from these embryo eggs as well as PCR and IHC on direct visceral samples detected *C. burnetii* DNA in two of the 70 abortions (1.42%). Cultures, PCR, and IHC results concurred exactly.

For infection with this agent, IHC has been applied more on the mothers and placentas than on foetal organs (Bildfell et al. 2000; Sanchez et al. 2006; Jensen et al. 2007; Muskens et al. 2012). Due to the fact that PCR revealed *C. burnetii* positivity in nine cases versus only four when using IHC in a study population of 100 bovine placentas with foetal abort viscera, Muskens et al. (2012) advanced the idea that IHC may be less sensitive than PCR. On the other hand, Hazzlet et al. (2014) observed that PCR may establish a diagnosis, but such a diagnosis must still be confirmed by another method, such as culture, staining, or IHC. There was no discrepancy between PCR and IHC results in our study. The difference in this respect with the study by Muskens et al. (2012) might be due to the infection stage.

The isolation of *C. burnetii* from aborted samples (foetus and placenta) represents the gold standard

for definitive diagnosis. High numbers of organisms are present in the amniotic fluids and placenta during birthing (e.g.,  $10^9$  bacteria/g placenta; Christie 1974). The foetal samples were sent to a routine diagnose laboratory, and the placentas were not analysed. For this reason, foetal samples were examined.

*C. burnetii* primarily infects the trophoblasts in the placenta (Baumgartner and Bachmann 1992; Sanchez et al. 2006). It has been proposed that *C. burnetii* is transported from the mother to the foetus by macrophages (Bildfell et al. 2000). The finding of immune positivity, especially in foetal organs such as the spleen and thymus, i.e. organs that are the richest in mononuclear cells like macrophages, seems to support such a hypothesis.

We diagnosed *C. burnetii* in bovine foetuses using PCR. We then performed IHC and *C. burnetii* was again diagnosed in these foetuses. Thus, the IHC analysis confirmed the PCR results. We conclude that *C. burnetii* diagnosis in bovine foetuses can be reliably performed using PCR and IHC. In addition, the frequency of 1.42% of *C. burnetii* positivity in bovine foetuses reported here was the first time that the presence of this agent was determined in Eastern Turkey.

## REFERENCES

- Adesiyun AA, Jagun AG, Tekdek LB (1984): Coxiella burnetii antibodies in some Nigerian dairy cows and their suckling calves. *International Journal of Zoonoses* 11, 155–160.
- Baumgartner W, Bachmann S (1992): Histological and immunocytochemical characterization of Coxiella burnetii-associated lesions in the murine uterus and placenta. *Infection and Immunity* 60, 5232–5241.
- Behymer DE, Biberstein EL, Riemann HP, Franti CE, Sawyer M, Ruppner R, Crenshaw GL (1976): Q fever (Coxiella burnetii) investigations in dairy cattle: challenge of immunity after vaccination. *American Journal of Veterinary Research* 37, 631–634.
- Behymer DE, Ruppner R, Brooks D, Williams JC, Franti CE (1985): Enzyme immunoassay for surveillance of Q fever. *American Journal of Veterinary Research* 46, 2413–2417.
- Berri M, Laroucau K, Rodolakis A (2000): The detection of Coxiella burnetii from ovine genital swabs, milk and fecal samples by the use of a single touchdown polymerase chain reaction. *Veterinary Microbiology* 72, 285–293.
- Bildfell RJ, Thomson GW, Haines DM, McEwen BJ, Smart N (2000): Coxiella burnetii infection is associated with placentitis in cases of bovine abortion. *Journal of Veterinary Diagnostic Investigation* 12, 419–425.
- Borriello G, Galiero G (2012): Coxiella burnetii. In: Lorenzo-Morales J (ed.): *Zoonosis*. InTech, Rijeka. 65–88.
- Chanton-Greutmann H, Thoma R, Corboz L, Borel N, Pospischil A (2002): Abortion in small ruminants in Switzerland: investigations during two lambing seasons (1996–1998) with special regard to chlamydial abortions. *Schweizer Archiv fur Tierheilkunde* 144, 483–492.
- Christie AB (1974): Q fever. In: Christie AB (ed.): *Infectious Diseases, Epidemiology and Clinical Practice*. Churchill Livingstone, Edinburgh. 876–891.
- Clemente L, Barahona MJ, Andrade ME, Botelho A (2009): Diagnosis by PCR of Coxiella burnetii in aborted fetuses of domestic ruminants in Portugal. *Veterinary Record* 164, 373–374.
- Dogru AK, Yildirim M, Unal N, Gazyagci S (2010): The relationship of Coxiella burnetii seropositivity between farm animals and their owners: A pilot study. *Journal of Animal and Veterinary Advances* 9, 1625–1629.
- Gimenez DF (1964): Staining rickettsiae in yolk sac cultures. *Stain Technology* 30, 135–137.
- Gunaydin E, Mustak HK, Sariyeyupoglu B, Ata Z (2015): PCR detection of Coxiella burnetii in fetal abomasal contents of ruminants. *Kafkas Universitesi Veteriner Fakultesi Dergisi* 21, 69–73.
- Hazlett MJ, McDowall R, DeLay J, Stalker M, McEwen B, Van Dreumel T, Spinato M, Binnington B, Slavic D, Carman S, Cai HY (2013): A prospective study of sheep and goat abortion using real-time polymerase chain reaction and cut point estimation shows Coxiella burnetii and Chlamydia abortus infection concurrently with other major pathogens. *Journal of Veterinary Diagnostic Investigation* 25, 359–368.
- Hoover AT, Vodkin MH, Williams JC (1992): A Coxiella burnetii repeated DNA element resembling a bacterial insertion sequence. *Journal of Bacteriology* 174, 5540–5548.
- Houwers DJ, Richardus JH (1987): Infections with Coxiella burnetii in man and animals in the Netherlands. *Zentralblatt fur Bakteriologie, Mikrobiologie und Hygiene* 267, 30–36.
- Jensen TK, Montgomery DL, Jaeger PT, Lindhardt T, Agerholm JS, Bille-Hansen V, Boye M (2007): Application of fluorescent in situ hybridisation for demonstration of Coxiella burnetii in placentas from ruminant abortions. *Acta Pathologica, Microbiologica, et Immunologica Scandinavica* 115, 347–353.
- Kim SG, Kim EH, Lafferty CJ, Dubovi E (2005): Coxiella burnetii in bulk tank milk samples, United States. *Emerging Infectious Diseases* 11, 619–621.

doi: 10.17221/138/2015-VETMED

- Kirkan S, Kaya O, Tekbiyik S, Parin U (2008): Detection of *Coxiella burnetii* in cattle by PCR. *Turkish Journal of Veterinary and Animal Sciences* 32, 215–220.
- Marrie TJ, Van Buren J, Fraser J, Haldane EV, Faulkner RS, Williams JC, Kwan C (1985): Seroepidemiology of Q fever among domestic animals in Nova Scotia. *American Journal of Public Health* 75, 763–766.
- Maurin M, Raoult D (1999): Q fever. *Clinical Microbiology Reviews* 12, 518–553.
- McQuiston JH, Childs JE (2002): Q fever in humans and animals in the United States. *Vector-Borne Zoonotic Diseases* 2, 179–191.
- Moeller RB (2001): Causes of caprine abortion: diagnostic assessment of 211 cases (1991–1998). *Journal of Veterinary Diagnostic Investigation* 13, 265–270.
- Muskens J, Wouda W, Von Banniseht-Wijismuller T, Van Maanen C (2012): Prevalence of *Coxiella burnetii* infections in aborted fetuses and stillborn calves. *Veterinary Record* 170, 260.
- Ongor H, Cetinkaya B, Karahan M, Acik MN, Bulut H, Muz A (2004): Detection of *Coxiella burnetii* by immunomagnetic separation-PCR in the milk of sheep in Turkey. *Veterinary Record* 154, 570–572.
- Parisi A, Fraccalvieri R, Cafiero M, Miccolupo A, Padalino I, Montagna C, Capuano F, Sottili R (2006): Diagnosis of *Coxiella burnetii*-related abortion in Italian domestic ruminants using single-tube nested PCR. *Veterinary Microbiology* 118, 101–106.
- Plagemann O (1989): The most frequent infectious causes of abortion in sheep in north Bavaria with special reference to Chlamydia and Salmonella infections. *Tierärztliche Praxis* 17, 145–148.
- Plommet M, Capponi M, Gestin J, Renoux G (1973): Fievre Q experimentale des bovines. *Annales de Recherches Veterinaires* 4, 325–346.
- Rady M, Glavits R, Nagy G (1985): Demonstration in Hungary of Q fever associated with abortions in cattle and sheep. *Acta Veterinaria Hungarica* 33, 169–176.
- Rodolakis A, Berri M, Hechard C, Caudron C, Souria UA, Bodier CC, Blanchard B, Camuset P, Devillechaise P, Natorp JC, Vadet JP, Arri Cau-Bouvery N (2007): Comparison of *Coxiella burnetii* shedding in milk of dairy bovine, caprine, and ovine herds. *Journal of Dairy Science* 90, 5352–5360.
- Sanchez J, Souriau A, Buendia AJ, Arricau-Bouvery N, Martinez CM, Salinas J, Rodolakis A, Navarro JA (2006): Experimental *Coxiella burnetii* infection in pregnant goats: a histopathological and immunohistochemical study. *Journal of Comparative Pathology* 135, 108–115.
- Seyitoglu S, Ozkurt Z, Dinler U, Okumus B (2006): The seroprevalence of Coxiellosis in farmers and cattle in Erzurum district in Turkey. *Turkish Journal of Veterinary and Animal Sciences* 30, 71–75.
- Szeredi L, Janosi S, Tenk M, Tekes L, Bozso M, Deim Z, Molnar T (2006): Epidemiological and pathological study on the causes of abortion in sheep and goats in Hungary (1998–2005). *Acta Veterinaria Hungarica* 54, 503–515.

Received: 2015–05–26

Accepted after corrections: 2016–06–14

## Corresponding Author:

Mustafa Ozkaraca, Ataturk University, Faculty of Veterinary Medicine, Department of Pathology,  
25240 Erzurum, Turkey  
E-mail: mustafaozkaraca55@hotmail.com