



Case Report:

Vogt-Koyanagi-Harada Syndrome in a 10 Years Old Child.

Aalia R Sufi, Sumera Zargar, Tejit Singh,

Department of Ophthalmology, Government Medical College, Srinagar, Jammu & Kashmir, India.

Address for Correspondence:

Dr. Sufi Aalia R,

610- F Bagh- e-Haider,

Hyderpora Bypass,

Srinagar, Jammu & Kashmir,

India.

E-mail: aaliarasool_s@yahoo.com

Citation: Sufi AR, Zargar S, Singh T. Vogt-Koyanagi-Harada Syndrome in a 10 Year Old Child. *Online J Health Allied Scs.* 2011;10(2):24

URL: <http://www.ojhas.org/issue38/2011-2-24.htm>

Open Access Archives: <http://cogprints.org/view/subjects/OJHAS.html> and <http://openmed.nic.in/view/subjects/ojhas.html>

Submitted: May 29, 2011; Accepted: Jul 16, 2011; Published: Jul 30, 2011

Abstract: The Vogt-Koyanagi-Harada (VKH) syndrome is a rare systemic disorder of uveitis, dysacusia, vitiligo, premature graying of the hair, eyebrows and eyelashes, and meningo-encephalitis. Although frequently unrecognised, VKH may affect children. We report a case of a 10 year old girl who presented with headache and dimness of vision and was diagnosed as papillitis on the basis of bilateral disc edema. However over the course of time developed skin changes (poliosis, vitiligo over lower back) and depigmented patches in inferior fundus suggesting diagnosis of VKH disease. Thus the diagnosis is difficult in the absence of extraocular manifestations. In such cases the diagnosis is based on clinical evolution of the disease.

Key Words: Vogt-Koyanagi-Harada Syndrome; Poliosis; Vitiligo; Uveitis.

Introduction:

Vogt-Koyanagi-Harada syndrome (VKH) is a bilateral granulomatous panuveitis associated with cutaneous, neurological and auditory manifestations.¹ Vogt was the first to report a case in 1906.² Later similar cases were reported by Koyanagi in 1929,³ after which the entity was identified as Vogt-Koyanagi syndrome characterised by anterior uveitis with poliosis, vitiligo and auditory disturbances. In 1926 Harada reported a patient with uveitis affecting the posterior segment with retinal detachment and meningeal irritation.⁴ These two disorders are known to overlap in many aspects and are now combined as a single entity as Vogt-Koyanagi-Harada disease.^{1,5}

The etiopathogenesis of VKH syndrome remains unknown. Clinically the disease is categorized into distinct phases:

1. Prodomal Phase: consisting of neurological symptoms-headache, fever, tinnitus followed by blurring of vision 1 or 2 days later.
2. Uveitic Phase: consisting of bilateral exudative retinal detachment, vitritis, disc hyperemia.
3. Chronic Phase: consisting of depigmentation of inferior fundus (sunset glow appearance), Dalen-Fuchs nodules.
4. Recurrent Phase: consisting of anterior uveitis and subretinal neovascularisation.

Systemic associations such as auditory signs (tinnitus, vertigo) and neurological signs (fever, headache, cerebrospinal fluid pleocytosis) occur at the onset of the disease. Dermal signs (poliosis, vitiligo) occur after 2-3 months of onset.⁶

Case Report:

A ten years old female child complained of headache and nausea of four days duration. This was followed by blurring of vision for which she reported to the eye OPD. There was no history of ocular trauma or surgery. Evaluation revealed visual status of 20/400 in the right eye and 20/800 in the left eye. Her pupils reacted sluggishly to light. Fundus examination showed hyperemic discs with blurred margins. MRI was done which was normal. Based on the findings, patient was diagnosed as bilateral papillitis following which she received three doses of intravenous methylprednisolone 500 mg for three days and was discharged on 40 mg prednisolone which was gradually tapered. Her vision improved to 20/30 in the right eye and 20/60 in the left eye. However the patient reported back after two weeks with complaint of diminution of vision. Examination revealed vision of 20/80 in both eyes. Slit lamp examination showed posterior synechiae with pigment dispersion over the cornea and anterior lens capsule and fine keratic precipitates in both eyes. Fundus examination could not be done in view of hazy media. Routine investigations were normal. Patient was treated as a case of uveitis and again put on 40 mg prednisolone. Later systemic steroids were withdrawn as the patient complained of weight gain and was put on topical steroids. After a period of two months patient developed graying of eyelashes (Fig. 1) and hair (Fig. 2) with patches of vitiligo over lower back (Fig. 3). On subsequent follow up patient's fundus revealed clearing of media with the appearance of pin head size granulomas in the inferior quadrant and within a week depigmented patches appeared in the inferior quadrant of the fundus (Fig. 4, Fig. 5). The patient was kept on 5 mg prednisolone on alternate days and attained visual acuity of 20/30 in the right eye and 20/40 in the left eye.

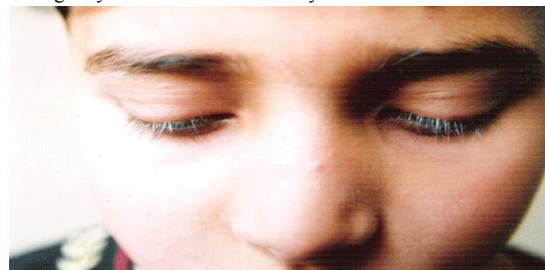


Figure 1: Graying of eyelashes

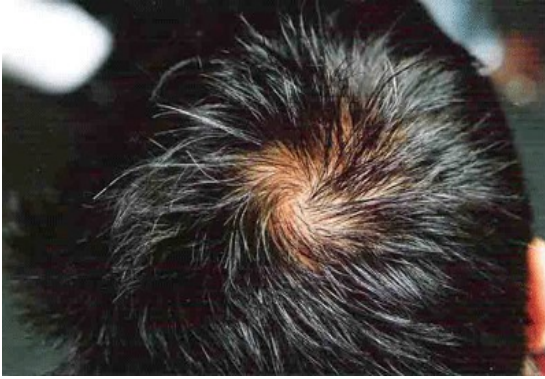

Figure 2: Graying of hair

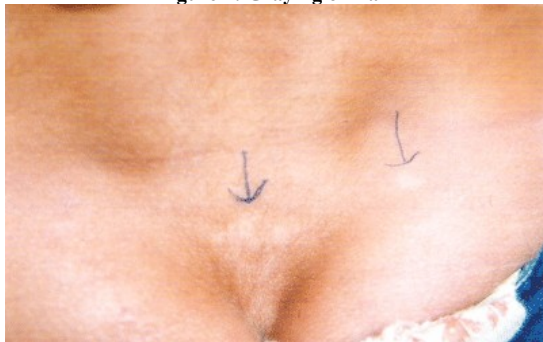

Figure 3: Patches of vitiligo over lower back

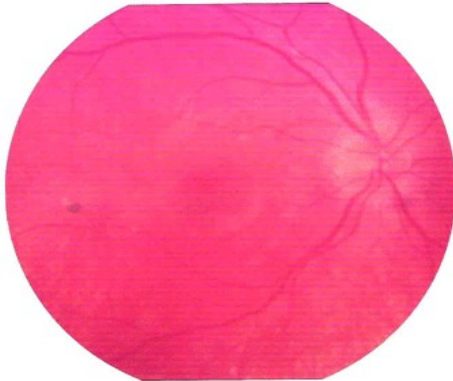


Figure 4: Sunset glow fundus in the chronic phase of Vogt-Koyanagi-Harada disease of right eye. The fundus has a reddish appearance and numerous small depigmented dots in the inferior quadrant.

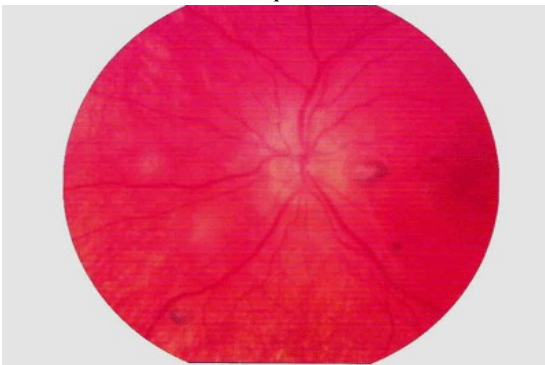


Figure 5: Sunset glow fundus in the chronic phase of Vogt-Koyanagi-Harada disease of the left eye. The fundus has a reddish appearance and numerous small depigmented dots in the inferior quadrant.

Discussion:

The patient was diagnosed as a case of Vogt-Koyanagi-Harada syndrome according to the revised criteria for diagnosis of VKH.⁷ However this diagnosis was attained after the disease manifested its extraocular associations of poliosis, vitiligo and developed sunset glow appearance of the fundus later in the course of the disease. Also the reason due to which the initial diagnosis of VKH was not made was that VKH is primarily a disease of adults with maximum frequency of onset in the thirties. It is rarely seen in children. According to a survey in Aravind Eye hospital, three out of 98 patients (about 3%) attending the uveitis clinic were children less than 16 years of age.⁸

Our case also highlights the rare initial presentation of VKH as bilateral disc edema. Retinal edema has been reported to present as the first sign of retinal involvement which is followed by exudative retinal detachment.⁹ However our patient did not develop retinal detachment. This can be attributed to the early administration of steroids which prevented development of retinal detachment.

Thus the diagnosis of the Vogt-Koyanagi-Harada (VKH) syndrome, especially in children is difficult due to the rarity of its occurrence in this age group, the variable onset of clinical signs and symptoms in the course of the disease and absence of diagnostic serological parameters.

References:

1. Moorthy RS, Inomata H, Rao NA. Vogt-Koyanagi-Harada syndrome. *Surv Ophthalmol* 1995;39:265-292.
2. Vogt A. Fruhzeitiges Ergrauen der Zilien und Bemerkungen uber den sogenannten plotzlichen Eintritt dieser Veranderung. *Klin Monatsbl Augenheilk* 1906;44:228-242.
3. Koyanagi Y. Dysakusis, Alopecia und Poliosis bei schwerer Uveitis nicht traumatischen Ursprungs. *Klin Monatsbl Augenheilk* 1929;82:194-211.
4. Harada E. On the acute diffuse choroiditis. *Acta Soc Ophthalmol Jpn* 1926;30:356-378.
5. Suguira S. Vogt-Koyanagi-Harada disease. *Jpn J Ophthalmol* 1978;22:9-35.
6. Inomata H. Vogt-Koyanagi-Harada Disease. In: Yanoff M, Duker JS, editors. *Ophthalmology*. 2nd ed. Missouri: Mosby; 2004. pp. 1196-1198.
7. Russel WR, Holland GN, Rao NA, Tabarra KF, Ohno S, Arellanes-Garcia L, et al. Revised diagnostic criteria for Vogt-Koyanagi-Harada disease: report of an International Committee on Nomenclature. *Am J Ophthalmol* 2001;131:647-652.
8. Rathinam SR, Vijayalakshmi P, Namperumalsamy P, Nozik RA, Cunningham ET. Vogt-Koyanagi-Harada syndrome in children. *Ocular Immunology & Inflammation* 1998;6(3):155-161.
9. Sawhney R, Jain R, Kumar S, Pannu BKS, Sood S. Glucose intolerance and Vogt-Koyanagi-Harada Syndrome. *Asian Journal of Ophthalmol* 2002;4:8-10.