



Case Report:

Primary Fallopian Tube Carcinoma

Prasad K Shetty, Balaiah K, Bafna UD, Gnana Prakash S,
Department of Pathology, Gynec-Oncology and Radiology, Bhagwan Mahaveer Jain Hospital, Bangalore, India.

Address For Correspondence:

Dr. Prasad K Shetty,
Department of Pathology,
Bhagwan Mahaveer Jain Hospital,
Millers Road, Vasanthnagar,
Bangalore-560052, India.
E-mail: dr.pkshetty@gmail.com

Citation: Shetty PK, Balaiah K, Bafna UD, Gnana Prakash S. Primary Fallopian Tube Carcinoma. *Online J Health Allied Scs.* 2010;9(4):26

URL: <http://www.ojhas.org/issue36/2010-4-26.htm>

Open Access Archives: <http://cogprints.org/view/subjects/OJHAS.html> and <http://openmed.nic.in/view/subjects/ojhas.html>

Submitted: Oct 27, 2010; Accepted: Nov 3, 2010; Published: Jan 20, 2011

Abstract:

Primary Fallopian Tube Carcinoma (PFTC) is rare and accounts for about 0.3% of all gynecologic cancers. Less than 1500 cases have been reported in the literature. It arises in postmenopausal women and typically presents with abdominal pelvic pain, vaginal bleeding and watery discharge. However, a correct diagnosis is rarely achieved preoperative, and in many cases, the diagnosis is made after incidental surgery for unrelated conditions commonly being ovarian carcinoma. Compared with ovarian carcinoma, PFTC more often presents at early stages, but it has a worse prognosis. PFTC is usually managed in the same manner as ovarian cancer. We report a case of Left PFTC that presented as Left ovarian mass, and we briefly review the literature.

Key Words: Primary fallopian tube carcinoma; Ovary; CA 125.

Case Report:

A 61 year old female came with history of postmenopausal bleeding and abdominal pain since 2 months. She also gives history of vaginal watery discharge since 5 days. She attained menopause 9 years back. Her blood pressure was 130/80 mm Hg. On vaginal examination, cervix showed a small cervical erosion, the uterus was normal in size and mobile with a 8X8 cm mass felt through the left fornix and placed anteriorly in the pelvis. The right fornix was free.

Her hemogram, hepatic and renal functions were normal. Hb-sAg, HIV I and II were negative and urine examination were reported to be normal. X-ray chest was normal. Abdominal pelvic CT scan showed no abnormality in upper abdomen and revealed a uterus with normal echotexture, measuring 8.8 x 4.5x3.4 cm. Endometrial thickness was 3 mm. Right ovary measured 2.2 x 1.0 cm and had normal echotexture. Left ovary was enlarged, shows a tumor with predominantly solid component and measured 7.6 x 6.2 cm. There was no free fluid in the abdomen and pelvis.

Serum CA - 125 was 24.5 U/mL (Normal upto 35 U/mL). Pap smear showed inflammatory picture. Endometrial curetings showed atrophic endometrium Based on the above features a provisional diagnosis of ovarian malignancy was made and total abdominal hysterectomy with bilateral salpingo-oophorectomy, pelvic and aortic lymphnode dissection and omentectomy was done. Peritoneal washings were negative for malignant cells.

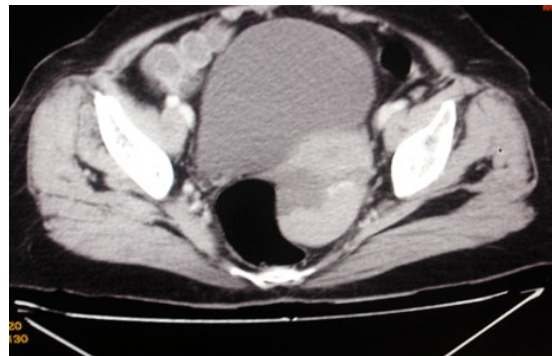


Figure 1: Abdominopelvic CT scan showing Left ovarian mass with solid cystic component.

On gross examination, uterus, right tube and both ovaries appeared normal, left fallopian tube was grossly dilated measuring 6x6cms, outer surface was smooth.

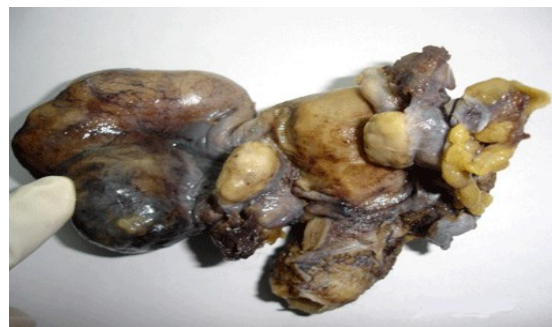

Figure 2: Uterus cervix with normal right adnexa and left ovary (finger points to grossly dilated Left fallopian tube)

Cut surface showed a gray white friable tumor dilating and occupying tubal lumen, tumor was solid with areas of haemorrhage.

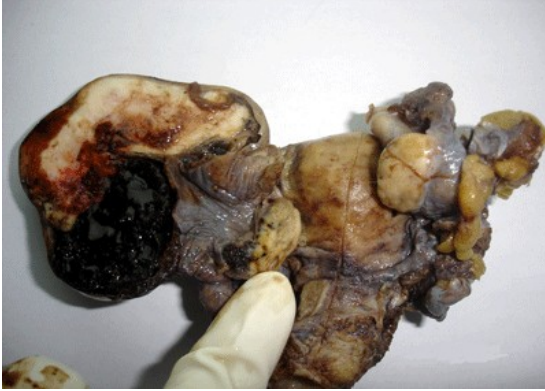

Figure 3: cut surface of Left tube with gray white tumor with hemorrhagic area within tubal lumen (finger points to normal left ovary)

The omentum measured 18x7 cm and was grossly unremarkable. On microscopic examination the left fallopian tube showed tumor arising from tubal epithelium infiltrating upto submucosa, muscular layer and serosa were free of tumor, tumor cells were arranged in solid sheets and papillary pattern, cells were moderately pleomorphic with high N/C ratio. There was no evidence of lymphovascular invasion.

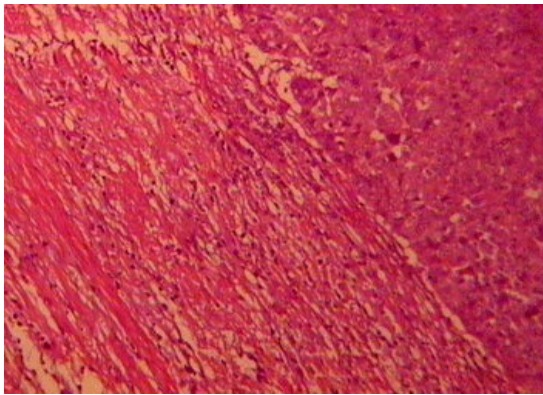


Figure 4: Hematoxylin and Eosin 10x showing tumor cells infiltrating upto submucosa

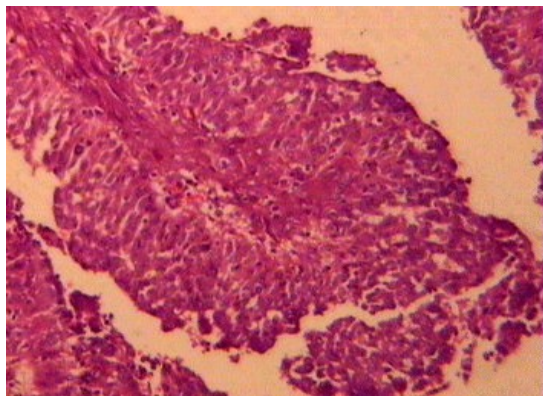


Figure 5: Hematoxylin and Eosin 10x shows tumor cells arranged in papillary pattern

There was no evidence of tumor metastasis elsewhere. Based on the histological features a diagnosis of PFTC morphologically papillary serous type FIGO Stage 1A Grade I was made. She had an uneventful post-operative recovery and was discharged from hospital on the 7th post-operative day.

Discussion:

Fallopian tube cancer was first described 1847. Since then, over 2000 cases have been reported in literature. PFTC is the least common of all gynecologic malignancies and the annual incidence about 3.6 per million women per year.¹

PFTC accounts for approximately 0.14 -1.8% of all female genital malignancies. The peak incidence is between the ages of 60 and 64 years, patients usually present with abnormal vaginal bleeding (47.5%), lower abdominal pain (39%), abnormal watery vaginal discharge (20%) and a palpable pelvic/abdominal mass (61%) (10) as seen in our case.¹⁻³ Tumor markers such as serum Ca-125 may be raised.⁴ Because of its rarity, the correct preoperative diagnosis is rarely made and it is usually an incidental diagnosis in patient undergoing an exploratory lapotomy. A correct diagnosis of PFTC was made preoperatively in only 4.6% of cases in the series of Alvarado-Cabrero et al.⁵ PFTC should be included in the differential diagnosis and especially if the patient has clinical symptoms such as vaginal discharge or abnormal genital bleeding with negative diagnostic curettage.⁶ On CT scan tumors are completely solid and others are predominantly cystic and the latter contain papillary projections or solid regions. Although rare, PFTC must be considered in the differential diagnosis of adnexal masses, and particularly in the presence of incomplete septations and a highly vascular, solid component.⁷

PFTC spreads by local invasion, transluminal migration and via the lymphatics and the bloodstream. Patients with PFTC have a higher rate of retroperitoneal and distant metastases than those patients with epithelial ovarian cancer. Metastases to the para-aortic lymph nodes have been documented in 33% of the patients with all stages of disease. The stage of disease at the time of diagnosis is the most important factor affecting the prognosis, PFTC carries five-year survival rates of about 68 -76% for Stage I disease, 27 - 42% for Stage II disease and 0 -6% for Stage III and IV disease so it is very important to diagnose these neoplasms in the early stages.^{8,9} Surgery is the treatment of choice for PFTC, and the surgical principles are the same as those used for ovarian cancer. The procedure of choice is abdominal total hysterectomy, bilateral salpingo-oophorectomy, omentectomy, selective pelvic and para-aortic lymphadenectomy for any stage for fallopian tube carcinoma. Microscopically all major types of carcinomas known to occur in ovary are reported, 95% of them being Papillary serous and 5% comprising of Endometrioid, Mucinous, Seromucinous, Clear cell and Transitional cell.¹⁰

Postoperative adjuvant chemotherapy is similar to that used for ovarian carcinoma. The diagnosis of PFTC is rarely considered preoperatively and it is usually first appreciated at the time of operation or after operation by the pathologist.^{8,9}

References:

1. Stewart SL, Wilke JM, FASTER SL. The incidence of primary fallopian tube cancer in the United States. *Gynecol Oncol* 2007;107(2):392-397
2. King A, Seraj IM, Thrasher T, Slater J, Wagner RJ. Fallopian tube carcinoma: a clinicopathological study of 17 cases. *Gynecol Oncol*. 1989;33:351-355.
3. Vaughan MM, Evans BD, Baranyai J, Weitzer MJ. Survival of patients with primary fallopian tube carcinoma. *Int J Gynecol Cancer*. 1998;8:16-22.
4. Kosary C, Trimble EL. Treatment and survival for women with fallopian tube carcinoma: a population-based study. *Gynecol Oncol*. 2002;86:190-191.
5. Alvarado-Cabrero I, Young RH, Vamvakas EC, Scully RE. Carcinoma of the fallopian tube: a clinicopathological study of 105 cases with observations on staging and prognostic factors. *Gynecol Oncol*. 1999;72:367-379.

6. Riska A, Leminen A, Pukkala E. Sociodemographic determinants of incidence of primary fallopian tube carcinoma, Finland 1953-97. *Int J Cancer*. 2003;104:643-645.
7. Slanetz PJ, Whitman GJ, Halpern EF, Hall DA, McCarthy KA, Simeone JF. Imaging of fallopian tube tumors. *Am J Roentgenol*. 1997;169:1321-1324.
8. Klein M, Rosen A, Lahousen M, Graf AH, Rancin A. Lymphadenectomy in primary carcinoma of fallopian tube. *Cancer Lett* 1999;147(1-2):63-66.
9. Benedet JL, Bender H, Jones H 3rd, Nagan HY, Pecorelli S. FIGO staging classifications and clinical practice guidelines in the management of gynaecological cancers. FIGO Committee on Gynecologic Oncology. *Int J Gynaecol Obstet* 2000;70:209-262.
10. Klein M, Rosen A, Lahousen M, Graf AH, Rainer A. The relevance of adjuvant treatment in primary carcinoma of fallopian tube stage 1 & 2: irradiation v/s chemotherapy. *Int J Radia Oncol Biol Phys* 2000;48(5):1427-1431.