

## Nerves originating from brachial plexus in the porcupine (*Hystrix cristata*)

A. AYDIN

Department of Anatomy, Faculty of Veterinary Medicine, Firat University, Turkey

**ABSTRACT:** In this study, dissemination of forelimb's nerves of the porcupine (*Hystrix cristata*) was investigated. Four porcupines (two males and two females) were used and nerves originating from brachial their plexus were dissected. Origin and dissemination of forelimb's nerves originated from brachial plexus constituted from cranial and caudal trunks were examined. Suprascapular nerve and the first branch of subscapular nerve originated from cranial and caudal part of cranial trunk, respectively. Nerves originated from caudal trunk, pectoral cranial nerves, constituted four branches spreading in pectoral muscles. Musculocutaneous nerve gives a branch to brachial muscle and, after giving medial cutaneous antebrachii nerve was divided to two branches (digital dorsal commun I and II nerve). Axillary nerve gives a branch to subscapular muscle and ends as cranial cutaneous antebrachii. Radial nerve separated to branches as ramus profundus and ramus superficial which also was divided to digital dorsal commun III and IV nerve and lateral cutaneous antebrachial nerve. Thoracodorsal nerve spreaded to latissimus dorsi muscle. Median nerve was divided to digital dorsal commun I, II, III and IV nerve. Ulnar nerve was divided to digital dorsal commun V and digital dorsal commun V nerve after giving caudal cutaneous antebrachii. An undefined nerve branch originated from caudal trunk entered coracobrachial muscle and biceps brachii muscle. Lateral thoracic and caudal pectoral nerves originated from caudal trunk. In the porcupine, branch which goes to coracobrachial muscle directly from caudal trunk of the brachial plexus and distributions of musculocutaneous, radial, ulnar and median nerves were different from rodentia and other mammals.

**Keywords:** nerves; forelimb; porcupines (*Hystrix cristata*); brachial plexus

**List of abbreviations:** m – musculus, A – cranial trunk, B – caudal trunk C – branch binding from cranial trunk to caudal trunk, C – cervical, T – thoracal

The porcupine is a member of Hystricidae family, a little group of rodentia (Weichert, 1970; Kuru, 1987; Demirsoy, 1992). On the structure of brachial plexus porcupines (Aydin, 2003), and distributions of the nerves originated from the brachial plexus have been studied in a variety of species including dog (Miller *et al.*, 1964; Tipirdamaz and Erden, 1988; Dursun *et al.*, 1994), cat (McClure *et al.*, 1973; Getty, 1975), Wervet monkey (Booth, 1991), Chacma baboon (Booth *et al.*, 1997), rabbit (Aslan, 1994; Yilmaz *et al.*, 1995), mouse (Cook, 1965) and rat (Green, 1968; Chiasson, 1980; Bertelli *et al.*, 1992). To the author's knowledge, this is the first study on nerves originating from the brachial plexus of porcupines (*Hystrix cristata*). The purpose of this

study was to document the branching patterns of the nerves originating from the brachial plexus of the porcupines (*Hystrix cristata*).

### MATERIAL AND METHODS

Four porcupines (two males and two females) killed by hunters were used. To document the nerve branches originating from the brachial plexus, skin and muscles were carefully dissected. The supply of the nerve branches originating from the brachial plexus in both forelimbs was examined and photographed. For the terminology, the Nomina Anatomica Veterinaria (1994) was used.

## RESULTS

In the porcupine, was found that plexus brachialis was formed by two trunks, called; cranial and caudal from which the nerves spread through forelimbs, are originated (Figure 1).

Suprascapular nerve originated from cranial part of cranial trunk, passed between *m. subscapularis* and *m. supraspinatus* at collum scapula level, existed at lateral face of scapula and continued through *m. supraspinatus* and *m. infraspinatus*.

Subscapular nervi were two nerves. The first one originated from cranial trunk and spreaded through subscapular muscle. The second one originated from caudal trunk with *n. axillaris* and dispersed to the caudal part of subscapular muscle and *teres major* muscle after leaving the *n. axillaris*.

Axillary nerve originated from the point that the branch coming from cranial trunk jointed to caudal trunk and after a short movement, divided two branches. First branch was given to *m. subscapularis* and *m. teres major*. This nerve at the level of collum scapula at the caudal of scapula coursed between *teres major* muscle and suprascapular muscle to the lateral face of scapula. After giving branches to *teres minor* and deltoid muscles it passed to lateral face of forelimb through the space between *caput lateralis* of *triceps brachii* muscle and deltoid muscle and gave the cutaneus brachii *lateralis cranialis* which spreaded to the cranial of lateral of forelimb and then continued as cranial cutaneous antebrachii nerve.

Thoracodorsal nerve arose from caudal trunk as two branches with *n. axillaris* and radial nerve and spreaded through *latissimus dorsi* muscle.

Radial nerve originated from the medial part of caudal trunk together with median nerve and ulnar nerve. At midway down of humerus, it passed between *caput medialis* and *caput lateralis* of *triceps brachii* muscle to the lateral face of arm and gave *rami musculares* to *tensor fascia antebrachii* muscle and *triceps brachii* muscle. First, it gave lateral cutaneous antebrachii nerve between *brachii* muscle and *caput lateralis* of *triceps brachii* muscle and then divided into two branches called *ramus profundus* and *ramus superficialis*. *Ramus profundus* distributes through extensor muscles on antebrachium. *Ramus superficialis* separated digital dorsal commun III and IV nerve on distal of antebrachium, descending on *extensor carpi radialis* muscle (Figure 2).

Median nerve was the longest nerve of plexus brachialis originating from caudal trunk in common with ulnar nerve and musculocutaneous as a common root. After leaving caudal trunk, first ulnar nerve and then near to distal of humerus, musculocutaneous nerve separated. Median nerve did not give any branch until *articulatio cubiti* level and then it gave two branches called; *rami muscularis* and *interosseus antebrachii* nerve on antebrachium. Then it ended as four branches; digital dorsal commun I, II, III, IV nerve, at the central level of palmar part of metacarpuses (Figure 3).

Ulnar nerve originated from caudal trunk together with median and musculocutaneous nerves and then separated from them. It gave the caudal cutaneous antebrachii nerve at the cauda of antebrachium and *rami musculares* at the level of cubital joint. The nerve divided into digital dorsal and palmar nerve V at caudomedial of antebrachium. Prior to spreading to the palmar and dorsal of the *digiti V* one branch originated from each of them spreaded to the skin and subcutaneous tissues of sole (Figure 2).

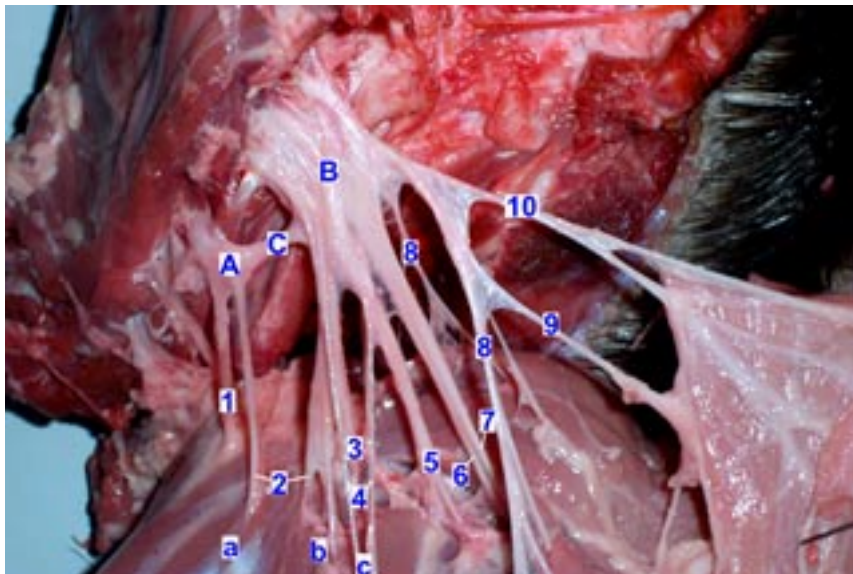
Cranial pectoral nerve had four branches, two spreading to pectoral descendens muscle, one to pectoral descendens muscle and pectoral transversus muscle, one together with lateral thoracic nerve and caudal pectoral nerve to cranial part of pectoral transversus muscle and pectoral ascendens muscle.

Lateral thoracic nerve originated from caudal trunk and passed through pectoral ascendens muscle. After giving a branch to cranial part of this muscle, it spreaded in cutaneous omobrachial muscle.

Caudal pectoral nerve originated from caudal trunk with lateral thoracic nerve, and gave two branches which spreaded to lower part of cutaneous trunci muscle and caudal part of pectoral ascendens muscle.

Undefined nerve branch originated from a point where a branch coming from cranial trunk bind to caudal trunk, coursed through *coracobrachialis* muscle and separated to two branches after giving a branch to this muscle. One of these branches passed through *biceps* muscle and the other merged cutaneous nerve transversally (Figure 4).

Musculocutaneous nerve initially coursed through distal of humerus together with median nerve and then separated from each other. This nerve at level of *articulatio cubiti*, gave *ramus muscularis distalis* to *brachialis* muscle and center of antebrachium, medial cutaneous antebrachii (going through skin and



A – cranial trunk, B – caudal trunk C – branch knocking cranial trunk and caudal trunk together, 1 – suprascapular nerve, 2 – subscapular nervi, 3 – axillary nerve, 4 – thoracodorsal nerve, 5 – radial nerve, 6 – median nerve, 7 – ulnar nerve, 8 – cranial pectoral nervi, 9 – lateral thoracic nerve, 10 – caudal pectoral nerve, a – subscapular muscle, b – teres major muscle, c – latissimus dorsi muscle

Figure 1. Lateral view of nerves originated from the brachial plexus in the porcines

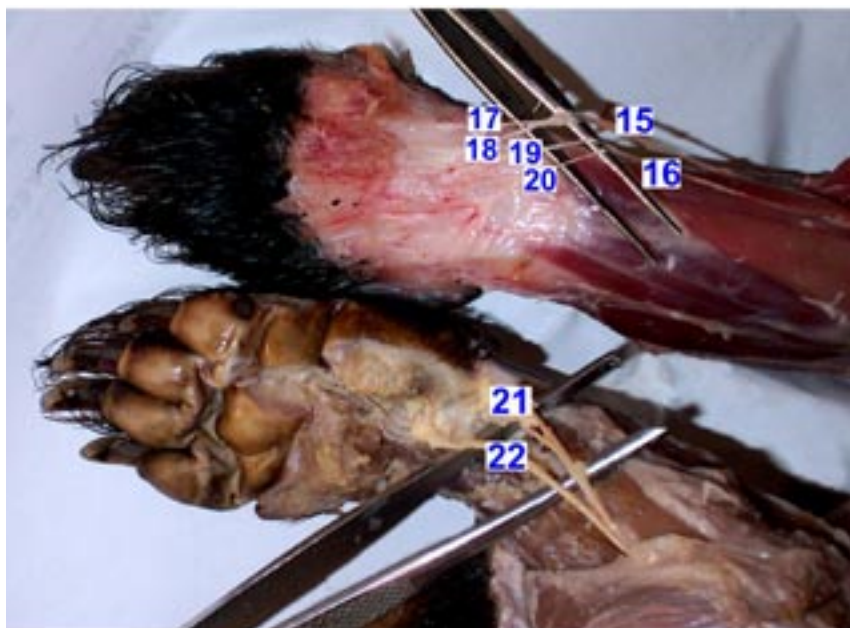
fascia), other branch divided digital dorsal commun I and II nerve at level of phalanx proximalis.

## DISCUSSION

Suprascapular nerve and subscapular nerves originate from C5 and C6 in rat (Green, 1968), rabbit (Aslan, 1994; Yilmaz *et al.*, 1995) Wervet monkey (Booth, 1991) and Chacma baboon (Booth *et*

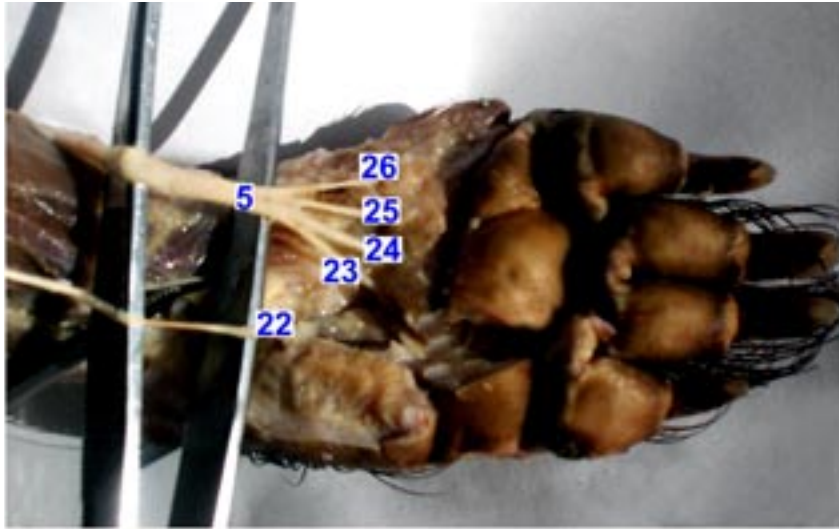
*al.*, 1997) and the present study determined a same finding. However, these nerves have been reported to originate from C6 and C7 in cats (McClure *et al.*, 1973; Getty, 1975; Aslan, 1994) and dog (Miller *et al.*, 1964; Getty, 1975; Tipirdamaz and Erden, 1988; Dursun *et al.*, 1994)

Axillary nerve receives contributions from the nerves driving from C5 to T1 in rat (Bertelli *et al.*, 1992) or only from C6 and C7 (Green, 1968), from C6 and C7 in rabbit (Aslan, 1994; Yilmaz *et*



15 – musculocutaneous nerve branche which go to dorsal surface of the phalanx, 16 – ramus superficial of radial nerve, 17 – digital dorsal commun I nerve, 18 – digital dorsal commun II nerve, 19 – digital dorsal commun III nerve, 20 – digital dorsal commun IV nerve, 21 – digital dorsal commun V nerve

Figure 2. View of the nerves which scattered to dorsal aspect of the forlimb digitis



22 – digital palmar commun V nerve, 23 – digital palmar commun IV nerve, 24 – digital palmar commun III nerve, 25 – digital palmar commun II nerve, 26 – digital palmar commun I nerve

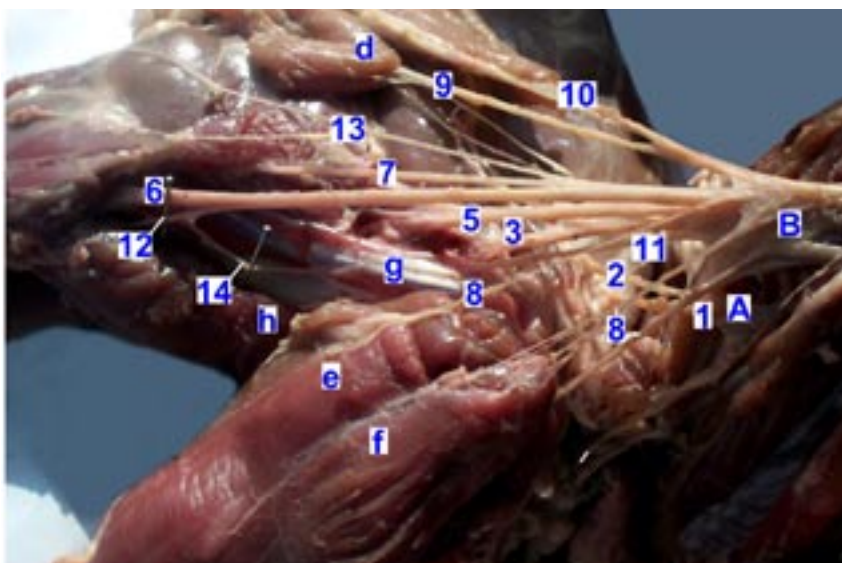
Figure 3. View of the nerves which spreaded to palmar aspect of the forelimb digitis

*al.*, 1995), from C5, C6 and C7 in Wervet monkey (Booth, 1991) and in Chacma baboon (Booth *et al.*, 1997), from C7 and C8 in dog (Miller *et al.*, 1964; Tipirdamaz and Erden, 1988; Dursun *et al.*, 1994), from C6 and C7 in cat (Getty, 1975; Aslan, 1994) or C7 and C8 (McClure *et al.*, 1973). In porcupine, this nerve differs from that of other species as it together with a branch of subscapular nerve, originated from caudal trunk.

Thoracodorsal nerve originates from C6 and C7 in rat (Green, 1968), C7 in rabbit (Yilmaz *et al.*, 1995), as a branch of radial nerve in Wervet monkey (Booth,

1991) and in Chacma baboon (Booth *et al.*, 1997) and from C7 and C8 (Miller *et al.*, 1964; Dursun *et al.*, 1994) or only C8 (Tipirdamaz and Erden, 1988) in dog, and C7 and C8 (Getty, 1975; Aslan, 1994) or only C7 (McClure *et al.*, 1973) in cat. Differing from these findings, in our study this nerve originated from caudal trunk as two separate branches together with radial and axillar nerves.

It is reported that radial nerve originated from C6, C7 and C8 in rat (Green, 1968), C7, C8 and T1 in rabbits (Aslan, 1994; Yilmaz *et al.*, 1995), C7, C8 and T1 in dogs (Getty, 1975; Tipirdamaz and Erden,



11 – branche supplying coracobrachialis muscle, 12 – musculocutaneous nerve, 13 – caudal cutaneous antebrachial nerve, 14 – branche which is bind to musculocutaneous nerve after leaving coracobrachial branche, d – pectoral ascendens muscle, e – pectoral transversus muscle, f – pectoral acendens muscle, g – corachobrahial muscle, h – biceps brachii muscle

Figure 4. Medial view of the humerus of the nerve branches in the porcupine

1988; Dursun *et al.*, 1994), C7 and C8 (McClure *et al.*, 1973) or C6, C7, C8 and T1 (Getty, 1975) in cat. It was different in porcupine and as in Wervet monkey (Booth, 1991) and in Chacma baboon (Booth *et al.*, 1997), radial nerve obtained branches from all nerves from C5 to T2. The origin of radial nerve was the same of those of other species. Cutaneous antebrachi lateral nerve separates from ramus superficialis, a branch of radial nerve, in equidea and ruminants (Dursun, 2000), and from ramus superficialis in dog (Tipirdamaz and Erden, 1988) differ from findings in porcupine.

Median nerve originates from C7, C8, T1 in rat (Green, 1968; Bertelli *et al.*, 1992), from all nerves from C5 to T2 in Wervet monkey (Booth, 1991) and in Chacma baboon (Booth *et al.*, 1997), C8, T1 and T2 (Miller *et al.*, 1964; Tipirdamaz and Erden, 1988) in dogs, from C7, C8, T1 and T2 in a kind kangal of dog (Dursun *et al.*, 1994), from C7, C8 and T1 (McClure *et al.*, 1973; Getty, 1975) in cat. In porcupine, it originates from caudal trunk as it is in Wervet monkey (Booth, 1991) and Chacma baboon (Booth *et al.*, 1997).

The ulnar nerve originated from C7, C8 and T1 in rat (Green, 1968; Bertelli *et al.*, 1992), T1 and T2 in rabbit (Yilmaz *et al.*, 1995), C8, T1 and T2 in Wervet monkey (Booth, 1991) and Chacma baboon (Booth *et al.*, 1997), C8, T1 and T2 in dog (Miller *et al.*, 1964; Tipirdamaz and Erden, 1988; Dursun *et al.*, 1994), and C8 and T1 in cat (Getty, 1975; McClure *et al.*, 1973). The present study determine that this nerve originated from caudal trunk in porcupine.

Cranial pectoral nerve originates from C7 and C8 in equidae, ruminant and carnivor (Dursun, 2000) and from C8, T1 and T2 as two branches one of which together with musculocutaneous nerve and the second one with cranial pectoral nerve and lateral thoracic nerve in dogs (Tipirdamaz and Erden, 1988). In porcupine it originated from caudal trunk as four branches, one together with lateral thoracic nerve and caudal pectoral nerve and other three separately.

Lateral thoracic nerve originates from C8, T1 and caudal pectoral nerve originated from C8, T1 and T2 in ruminant and equidea (Tecirlioglu, 1983). According to Dursun (2000), both of them originates from C8 and T1. In dog, they originated from C8, T1, T2 (Tipirdamaz and Erden, 1988; Dursun *et al.*, 1994). These two nerves originated from caudal trunk and caudal pectoral nerve as two separate branches in porcupine, according to the result of this study.

Musculocutaneous nerve originated from C5, C6 and C7 (Bertelli *et al.*, 1992) or C6 and C7 (Green, 1968) in rats, C5, C6 and C7 in Wervet monkey (Booth, 1991) and Chacma baboon (Booth *et al.*, 1997). In dog, this nerve together with cranial pectoral nerve originated from C7 (Dursun *et al.*, 1994). Tipirdamaz and Erden (1988) reported that it also receives a contribution from C6. In cat, it originates from C7 (McClure *et al.*, 1973) or C6 and C7 (Getty, 1975). In the present study, we observed that it originated from caudal trunk in porcupine. Ramus muscularis proximalis which separates from musculocutaneous nerve and courses to the coracobrachial muscle in dog (Miller *et al.*, 1964; Tipirdamaz and Erden, 1988; Dursun *et al.*, 1994) and cat (McClure *et al.*, 1973; Getty, 1975) showed a different pattern in porcupine, because it originated from caudal trunk together with cranial pectoral nerve in contrast to the previous species. Musculocutaneous nerve ends as cutaneous antebrachi medial nerve in equidea and ruminants (Tecirlioglu, 1983; Dursun, 2000) and dog (Tipirdamaz and Erden, 1988; Dursun *et al.*, 1994). In porcupine, we observed that in addition to this branch, it gave the digital dorsal commun I and II nerve which supplied the dorsal aspect of the fingers (Figure 2).

As a result, nerves originating from brachial plexus showed some significant differences in porcupine compared to these in rat, rabbit and other mammals. The nerve innervating coracobrachial muscle and brachial biceps muscle originated directly from plexus, and transversally joined musculocutaneous nerve after giving a branch to each muscle. After giving ramus muscularis distalis to brachial muscle and cutaneous antebrachii medial nerve to the medial aspect of antebrachii, musculocutaneous nerve continues and together with ramus superficialis of radial nerve and dorsal branch of ulnar nerve spreads to the dorsal of fingers and palmar branch of ulnar nerve and the last parts of median nerve supplied the palmar aspect of finger.

## REFERENCES

- Aslan K. (1994): The comparative macroanatomic investigation on the brachial plexus of the native cat (*Felis domestica*) and White New Zealand Rabbit (*Oryctolagus cuniculus*) (in Turkish). Istanbul Universitesi Veteriner Fakultesi Dergisi, 20, 197–208.
- Aydin A. (2003): Brachial plexus of the porcupine (*Hystrix cristata*). Vet. Med. – Czech, 48, 301–304.

- Bertelli J.A., Mira J.C., Gilbert A., Michot G.A., Legagneux J. (1992): Anatomical basis of rat brachial plexus reconstruction. *Surg. Radiol. Anat.*, 14, 85–86.
- Booth K.K. (1991): The brachial plexus in the vervet monkey (*Cercopithecus pygerythrus*). *J. Med. Primatol.*, 20, 23–28.
- Booth K.K., Baloyi F.M., Lukhele O.M. (1997): The brachial plexus in the chacma baboon (*Papio ursinus*). *J. Med. Primatol.*, 26, 196–203.
- Chiasson R.B. (1980): *Laboratory Anatomy of the White Rat*. W. C. Brown Company Publishers, USA.
- Cook M.J. (1965): *The Anatomy of the Laboratory Mouse*. Academic Press, London, New York.
- Demirsoy A. (1992): Rodentia. *Yasamin temel Kurallari*, Ankara, Meteksan Anonim Sirketi. 695–729.
- Dursun N. (2000): *The Anatomy of the Veterinary III*. Medisan Yayınevi, Ankara. 96–111.
- Dursun N., Tipirdamaz S., Gezici M. (1994): Macroanatomic investigations on the brachial plexus in Kangal dogs (in Turkish). *Selcuk Universitesi, Veteriner Bilimler Dergisi*, 10, 78–80.
- Getty R. (1975): *Sisson and Grossman's the Anatomy of the Domestic Animals*. 5th ed. W. B. Saunders Company, Philadelphia. 1700–1718.
- Green C.E. (1968): *Anatomy of the Rat*. Hafner Publishing Company, New York and London. 124–153.
- Kuru M. (1987): Rodentia. *Omurgali Hayvanlar, Erzurum, Atatürk Üniversitesi, Basım*. 551–564.
- McClure R.C., Dallman M.J., Garret P.G. (1973): *Cat Anatomy*. Lea and Febiger, Philadelphia. 66.
- Miller M., Christensen G., Evans H. (1964): *Anatomy of the Dog*. W. B. Saunders Company, Philadelphia. 578–589.
- Nomina Anatomica Veterinaria (1994): 4th ed. Copyright by the World Association of Veterinary Anatomists.
- Tecirlioglu S. (1983): *Comparative anatomy of the veterinary (Nerves system)*. Fak. Yay. Atatürk Üniversitesi, Basımevi. 389.
- Tipirdamaz S., Erden H. (1988): Macroanatomic investigations on the brachial plexus of the dogs (in Turkish). *Selcuk Universitesi, Veteriner Bilimler Dergisi*, 4, 317–332.
- Weichert C.K. (1970): *The Anatomy of the Choradates*. 4th ed. McGraw-Hill, London. 500–738.
- Yılmaz O., Yıldız H., Yıldız B., Serbest A. (1995): Morphological and morphometrical investigations on fascicle of ventral branches forming brachial plexus and nerves originating from plexus in White New Zealand Rabbits (*Oryctolagus cuniculus*) (in Turkish). *Yuzuncu Yil. Universitesi, Veteriner Fakültesi Dergisi*, 6, 67–75.

Received: 03–10–14

Accepted after corrections: 04–02–26

---

*Corresponding Author*

Dr. Ali Aydin, Firat University, Faculty of Veterinary Medicine, Department of Anatomy, 23119-Elazığ, Turkey  
Tel. +90 424 237 0000/6680, fax +90 424 238 8173, e-mail: aydina@firat.edu.tr

---