

A Comparative Analysis of Diagnostic Accuracy of Focused Assessment With Sonography for Trauma Performed by Emergency Medicine and Radiology Residents

Majid Zamani,¹ Babak Masoumi,¹ Mehrdad Esmailian,¹ Amin Habibi,² Mehdi Khazaei,³ and Mohammad Mohammadi Esfahani^{1,*}

¹Department of Emergency Medicine, Isfahan University of Medical Sciences, Isfahan, IR Iran

²Education Development Center, Isfahan University of Medical Sciences, Isfahan, IR Iran

³School of Medicine, Isfahan University of Medical Sciences, Isfahan, IR Iran

*Corresponding Author: Mohammad Mohammadi Esfahani, Department of Emergency Medicine, Isfahan University of Medical Sciences, Isfahan, IR Iran. Tel: +98-9133277881, Fax: +98-36684510, E-mail: Mohammadi5147@yahoo.com

Received 2014 July 28; Revised 2015 April 27; Accepted 2015 June 8.

Abstract

Background: Focused assessment with sonography in trauma (FAST) is a method for prompt detection of the abdominal free fluid in patients with abdominal trauma.

Objectives: This study was conducted to compare the diagnostic accuracy of FAST performed by emergency medicine residents (EMR) and radiology residents (RRs) in detecting peritoneal free fluids.

Patients and Methods: Patients triaged in the emergency department with blunt abdominal trauma, high energy trauma, and multiple traumas underwent a FAST examination by EMRs and RRs with the same techniques to obtain the standard views. Ultrasound findings for free fluid in peritoneal cavity for each patient (positive/negative) were compared with the results of computed tomography, operative exploration, or observation as the final outcome.

Results: A total of 138 patients were included in the final analysis. Good diagnostic agreement was noted between the results of FAST scans performed by EMRs and RRs ($\kappa = 0.701$, $P < 0.001$), also between the results of EMRs-performed FAST and the final outcome ($\kappa = 0.830$, $P < 0.0010$), and finally between the results of RRs-performed FAST and final outcome ($\kappa = 0.795$, $P < 0.001$). No significant differences were noted between EMRs- and RRs-performed FASTs regarding sensitivity (84.6% vs 84.6%), specificity (98.4% vs 97.6%), positive predictive value (84.6% vs 84.6%), and negative predictive value (98.4% vs 98.4%).

Conclusions: Trained EMRs like their fellow RRs have the ability to perform FAST scan with high diagnostic value in patients with blunt abdominal trauma.

Keywords: Comparative, Diagnostic, Sonography, Emergency Medicine, Radiology Residents

1. Background

Focused assessment with sonography in trauma (FAST) is a modality to rapidly detect free fluid (usually blood) in the peritoneal, pericardial, or pleural spaces in trauma patients (1). It can be performed in the emergency department (ED) to provide noteworthy information in a short span of time. Therefore, FAST exam is applied in blunt trauma algorithms as an initial evaluation procedure. It is performed immediately after the primary survey of the Advanced Trauma Life Support (ATLS) protocol and is the basis for immediate decisions for further evaluation and management of the patient (2).

Interest and experience with FAST grew among surgeons and emergency physicians during the early 1990s, when it was no longer exclusively performed by radiologists (3-5). In 2001, American college of emergency physicians (ACEP) published the first formal comprehensive

guidelines ultrasound use in emergency medicine that contained the application of FAST as a core application (6). In 2008, the ACEP offered recommendations for the training of FAST by emergency physicians (3).

As an ultrasound imaging method, FAST is an operator-dependent technique, i.e. the skill of the operator is critically important for correct diagnosis. Many studies have shown that trained nonradiologist physicians are capable of performing an expedient FAST as accurately as formally trained radiologists (7-9). Nonetheless, some radiologists believe that a high level of knowledge and experience is needed to perform an accurate and reliable FAST in trauma patients (10).

2. Objectives

The present study was conducted to compare the diag-

nostic accuracy of FAST performed by emergency medicine and radiology residents for the detection of peritoneal free fluid in trauma patients.

3. Patients and Methods

This prospective observational study was conducted between November 2012 and November 2013 in Al-Zahra educational hospital (Isfahan, Iran) of Isfahan university of medical sciences. The study protocol was approved by the ethics committee of the university.

Patients of any age or sex admitted to the emergency department (ED) of hospital for blunt abdominal trauma, high energy trauma (Box 1) (11), and multiple trauma were deemed eligible for participation in the study.

Box 1. Evidence of High-Energy Impact

Evidence
Falls
Adults: > 6.09 meter
Children: > 3.04 meter or 2 to 3 times the height of the child
High-risk auto crash
Extrusion: > 0.3 meter, occupant site: >0.45 meter, any site
Ejection (partial or complete) from automobile
Death in same passenger compartment
Vehicle telemetry data consistent with high risk of injury
Auto pedestrian/bicyclist thrown, run over, or with significant (> 32 km/h) impact
Motorcycle crash > 32 km/h

After arrival in ED and a primary trauma survey, FAST was carried out by previously trained EMRs. Simultaneously, other necessary measures were taken for the patient. Patients on whom performing FAST would potentially delay emergency procedures, those with penetrating abdominal trauma and preexisting peritoneal fluid, and pregnant women were excluded from the study.

The patients were evaluated in supine position with arms abducted slightly or above the head. All scans were done by the same ultrasound machine (DC-7, Mindray Medical Ltd., China) in ED, while a low frequency (5 - 2 MHz) curved array transducer was selected with a focused depth based on the patient's body. In pediatric patients, a higher-frequency linear array transducer was selected to produce sound waves with adequate depth penetration to obtain better resolution (12).

A typical FAST examination was performed to obtain the 4 standard views (subxiphoid (pericardial) 4-chamber view, right coronal and intercostal oblique view, left coronal and intercostal oblique view, and suprapubic (pelvic view) to examine 4 specific areas of the thoracoabdominal region (13).

History and physical examination findings were noted and FAST scan findings (negative or positive for abdominal free fluid) were collected and documented on a data

sheet for each case. Any amount of free fluid in any of the 3 windows (hepatorenal, splenorenal, suprapubic) was considered positive for abdominal free fluid (haemoperitoneum). Patients with pericardial effusion were excluded and managed separately. After FAST was completed by EMRs, the patients were transferred to radiology department and underwent FAST by radiology residents (second year radiology residents) using the same technique and machine as EMRs. All FAST scans were completed within 4 minutes. For the patients whose transfer to RD was dangerous or impossible and those who were hemodynamically unstable, the bedside FAST scan was down by EMRs and RRs. Ultrasound findings for each patient were compared with the results of computed tomography (reported by the attending radiologist), operative exploration, or observation.

For definitive imaging of the abdomen in positive or suspected reports of each resident group a CT scan of the abdomen and pelvis with intravenous contrast was performed. In addition, patients with negative FAST results were observed for 6 - 12 hours in the emergency department. Patients with negative FAST scan whose abdominal physical examination was suspicious, underwent CT scan of the abdomen and pelvis at the request of the senior EM resident or an attending emergency physician. Patients with positive FAST scan who were hemodynamically unstable and did not respond to 2 L IV fluid administration while no other source was found for the instability, underwent exploratory laparotomy without further imaging (14).

All statistical analyses were performed using the statistical package of social sciences (SPSS) version 19.0 (SPSS, Chicago, IL, USA). To evaluate the diagnostic agreement between the results of the two groups of residents and also between FAST results and final diagnostic method, kappa score analysis was run. Sensitivity, specificity, positive, and negative predictive values of FAST performed by EMRs and RRs were calculated and compared using Chi-square analysis. P value less than 0.05 was considered statistically significant

4. Results

One hundred and forty participants with a mean age of 28.5 ± 13.8 years (range 4 - 65 years) were included in this study. About 71% of patients were male. Sonography was performed on all of the patients.

Two patients expired and were excluded from the final analysis. Of remaining 138 patients, 17 patients had positive FAST scan by one or both resident groups. Five patients (with positive FAST scan from both groups) had moderate or greater amount of intraperitoneal free fluid in FAST and underwent operation without having other diagnostic modalities and laparotomy proved the presence of haemoperitoneum in all cases. In 6 patients with negative FAST, the abdominal examination was suspicious; therefore, CT scan was performed.

Finally, FAST scan findings were compared to the results

of surgical exploration in 5 patients (3.62%), to CT scan in 18 patients (13.04%), and to clinical observation in the remaining 115 patients (83.33%).

Good diagnostic agreement was noted between the results of FAST scans performed by EMRs and RRs ($\kappa = 0.701$, $P < 0.001$), also between the results of EMRs-performed FAST and the final outcome ($\kappa = 0.830$, $P < 0.0010$), and finally between the results of RRs-performed FAST and the final outcome ($\kappa = 0.795$, $P < 0.001$), (complete agreement would be equal to a κ of 1, and chance agreement would be equal to 0) (Table 1).

Sensitivity, specificity, positive, and negative predictive values of FAST scans done by EMRs and RRs are presented in Table 2. There were no differences in these parameters between FAST scans performed by EMRs and RRs (Figure 1).

Table 1. Agreement Between the Results of FAST Performed by Emergency Medicine Residents and Radiology Residents^{a,b}

EMRs Performed FAST	RRs Performed FAST		
	Positive	Negative	Total
Positive	11	3	14
Negative	5	121	126
Total	16	124	140

^aAbbreviations: EMRs, Emergency medicine residents; RRs, Radiology residents.

^bKappa = 0.701 and $P < 0.001$.

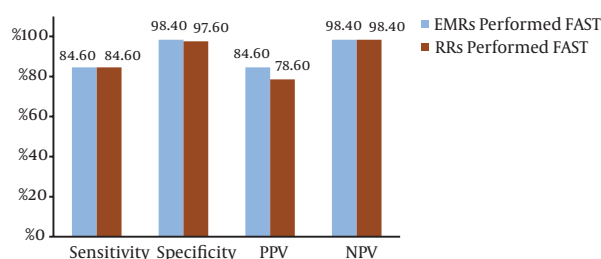
Table 2. Agreement Between the Results of FAST Performed by Two Groups of Residents and Final Outcome^{a,b}

Final outcome	EMRs Performed FAST		RRs Performed FAST	
	Positive	Negative	Positive	Negative
Positive	11	2	11	2
Negative	2	123	3	122
Total	13	125	14	124

^aAbbreviations: EMRs, Emergency medicine residents; RRs, Radiology residents.

^bBetween EMRs-performed fast and final outcome, Kappa = 0.830 and $P < 0.001$. between RRs-performed FAST and final outcome, Kappa = 0.830 and $P < 0.001$.

Figure 1. Sensitivity, Specificity, Positive Predictive Value (PPV) and Negative Predictive Value (NPV) of FAST Performed by Two Resident Groups (Chi-square)



EMRs, Emergency medicine residents; RRs, Radiology residents. P value in comparison of specificities = 0.651. P value in comparison of PPVs = 0.686.

5. Discussion

In this study, we compared the diagnostic value of FAST scan between RRs and EMRs. This investigation showed that ER-performed sonography had an acceptable diagnostic value in comparison to RR-performed FAST.

Rapid detection of intraperitoneal fluid in patients with blunt abdominal trauma to select an appropriate approach is highly critical in reducing mortality and improving the outcome. Diagnostic peritoneal lavage (DPL), CT imaging, and FAST are the main paraclinical modalities to evaluate patients with blunt abdominal trauma. CT scan is the gold standard and provides the evidence of bleeding plus detailed information of injured organ. It has a sensitivity of 88% and specificity of 98% (15). However, it is time consuming and inappropriate for unstable patients. DPL is sensitive in the detection of abdominal bleeding (16) but is invasive and time consuming and may bring about some complications to patients (17). FAST is a noninvasive rapid bedside method. Although it cannot replace CT scan, it is highly valuable in the initial evaluation of patients with abdominal trauma and could save the time and provide highly valuable information to make decisions about the further management of patients in ED (13). Therefore, it is very important for physicians working in ED to be able to do an accurate and reliable FAST.

Several previous studies have compared the accuracy of FAST performed by radiologists and nonradiologists. The results of these studies demonstrated a sensitivity of 52% - 100% and specificity of 96% - 99% for FAST performed by nonradiologists (18-20). Some studies have shown that the ability to detect haemoperitoneum using the FAST method is equally accurate if it is performed by nonradiologists (NR) and radiologists alike (9, 14). Our results are consistent with these studies. Buzzas et al. (10) compared the accuracy of FAST performed by surgery residents and radiologists. They reported a sensitivity of 73% and specificity of 97% for surgeon-performed FAST and sensitivity of 79% and specificity of 99% for radiologist-performed FAST. Bhoi et al. evaluated the accuracy of FAST done by nonradiologists and compared it to radiologists-performed FAST in the emergency department of a trauma center in India. Sensitivity values of FAST done by NR and RR were 100% and 95.6% and specificity was 97.5% in both groups (8).

The results of our study suggest that the accuracy of FAST performed by trained EMRs is comparable to RRs performed FAST. Some studies have specifically evaluated FAST performed by EMRs or emergency physicians. Brenchley et al. reported a sensitivity of 78% and specificity of 99% for FAST performed by UK emergency physicians (7). Ingeman et al. reported that FAST performed by emergency physicians had a sensitivity of 75%, a specificity of 96% and an accuracy of 91% (19). In our study, EMRs-performed FASTs had 84% sensitivity and 98% specificity. Sensitivity and specificity for RRs-performed FAST were

84% and 97%, respectively. Currently, FAST is being done by residents and specialists of radiology, emergency medicine, and surgery in Iran. Shojaee et al. evaluated the accuracy of FASTs performed by EMRs with respect to the detection of abdominal free fluid following blunt trauma and compared it to RRs performed FASTs. Both RRs- and ERs-performed FASTs had about 60% sensitivity and 99% specificity in comparison to the final outcome based on the findings of abdominal CT scans and clinical follow-up (21). Kakaie et al. evaluated the role of FAST in assessing injured people in Iran 2012 earthquake and reported that sensitivity of FAST did not change when it was performed by RRs, but its specificity increased (compared to EM and surgery residents) (22).

Therefore, the results of our study are comparable with previous studies conducted in Iran and other countries. All EMRs in hospitals affiliated to Isfahan university of medical sciences have substantial training in FAST as a part of residency training programs, including didactic sessions and practical examinations, each with at least 200 FAST examinations at the end of the first year of residency (according to the log book). It has been suggested by most investigators that sensitivity and specificity begin to plateau after 25 to 50 FAST exams (23-25), while some others have recommended 200 examinations (26). In addition, during the second year of residency training, they are required to complete 1 month training in an EM radiology rotation. Hence, it is no surprise that EMRs of this center provide accurate FAST exams.

There were some limitations in this study. First, EMRs were more involved with the patients and had more information about them which could affect their performance in FAST. Second, we could not perform CT scan as gold standard for all patients. And finally, the timing of FAST performed by each group of residents is different in this study. EMRs performed FAST just after patients' arrival to ED (after primary survey) and the patients were transferred to RD after the primary evaluations in the ED. Regarding the role of time in the fluid accumulation it could affect the result of FAST scan. Although the patients were transferred to radiology department as soon as possible to eliminate this effect, this limitation is inevitable when we decide to perform the FAST scan on the same subjects by both groups of residents. Further studies with separate subjects for each group of residents or doing serial FASTs on patients may practically eliminate the effect of time on the performance of each group.

We conclude that, trained EMRs have the ability to perform FAST scan with high diagnostic value (specificity, sensitivity, PPV, and NPV), similar to RRs for the detection of haemoperitoneum in patients with blunt abdominal trauma.

Footnotes

Authors' Contribution:All authors contributed equally in writing and editing the manuscript.

Funding/Support:This research was supported by the research department of Isfahan university of medical sciences.

References

- Sheng AY, Dalziel P, Liteplo AS, Fagenholz P, Noble VE. Focused assessment with sonography in trauma and abdominal computed tomography utilization in adult trauma patients: Trends over the last decade. *Emerg Med Int.* 2013;678380. doi: 10.1155/2013/678380. [PubMed: 24073336]
- Mohr NM, Moreno-Walton L, Mills AM, Brunett PH, Promes SB, et al. Generational influences in academic emergency medicine: Teaching and learning, mentoring, and technology (part I). *Acad Emerg Med.* 2011;18(2):190-9. doi: 10.1111/j.1553-2712.2010.00985.x. [PubMed: 21314779]
- American College of Emergency P. Emergency ultrasound guidelines. *Ann Emerg Med.* 2009;53(4):550-70. doi: 10.1016/j.annemergmed.2008.12.013. [PubMed: 19303521]
- Bode PJ, Niezen RA, van Vugt AB, Schipper J. Abdominal ultrasound as a reliable indicator for conclusive laparotomy in blunt abdominal trauma. *J Trauma.* 1993;34(1):27-31. [PubMed: 8437192]
- Tso P, Rodriguez A, Cooper C, Militello P, Mirvis S, Badellino MM, et al. Sonography in blunt abdominal trauma: A preliminary progress report. *J Trauma.* 1992;33(1):39-43. [PubMed: 1635104]
- American College of Emergency P. American College of Emergency Physicians. ACEP emergency ultrasound guidelines-2001. *Ann Emerg Med.* 2001;38(4):470-81. [PubMed: 11574810]
- Brenchley J, Walker A, Sloan JP, Hassan TB, Venables H. Evaluation of focussed assessment with sonography in trauma (FAST) by UK emergency physicians. *Emerg Med J.* 2006;23(6):446-8. doi: 10.1136/emj.2005.026864. [PubMed: 16714505]
- Bhoi S, Sinha TP, Ramchandani R, Kurrey L, Galwankar S. To determine the accuracy of focused assessment with sonography for trauma done by nonradiologists and its comparative analysis with radiologists in emergency department of a level 1 trauma center of India. *J Emerg Trauma Shock.* 2013;6(1):42-6. doi: 10.4103/0974-2700.106324. [PubMed: 23493113]
- Zożycki GS, Ochsner MG, Schmidt JA, Frankel HL, Davis TP, Wang D, et al. A prospective study of surgeon-performed ultrasound as the primary adjuvant modality for injured patient assessment. *J Trauma.* 1995;39(3):492-8. [PubMed: 7473914]
- Buzzas GR, Kern SJ, Smith RS, Harrison PB, Helmer SD, Reed JA. A comparison of sonographic examinations for trauma performed by surgeons and radiologists. *J Trauma.* 1998;44(4):604-6. [PubMed: 9555830]
- Gross E, Martel M. Multiple Trauma. In: Marx JA, Hochberger RS, Walls RM, Adams JG, Barsan WJ, Biros MH, editors. *Rosen's emergency medicine: concepts and clinical practice.* Philadelphia: MOSBY Elsevier; 2010. pp. 2435-251.
- Bahner D, Blaiwas M, Cohen HL, Fox JC, Hoffenberg S, Kendall J, et al. AIUM practice guideline for the performance of the focused assessment with sonography for trauma (FAST) examination. *J Ultrasound Med.* 2008;27(2):313-8. [PubMed: 18204028]
- Patel NY, Riherd JM. Focused assessment with sonography for trauma: methods, accuracy, and indications. *Surg Clin North Am.* 2011;91(1):195-207. doi: 10.1016/j.suc.2010.10.008. [PubMed: 21184909]
- Isenhour JL, Marx JA. Abdominal Trauma. In: Marx JA, Hochberger RS, Walls RM, Adams JG, Barsan WJ, Biros MH, editors. *Rosen's emergency medicine: Concepts and clinical practice.* Philadelphia: MOSBY Elsevier; 2010. pp. 414-35.
- Catre MG. Diagnostic peritoneal lavage versus abdominal computed tomography in blunt abdominal trauma: A review of prospective studies. *Can J Surg.* 1995;38(2):117-22. [PubMed: 7728665]
- Nagy KK, Roberts RR, Joseph KT, Smith RF, An GC, Bokhari F, et al. Experience with over 2500 diagnostic peritoneal lavages. *Injury.* 2000;31(7):479-82. [PubMed: 10908739]
- Kirkpatrick AW. Clinician-performed focused sonography for the resuscitation of trauma. *Crit Care Med.* 2007;35(5 Suppl):S162-72. doi: 10.1097/01.CCM.0000260627.97284.5D. [PubMed: 17446775]

18. Brooks A, Davies B, Smethhurst M, Connolly J. Prospective evaluation of non-radiologist performed emergency abdominal ultrasound for haemoperitoneum. *Emerg Med J*. 2004;**21**(5):e5. doi: 10.1136/emj.2003.006932. [PubMed: 1533573]
19. Ingeman JE, Plewa MC, Okasinski RE, King RW, Knotts FB. Emergency physician use of ultrasonography in blunt abdominal trauma. *Acad Emerg Med*. 1996;**3**(10):931-7. [PubMed: 8891039]
20. Fox JC, Boysen M, Gharahbaghian L, Cusick S, Ahmed SS, Anderson CL, et al. Test characteristics of focused assessment of sonography for trauma for clinically significant abdominal free fluid in pediatric blunt abdominal trauma. *Acad Emerg Med*. 2011;**18**(5):477-82. doi: 10.1111/j.1553-2712.2011.01071.x. [PubMed: 21569167]
21. Shojaee M, Faridaalae G, Sabzghabaei A, Safari S, Mansoorifar H, Arhamidolatabadi A, et al. Sonographic Detection of Abdominal Free Fluid: Emergency Residents vs Radiology Residents. *Trauma Mon*. 2013;**17**(4):377-9. doi: 10.5812/traumamon.5476. [PubMed: 24350131]
22. Kakaie F, Zarrintan S, Rikhtegar R, Yaghoubi AR. Iranian 2012 earthquake: the importance of Focused Assessment with Sonography for Trauma (FAST) in assessing a huge mass of injured people. *Emerg Radiol*. 2013;**20**(4):307-8. doi: 10.1007/s10140-013-1123-y. [PubMed: 23558508]
23. Gracias VH, Frankel HL, Gupta R, Malcynski J, Gandhi R, Collazzo L, et al. Defining the learning curve for the Focused Abdominal Sonogram for Trauma (FAST) examination: implications for credentialing. *Am Surg*. 2001;**67**(4):364-8. [PubMed: 11308006]
24. Shackford SR, Rogers FB, Osler TM, Trabulsy ME, Clauss DW, Vane DW. Focused abdominal sonogram for trauma: the learning curve of nonradiologist clinicians in detecting hemoperitoneum. *J Trauma*. 1999;**46**(4):553-62. [PubMed: 10217217]
25. Thomas B, Falcone RE, Vasquez D, Santanello S, Townsend M, Hockenberry S, et al. Ultrasound evaluation of blunt abdominal trauma: program implementation, initial experience, and learning curve. *J Trauma*. 1997;**42**(3):384-8. [PubMed: 9095104]
26. Scalea TM, Rodriguez A, Chiu WC, Brenneman FD, Fallon WF, Kato K, et al. Focused Assessment with Sonography for Trauma (FAST): results from an international consensus conference. *J Trauma*. 1999;**46**(3):466-72. [PubMed: 10088853]