

# **Foreign Body Reaction to Hyaluronic Acid (Restylane®): An Adverse Outcome of Lip Augmentation**

Paul C. Edwards<sup>1</sup> M.Sc., D.D.S., John E. Fantasia<sup>2</sup> DDS, and Robert Iovino<sup>3</sup> DDS.

<sup>1</sup>Assistant Professor, Department of General Dentistry, and Director, Surgical Oral Pathology Service, Creighton University School of Dentistry, Omaha, NE,

<sup>2</sup>Chief, Division of Oral Pathology, Department of Dental Medicine, Long Island Jewish Medical Center, New Hyde Park, NY, and

<sup>3</sup>Private Practice, Oral and Maxillofacial Surgery, Southampton, NY.

**Keywords:** foreign body reaction, granulomatous, lip augmentation, hyaluronic acid, Restylane®.

Address reprint requests to:

Dr. Paul C. Edwards

Assistant Professor, Department of General Dentistry,

Director, Surgical Oral Pathology Service,

Creighton University School of Dentistry,

2500 California Plaza,

Omaha, NE 68178

Tel: (402)-280-5025

Fax: (402)-280-5094

---

Author's accepted manuscript; final version published as:

Edwards PC, Fantasia JE, Iovino R. Foreign body reaction to hyaluronic acid (Restylane): an adverse outcome of lip augmentation. J Oral Maxillofac Surg. 2006 Aug;64(8):1296-9.

E-mail: pedwards@creighton.edu



Author's accepted manuscript; final version published as:

Edwards PC, Fantasia JE, Iovino R. Foreign body reaction to hyaluronic acid (Restylane): an adverse outcome of lip augmentation. *J Oral Maxillofac Surg.* 2006 Aug;64(8):1296-9.

## **Abstract**

Non-animal source hyaluronic acid (Restylane®) is a relatively new redefining dermal filler that is being employed with increasing frequency in the fields of dermatology and cosmetic/facial plastic surgery.

We report a case of a 74-year-old woman who presented with a firm submucosal nodule of the lower lip, which clinically was thought to represent a benign neoplasm. An excisional biopsy revealed the presence of multiple cyst-like vacuolated areas surrounded by granulomatous tissue composed predominantly of histiocytes and foamy macrophages, consistent with a foreign body reaction. Subsequent to the pathology findings, the patient acknowledged that she had received injections of Restylane® to the lips approximately 6 months before discovering the nodule. She had not mentioned this to her dentist or oral and maxillofacial surgeon to whom she had been referred because she believed that these two events were not related.

Although hyaluronic acid-based dermal fillers reportedly have a low incidence of long term side effects, clinicians should be aware of the possible development of foreign body reactions to these injectable agents.

## **Introduction**

A substantial amount of research has been directed towards the development of a biocompatible material with prolonged clinical longevity for use as an esthetic facial soft tissue augmentation agent. Some of these skin fillers include autologous

fat, bovine collagen, as well as autologous and allogeneic human collagen. Until recently, bovine collagen has been regarded as the “gold standard” in facial soft tissue augmentation. However, bovine collagen has a number of significant limitations, including the development of delayed hypersensitivity reactions in approximately 3% of patients<sup>1</sup>. As a result, double skin testing is recommended prior to treatment with bovine collagen<sup>2</sup>.

Hyaluronic acid-based temporary dermal fillers are being employed with increasing frequency for the treatment of facial skin lines and for lip augmentation procedures. These include Restylane® (Q-Medical Corporation, Uppsala, Sweden), a cross-linked hyaluronic acid injectable filler produced from bacteria by microbiologic engineering techniques<sup>3</sup>, and Hylaform® (Biomatrix Inc., Ridgefield, NJ), a hyaluronic acid extract derived from rooster combs.

Hyaluronic acid, a glycoaminoglycan consisting of repeating units D-glucuronic acid and N-acetyl-D-glucosamine, is a major component of the extracellular matrix of the dermis. In contrast to collagen, the chemical structure of hyaluronic acid is reportedly identical across species<sup>4</sup>. Therefore, the risk of immunogenicity to these products is believed to be low. However, these products do contain trace amounts of hyaluronin-associated protein and, in the case of Restylane®, bacterial antigens<sup>5</sup>. Moreover, the cross-linking process may introduce some immunogenic potential.

### **Case Presentation**

A 74-year-old woman presented with a firm, submucosal nodule of the lower lip measuring approximately 1.5cm in diameter. Clinically, this was thought to represent a

benign neoplasm. An excisional biopsy was performed under local anesthesia. The excised mass measured 1.2 x 1.2 x 0.8cm. Histologic examination revealed mucosa overlying connective tissue containing multiple vacuolated cyst-like areas (Figure 1). These cyst-like structures were surrounded by a granulomatous foreign body tissue reaction composed predominantly of histiocytes and foamy macrophages (Figure 2). On further questioning, the patient acknowledged that she had received injections of Restylane® to the lips by a dermatologist approximately 6 months before the development of the nodule. She had not mentioned this to her dentist or oral surgeon because she believed that these two events were not related. The patient denied having any prior cosmetic procedures to the face or lips besides the Restylane® injections.

On follow-up the surgical site had fully healed, and no further soft tissue nodules or swellings were noted.

## **Discussion**

The incidence of long term adverse reactions secondary to the injection of hyaluronic acid skin fillers is low. Short duration local injection site reactions, consisting of swelling, pain, tenderness and bruising are seen in the vast majority of patients treated with injectable hyaluronic acid derivatives<sup>2</sup>. In the same study, delayed onset reactions, primarily redness which resolved without treatment within 3 months, were noted in 8% of patients treated with Restylane®.

A review<sup>6</sup> of all reports of adverse reactions to Restylane® submitted to the manufacturer in 1999 and 2000 estimated one adverse event for every 650 to 1800 patients treated. These consisted primarily of localized hypersensitivity reactions and

injection site inflammation. There were two cases of injection site necrosis, as well as “rare reports of localized granulomatous reactions, bacterial infections, as well as acneiform and cystic lesions”<sup>6</sup>.

A retrospective study<sup>5</sup> of an estimated 4300 patients injected with Restylane® documented a 0.6% incidence of hypersensitivity reactions, equally divided between immediate and delayed reactions.

In a prospective randomized study of 38 individuals treated with Restylane® alone or Restylane® with Botulinum toxin A<sup>3</sup>, one subject in the combined Restylane®/ Botulinum toxin A group developed two episodes of delayed erythema, swelling and discomfort at the injection site at 4 and 11 months. A review of 709 patients<sup>1</sup> treated with either Hylaform or Restylane® for smoothing of nasolabial and glabellar lines, lip augmentation and correction of atrophic facial scars noted that slightly less than 0.5% of patients developed delayed skin reactions. The delayed skin reactions, which were first noticed between 6 to 8 weeks after injection, were of varying severity and manifested as induration, erythema and tenderness at the injection sites. One patient developed a sterile abscess of the nasolabial region. Time to complete resolution varied from 6 to 24 weeks. Three patients were treated with intralesional injections of triamcinolone. Subsequent intradermal skin testing performed on these patients was positive in 4 of 5 patients tested<sup>1</sup>.

A number of anecdotal reports of adverse reactions following dermal infiltration with hyaluronic acid-based fillers have been published. Shafir and Amir<sup>7</sup> described a patient who developed multiple sterile abscesses following injection of both lips and the nasolabial folds with Restylane®. A single report of a patient developing a 1x1 cm

ulcer of the glabellar region following injection with Restylane® has also been described<sup>8</sup>. The authors ascribed this reaction to embolization of the dorsal nasal artery by the injected hyaluronic acid gel. Low<sup>9</sup> described a case of venous occlusion of the upper lip with a resulting varix that persisted for 6 years following injection with Restylane®. Lupton and Alster<sup>10</sup> reported a case of a woman who developed multiple erythematous papulocystic nodules following injection of an unspecified modified hyaluronic acid gel. Toy and Frank<sup>11</sup> presented 2 case reports of women who developed granulomatous infections following injections of an unlicensed hyaluronic acid derivative (Hyacell) imported from South America. Both women were injected by the same practitioner, who was practicing medicine without a license in New York City. This individual was ultimately tied to a cluster of *Mycobacterium abscessus* infections, presumably related to injections with tainted hyaluronic acid<sup>11</sup>.

Histologic findings associated with adverse reactions to hyaluronic acid dermal injections have only been described in a few cases. In the previously described study by Carruthers and Carruthers<sup>3</sup>, histologic examination performed on one patient treated with Restylane® revealed a moderate lymphocytic and plasma cell infiltrate in the mid to lower dermis. No foreign material or foreign body giant cells were noted. Alcian blue staining for hyaluronic acid was negative. Fernandez-Acenero and colleagues<sup>12</sup> biopsied a nodule of the upper lip in a patient who received injections of Restylane® 2 months prior. A giant cell granulomatous foreign body reaction surrounding pools of Alcian blue positive amorphous material was noted. Soparkar et al<sup>13</sup> performed an incisional biopsy on a 65-year-old female patient who developed multiple plaque-like elevations of the periorbital region 5 years after undergoing

cosmetic treatment with Restylane®. Histologic examination revealed the presence of multiple cyst-like spaces, some of which contained alcian blue positive material, with a surrounding fibrotic reaction. Interestingly, they reported resolution of the dermal elevations following local infiltration of hyaluronidase. Follow-up histologic examination was not available. Raulin and colleagues<sup>14</sup> performed an intracutaneous test on a 53 year-old woman who developed a granulomatous-like lesion after injection of Hylaform for correction of perioral wrinkles. A biopsy taken 30 days later from the intracutaneous test site revealed the presence of a foreign body granuloma as well as the presence of mucin-like basophilic material presumed to be hylaform. Rongioletti et al<sup>15</sup> performed a biopsy on a 72-year-old woman who developed induration of the skin after receiving injections of Restylane®. The biopsy specimen revealed a foreign body granulomatous reaction encircling clear spaces of variable size, reminiscent of the histologic pattern seen in our patient. Alcian blue positive material was identified in the sclerotic stroma, but not in the clear vacuolated areas. Due to the histologic resemblance of the biopsied specimen to a silicone foreign body reaction, infrared spectrophotometry was performed to rule out the possibility of adulteration of the injected filler with silicone. Micheels<sup>16</sup> reported biopsy findings on four patients who experienced delayed reactions following cosmetic treatment with hyaluronic acid derivatives. Three biopsies from areas treated with Hylaform all exhibited foreign body-type giant cell reactions. Of the two areas injected with Restylane®, one showed a strong foreign body-type giant cell reaction, similar to the pattern noted following Hylaform injection. The other Restylane® injection site revealed mild chronic inflammation. Honig and colleagues<sup>17</sup> reported a foreign body-

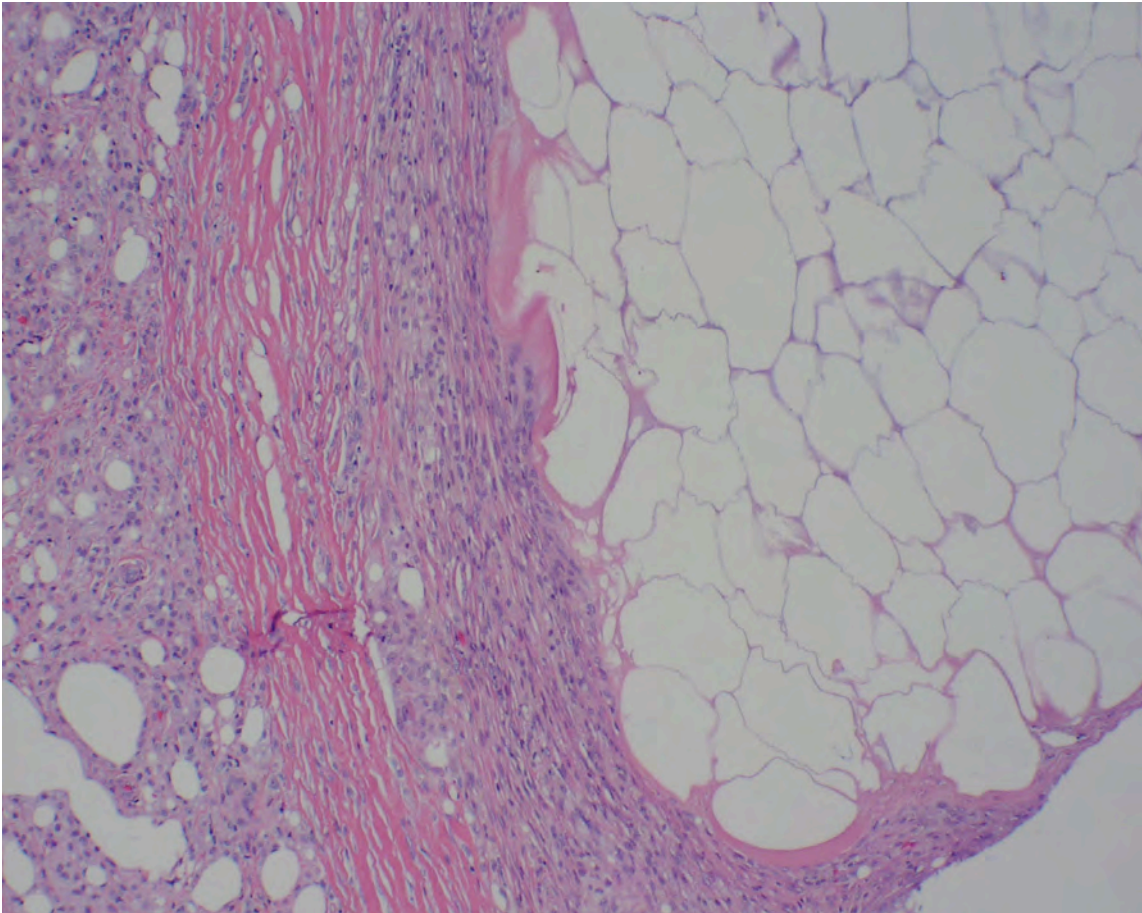


type giant cell reaction developing in a woman who received injections of hyaluronic acid in the nasolabial fold for the correction of facial lines. The most comprehensive histopathologic assessment of orofacial foreign body granulomas following injection of a number of different cosmetic fillers was reported by Lombardi et al<sup>18</sup>. However, none of the biopsied lesions were from patients treated with hyaluronic acid-derived fillers.

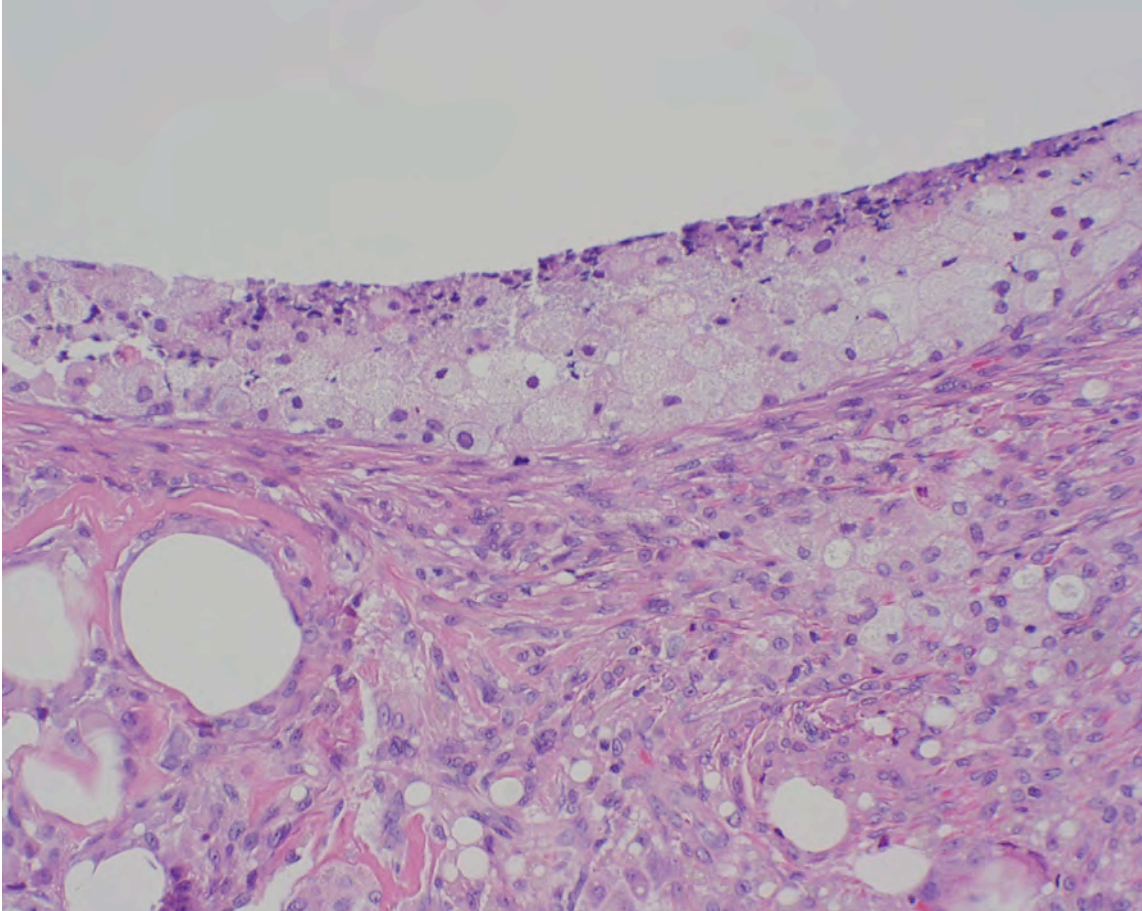
### **Conclusion**

Although hyaluronic acid-based dermal fillers reportedly have a low incidence of long term side effects, clinicians should be aware of the possible development of foreign body reactions to these injectable agents. When presented with a patient with a nodular lesion of the lips or facial region, the possibility that the patient may have undergone previous cosmetic procedures to the area should be included in the differential diagnosis.

**Figure 1: Low Power View of Biopsy Specimen from Lower Lip.** Multiple vacuolated cyst-like areas of different size are evident. These are surrounded by fibrotic connective tissue and a histiocytic tissue reaction. (Hematoxylin and eosin, original magnification 10x).



**Figure 2: High Power View of Biopsy Specimen from Lower Lip.** Fibrotic tissue and histiocytes surround the variable sized, vacuolated cyst-like areas. Abundant histiocytes are evident. (Hematoxylin and eosin, original magnification 40x).



## **References**

---

- <sup>1</sup> Lowe NJ, Maxwell CA, Lowe PL, Duick MG, Shah K. Hyaluronic acid skin fillers: adverse reactions and skin testing. *J Am Acad Dermatol.* 2001;45:930-3.
- <sup>2</sup> Narins RS, Brandt F, Leyden J, Lorenc P, Rubin M, Smith S. A randomized, double-blind, multicenter comparison of the efficacy and tolerability of Restylane versus Zyplast for the correction of nasolabial folds. *Dermatol Surg.* 2003; 29:588-95.
- <sup>3</sup> Carruthers J, Carruthers A. A prospective, randomized, parallel group study analyzing the effect of BTX-A (Botox) and nonanimal sourced hyaluronic acid (NASHA, Restylane) in combination compared with NASHA (Restylane) alone in severe glabellar rhytides in adult female subjects: treatment of severe glabellar rhytides with a hyaluronic acid derivative compared with the derivative and BTX-A. *Dermatol-Surg.* 2003;29:802-9.
- <sup>4</sup> Richter AW, Ryde EM, Zetterstrom EO. Nonimmunogenicity of a purified sodium hyaluronate preparation in man. *Int Arch Allergy Appl Immunol.* 1988; 59:45-8.
- <sup>5</sup> Andre P. Evaluation of the safety of a non-animal stabilized hyaluronic acid (NASHA- Q-Medical, Sweden) in European countries: a retrospective study from 1997 to 2001. *J Eur Acad Dermatol Venereol.* 2004;18:422-5.

- 
- <sup>6</sup> Friedman PM, Mafong EA, Kauvar AN, Geronemus RG. Safety data of injectable nonanimal stabilized hyaluronic acid gel for soft tissue augmentation. *Dermatol Surg.* 2002;28:491-4.
- <sup>7</sup> Raphael S, Amir A. Long-term complications of facial injections with Restylane (injectable hyaluronic acid). *Plast Reconst Surg.* 2000;106:121-6.
- <sup>8</sup> Schanz S, Schippert W, Ulmer A, Rassner G, Fierlbeck G. Arterial embolization caused by injection of hyaluronic acid (Restylane). *Brit J Dermatol.* 2002;146:920-32.
- <sup>9</sup> Lowe NJ. Re: arterial embolization caused by injection of hyaluronic acid (Restylane). *Brit J Dermatol.* 2003;148:379-80.
- <sup>10</sup> Lupton JR, Alster TS. Cutaneous hypersensitivity reaction to injectable hyaluronic acid gel. *Dermatol Surg.* 2000;26:135-7.
- <sup>11</sup> Toy BR, Frank PJ. Outbreak of Mycobacterium abscessus infection after soft tissue augmentation. *Dermatol Surg.* 2003;29:971-3.
- <sup>12</sup> Fernandez-Acenero MJ, Zamora E, Borbujo J. Granulomatous foreign body reaction against hyaluronic acid: report of a case after lip augmentation. *Dermatol Surg.* 2003;29:1225-6.
- <sup>13</sup> Soparkar CN, Patrinely JR, Tschen J. Erasing Restylane. *Ophthal Plast Reconstr Surg.* 2004;20:317-8.
- <sup>14</sup> Raulin C, Greve B, Hartschuh W, Soegding K. Exudative granulomatous reaction to hyaluronic acid (Hylaform). *Contact Dermatitis.* 2000;43:178-9.

---

<sup>15</sup> Rongioletti F, Cattarini G, Sottofattori E, Rebora A. Granulomatous reaction after intradermal injections of hyaluronic acid gel. *Arch dermatol.* 2003;139:815-6.

<sup>16</sup> Micheels P. Human anti-hyaluronic acid antibodies: is it possible? *Dermatol Surg.* 2001;27:185-91.

<sup>17</sup> Honig JF, Brink U, Korabiowska M. Severe granulomatous allergic tissue reaction after hyaluronic acid injection in the treatment of facial lines and its surgical correction. *J Craniofac Surg.* 2003;14:197-200.

<sup>18</sup> Lombardi T, Samson J, Plantier F, Husson C, Kuffer R. Orofacial granulomas after injection of cosmetic fillers. Histopathologic and clinical study of 11 cases. *J Oral Pathol Med.* 2004;33:115-20.