

Surgical Approaches to the Mandible

Jie Long MD, PhD

Department of OMS,
College of West China Stomatology,
Sichuan University, Chengdu



S

Safe (nerves&vessels)

E

Good Exposure

O

Easy Operation

A

Asthetics



Extraoral

- Atrophic, edentulous mandible
- Condylar/subcondylar fractures
- Comminuted fractures
- Skin laceration

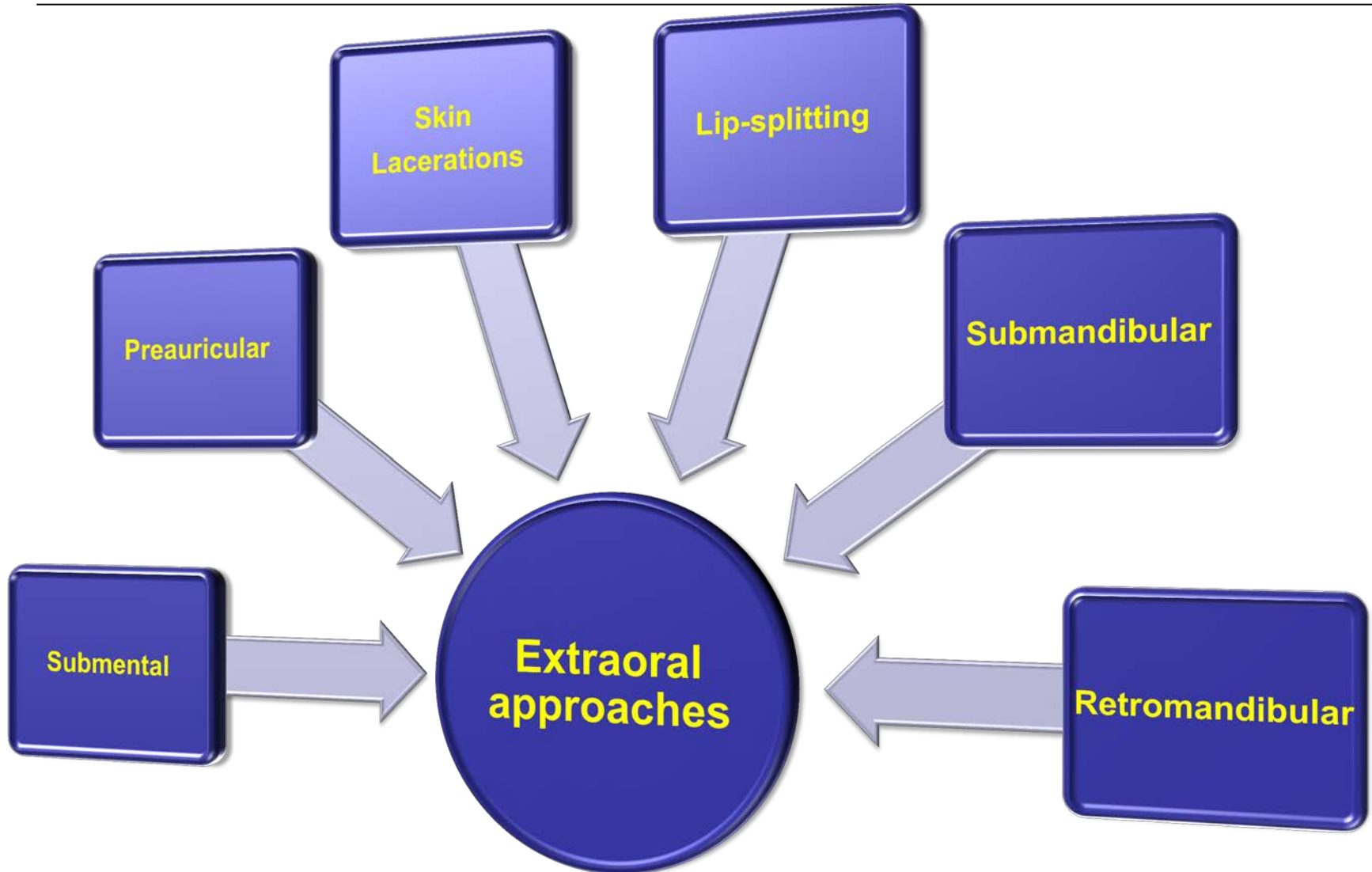
Intraoral

- Fracture without serious displacement
- Symphyseal, Parasymphyseal
- Body, angle fractures

Endoscope

- Condylar fractures
- Subcondylar fractures
- ramus fractures

Extraoral approach to mandible Chinese CMF

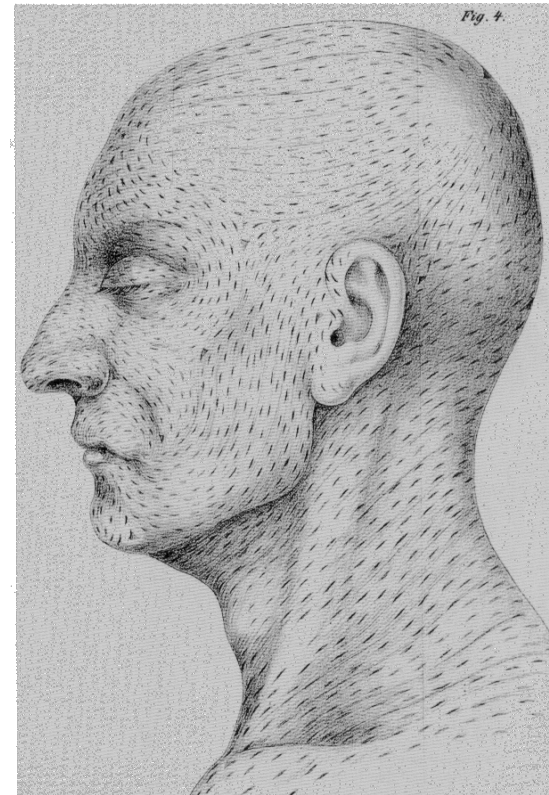


Langer's line:

static lines of maximal skin tension

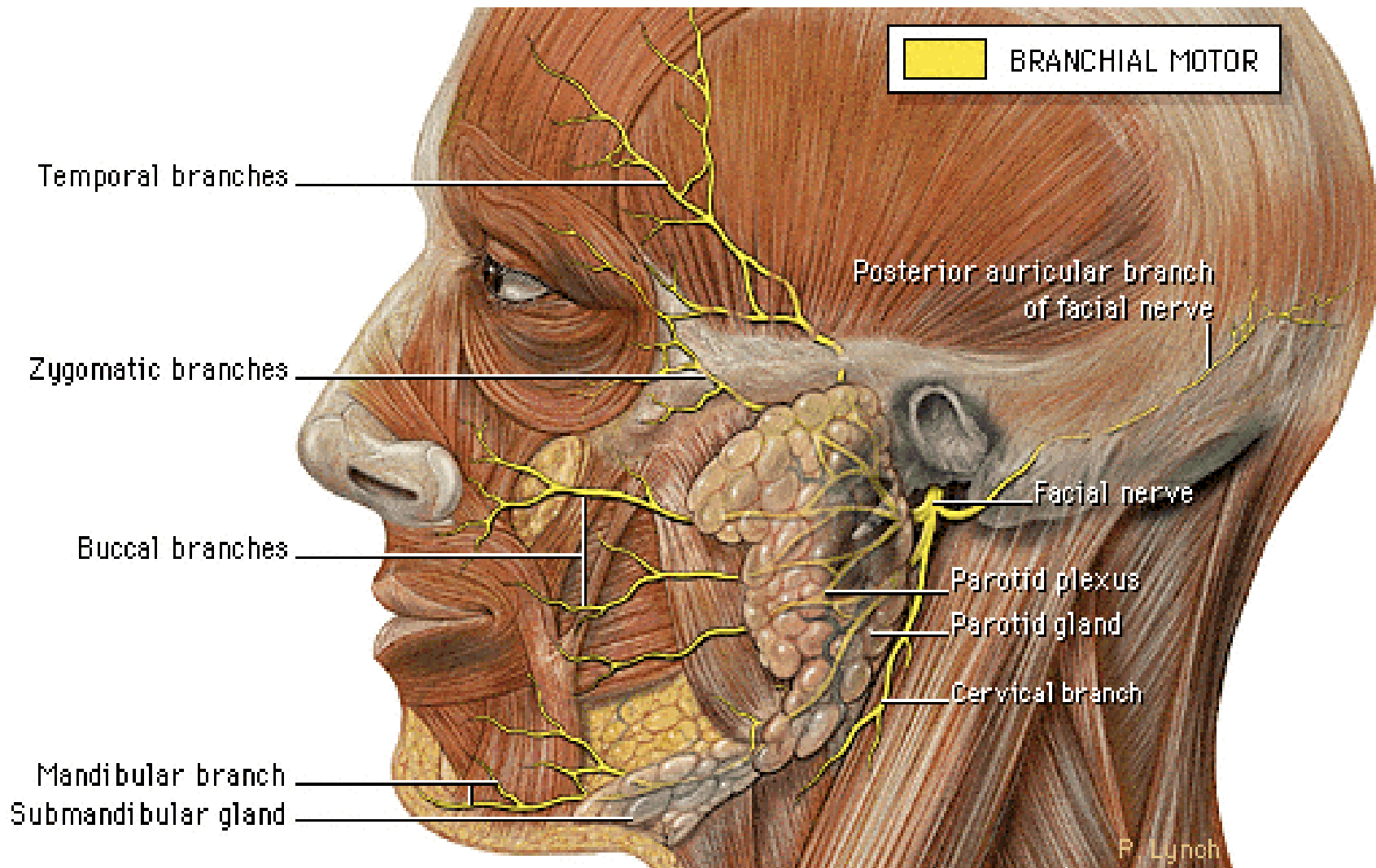
Extraoral incision:

Incision follow the direction of Langer's lines to obtain the best postoperative scars



Langer's lines, 1861

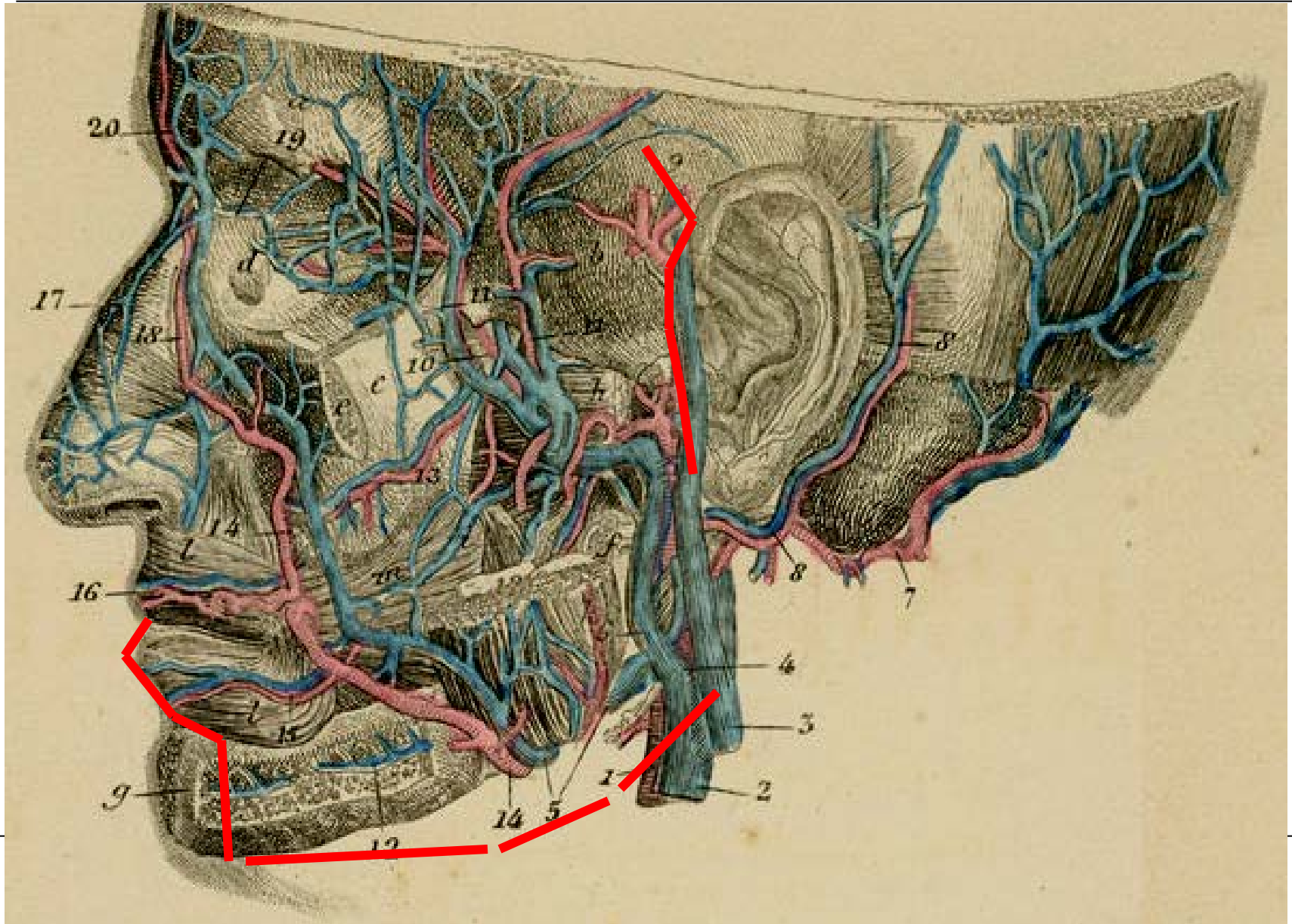
Anatomy: Nerves



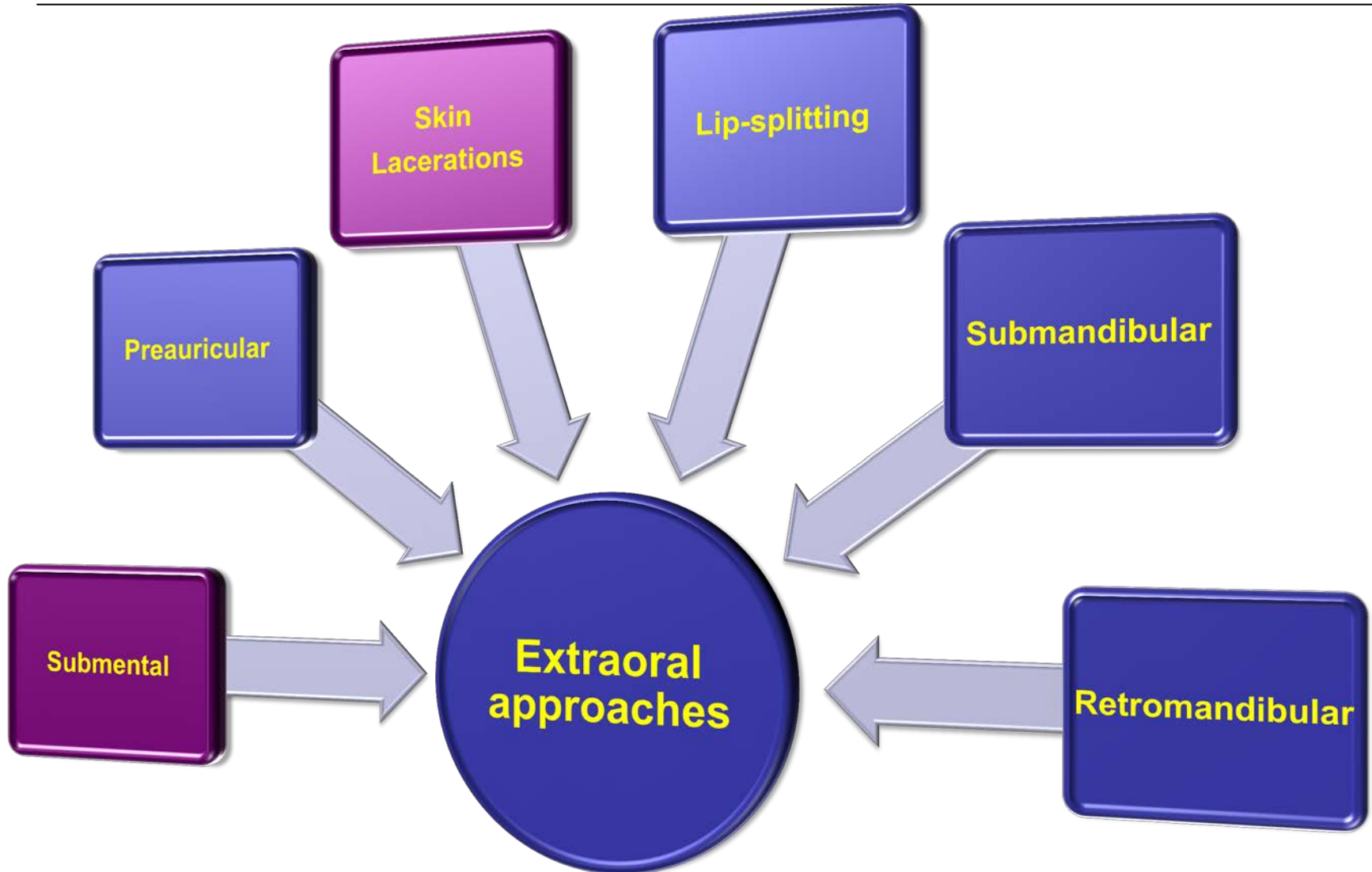
Anatomy: Arteries and Vein



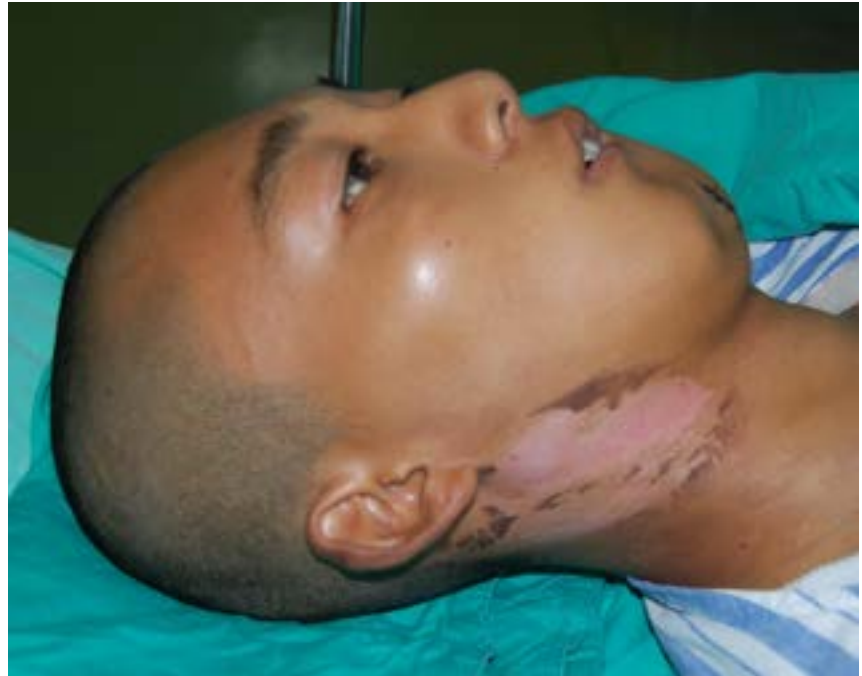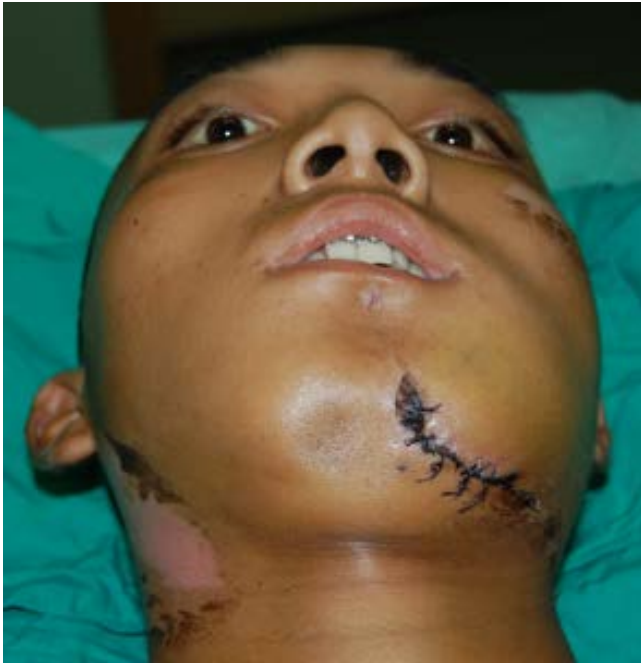Chinese CMF

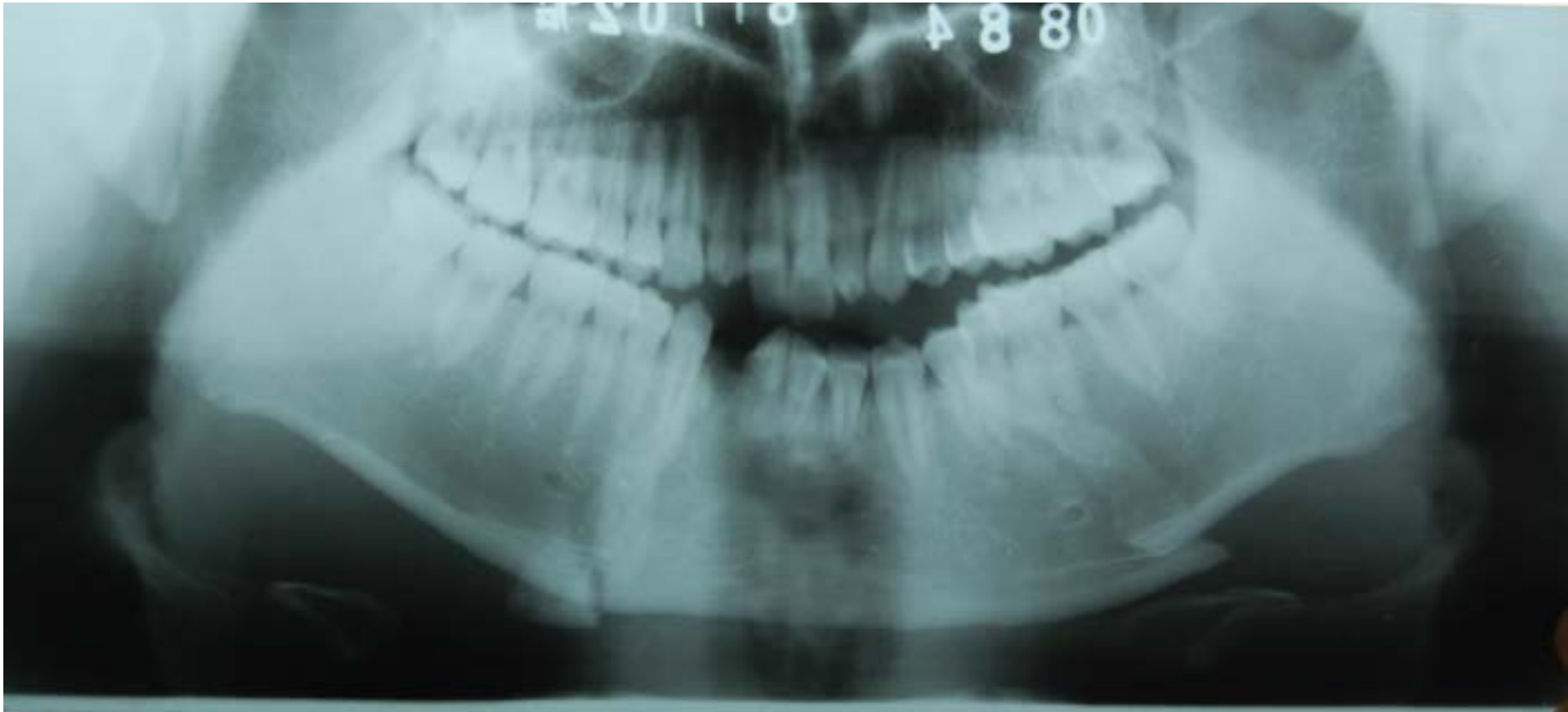

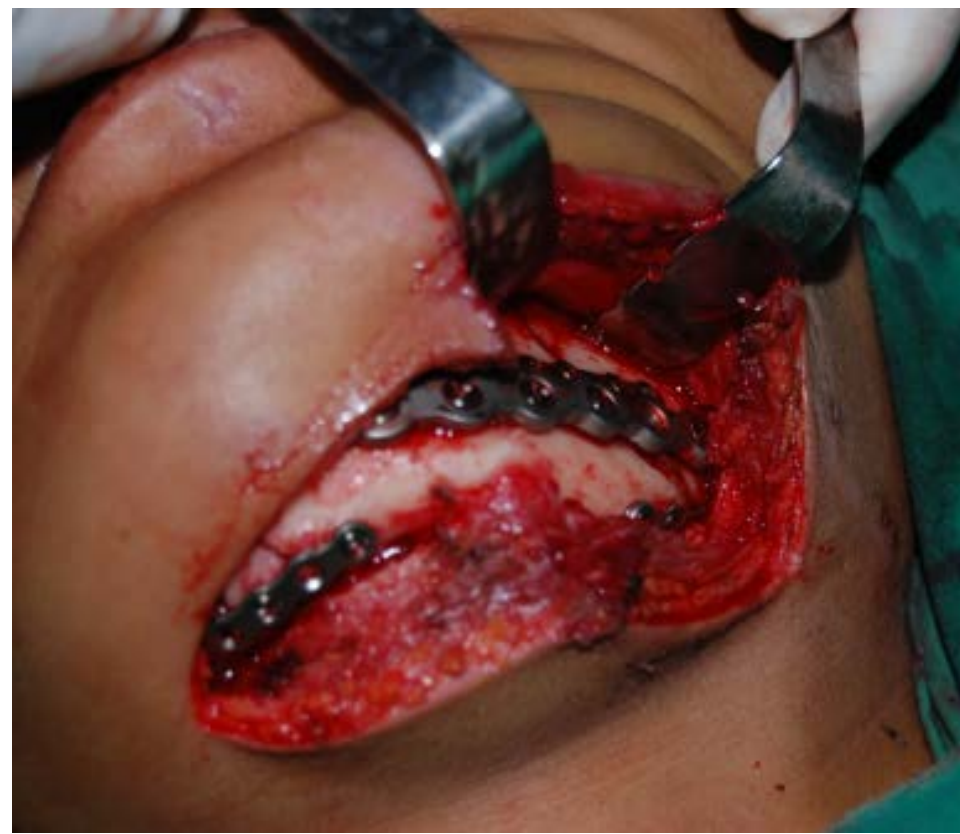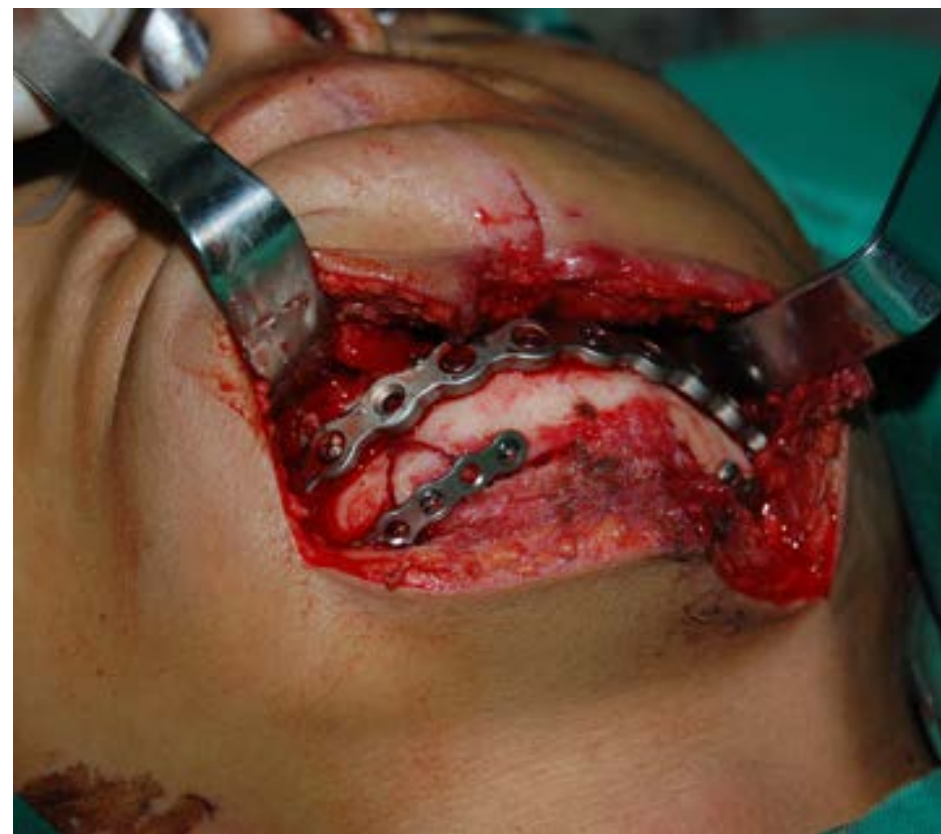Extraoral approach to mandible Chinese CMF

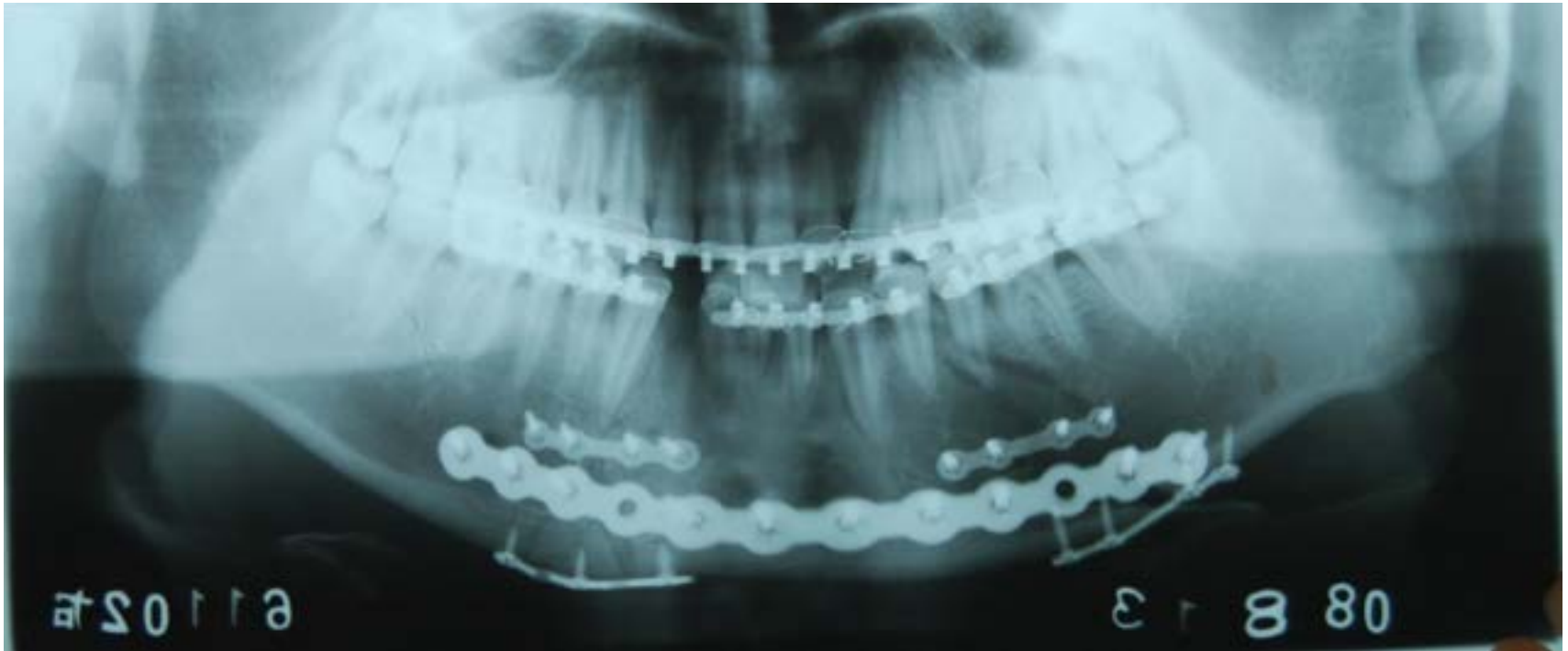

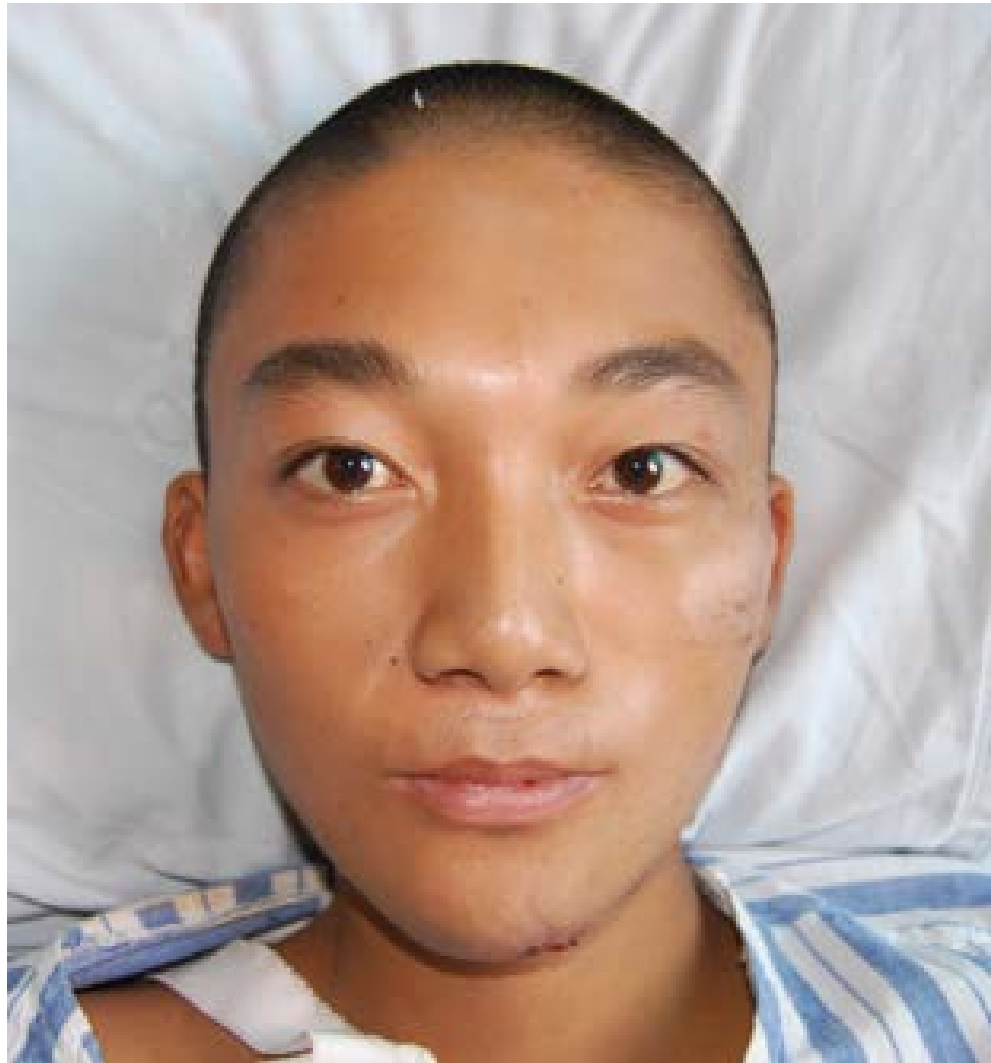- Parasymphyseal/Symphyseal fractures
 - Skin lacerations
 - Serious Dislocation of fragments
 - Comminuted fractures
 - defected fractures
-



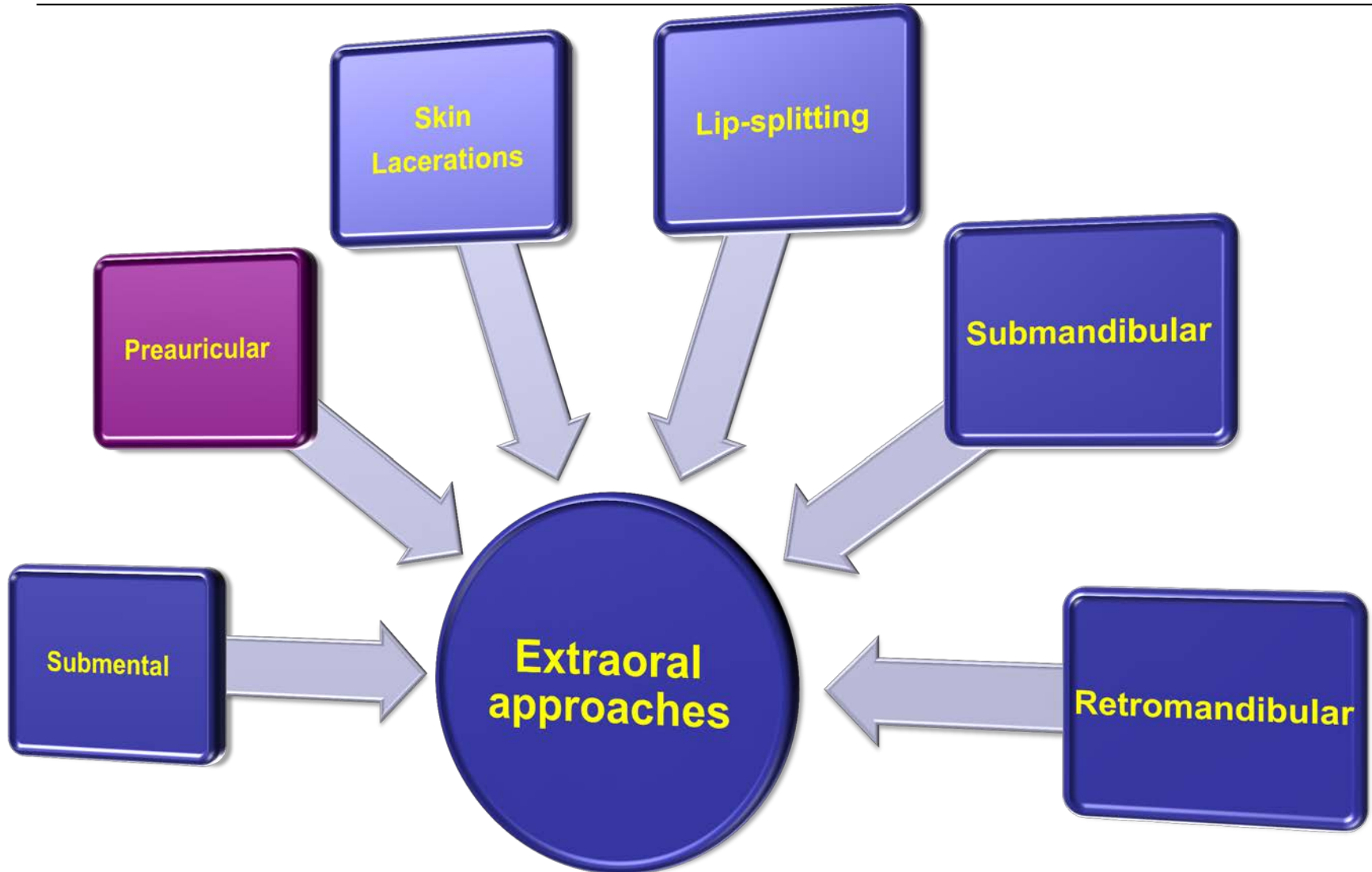


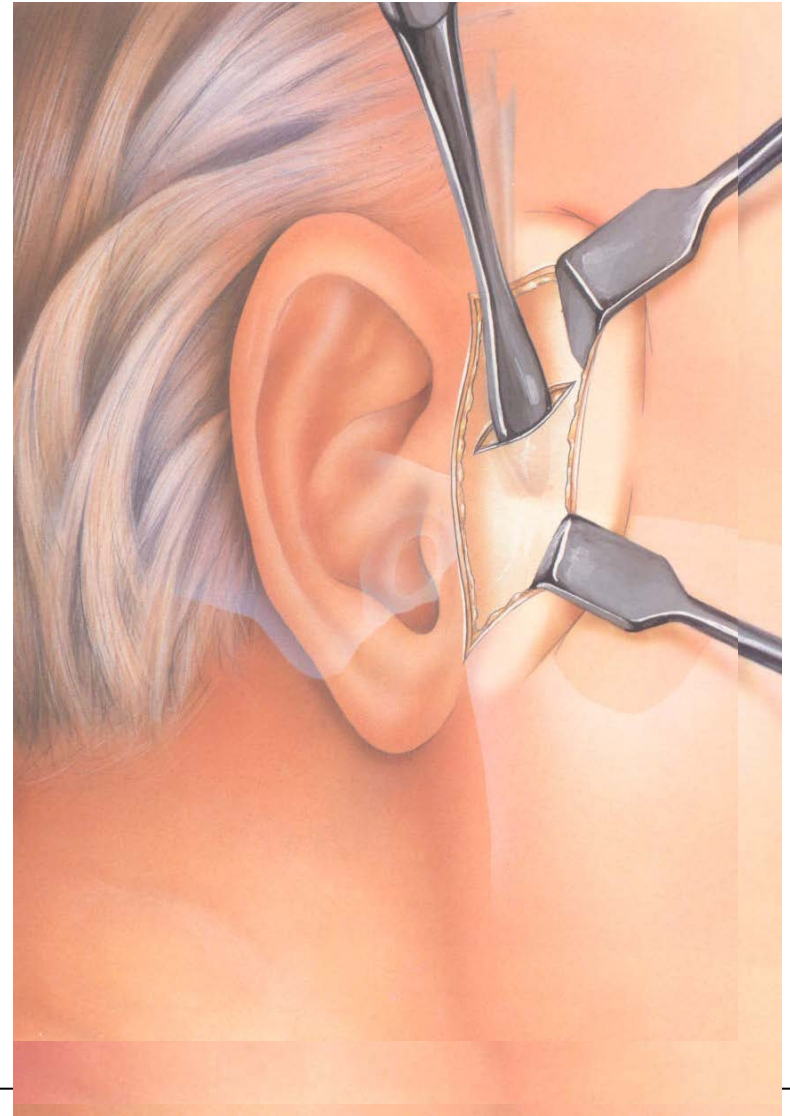
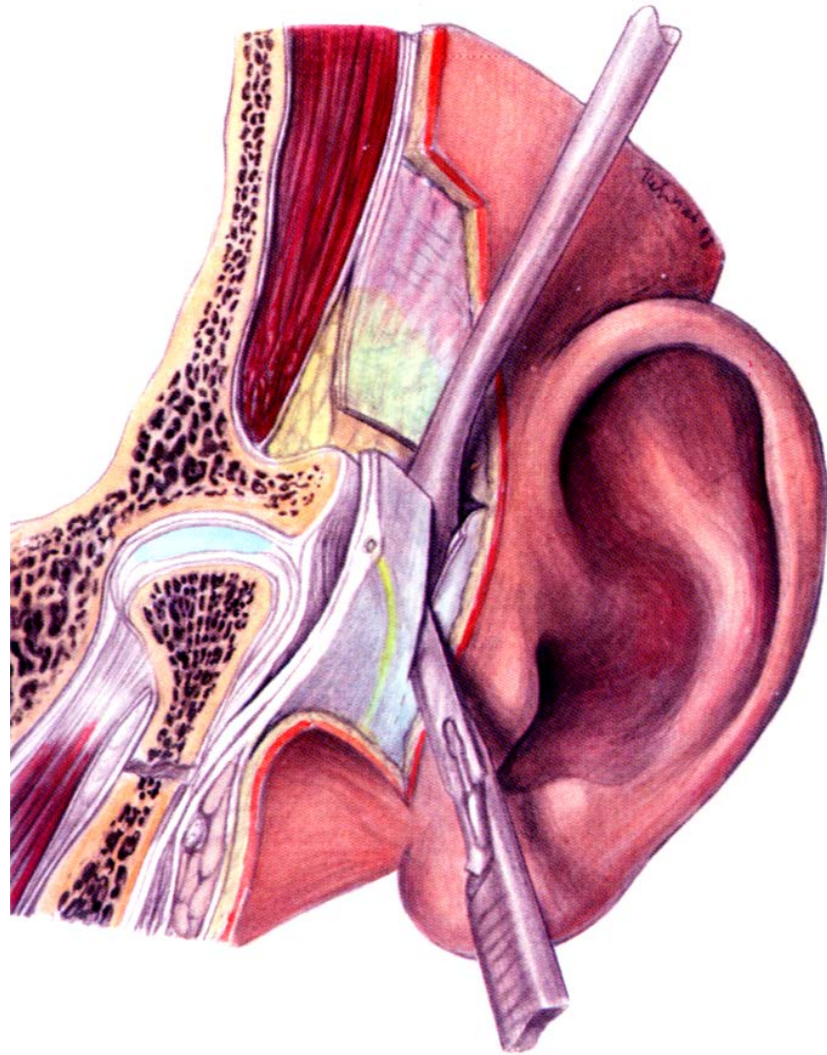


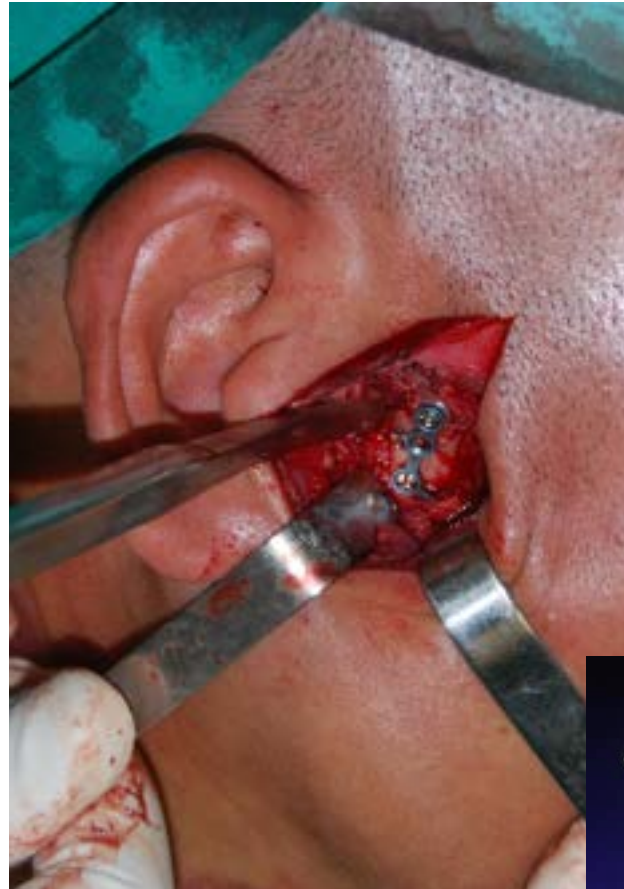
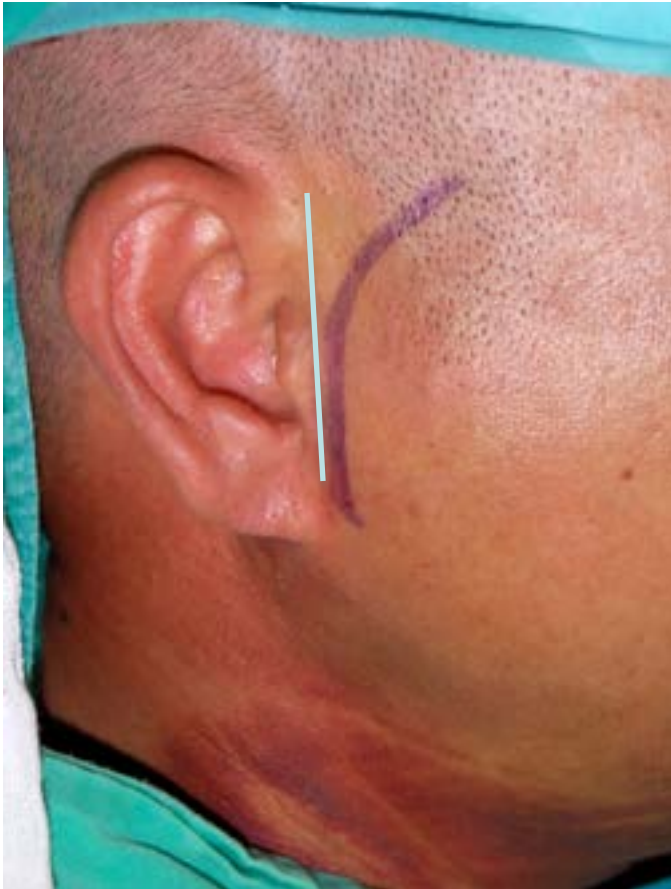


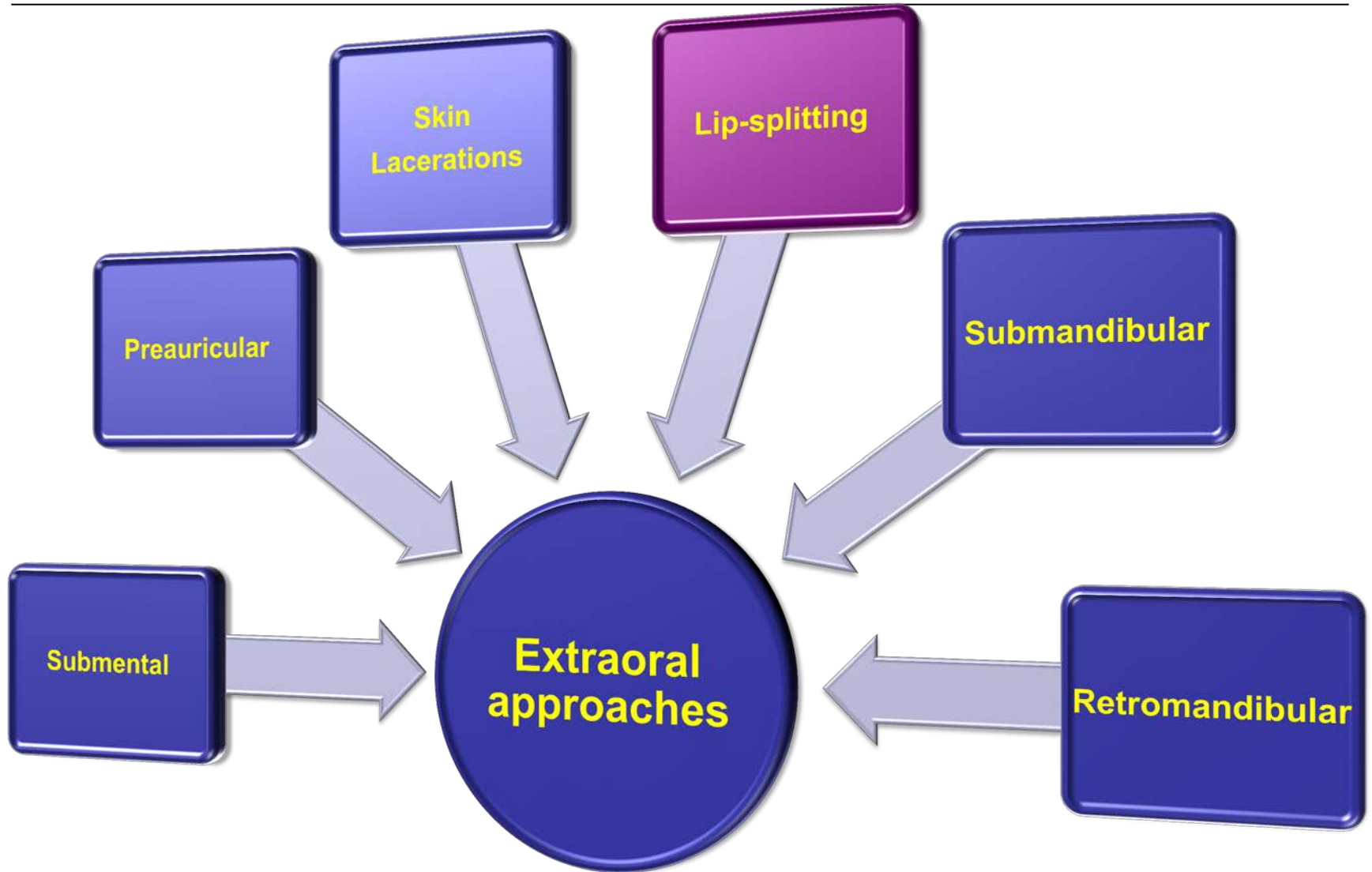
Extraoral approach to mandible Chinese CMF

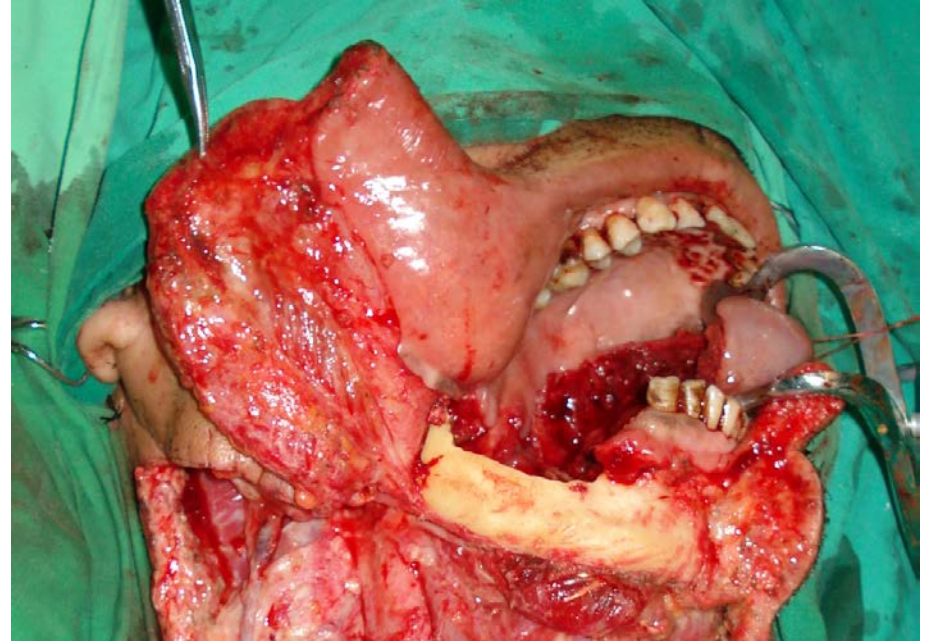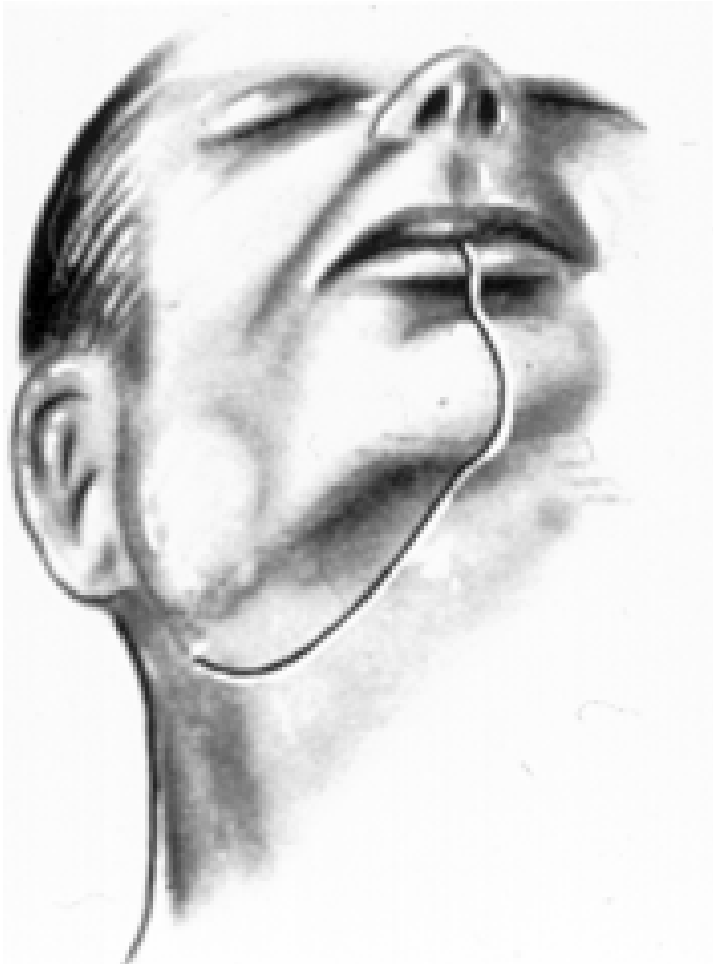




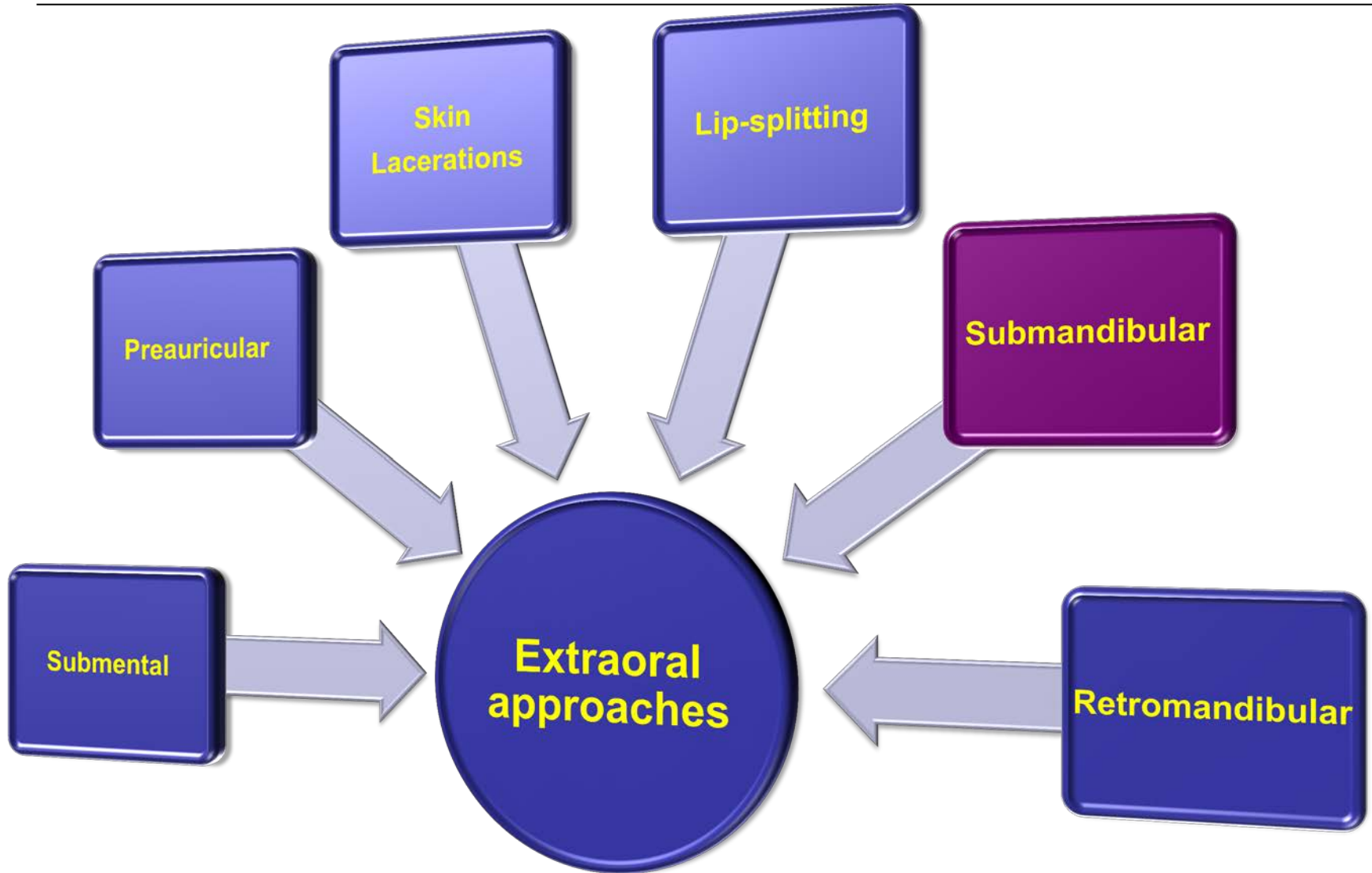


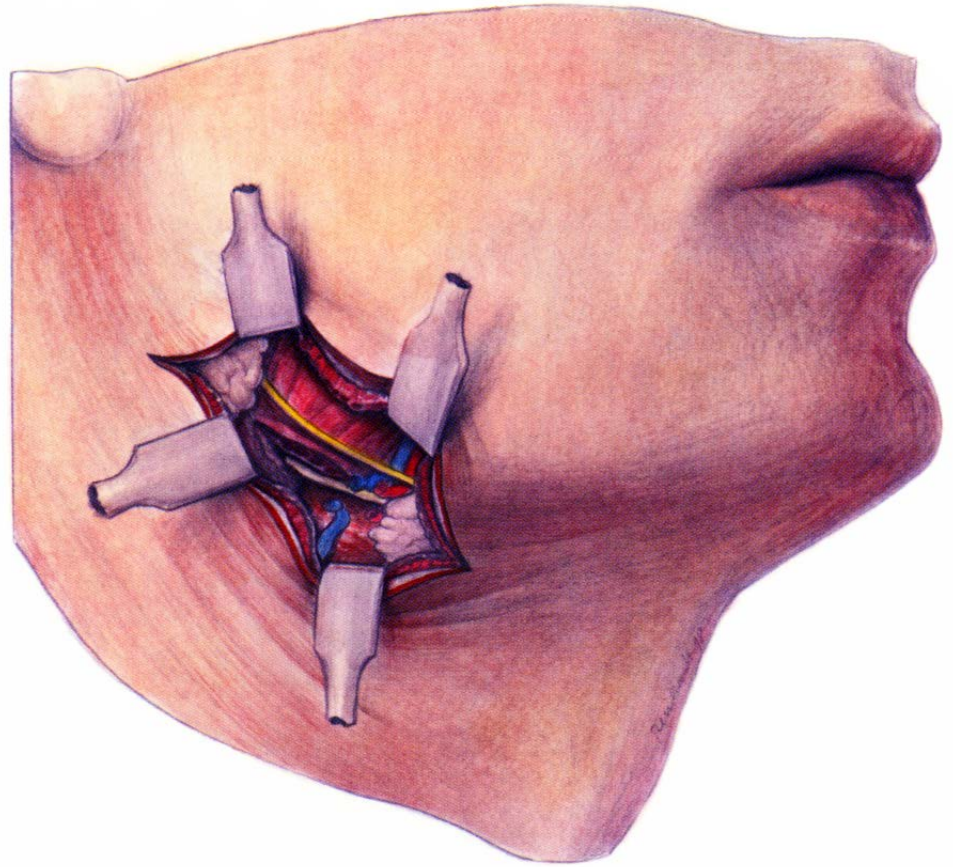
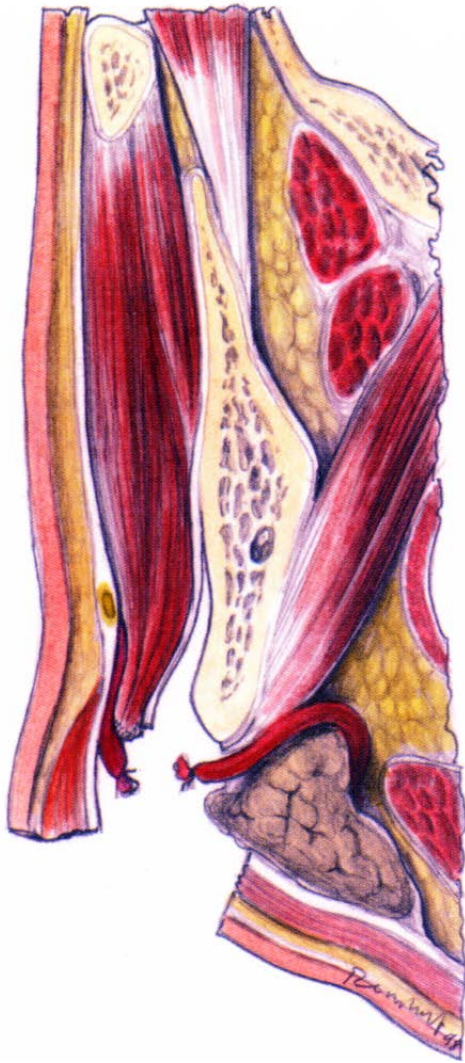
Extraoral approach to mandible Chinese CMF



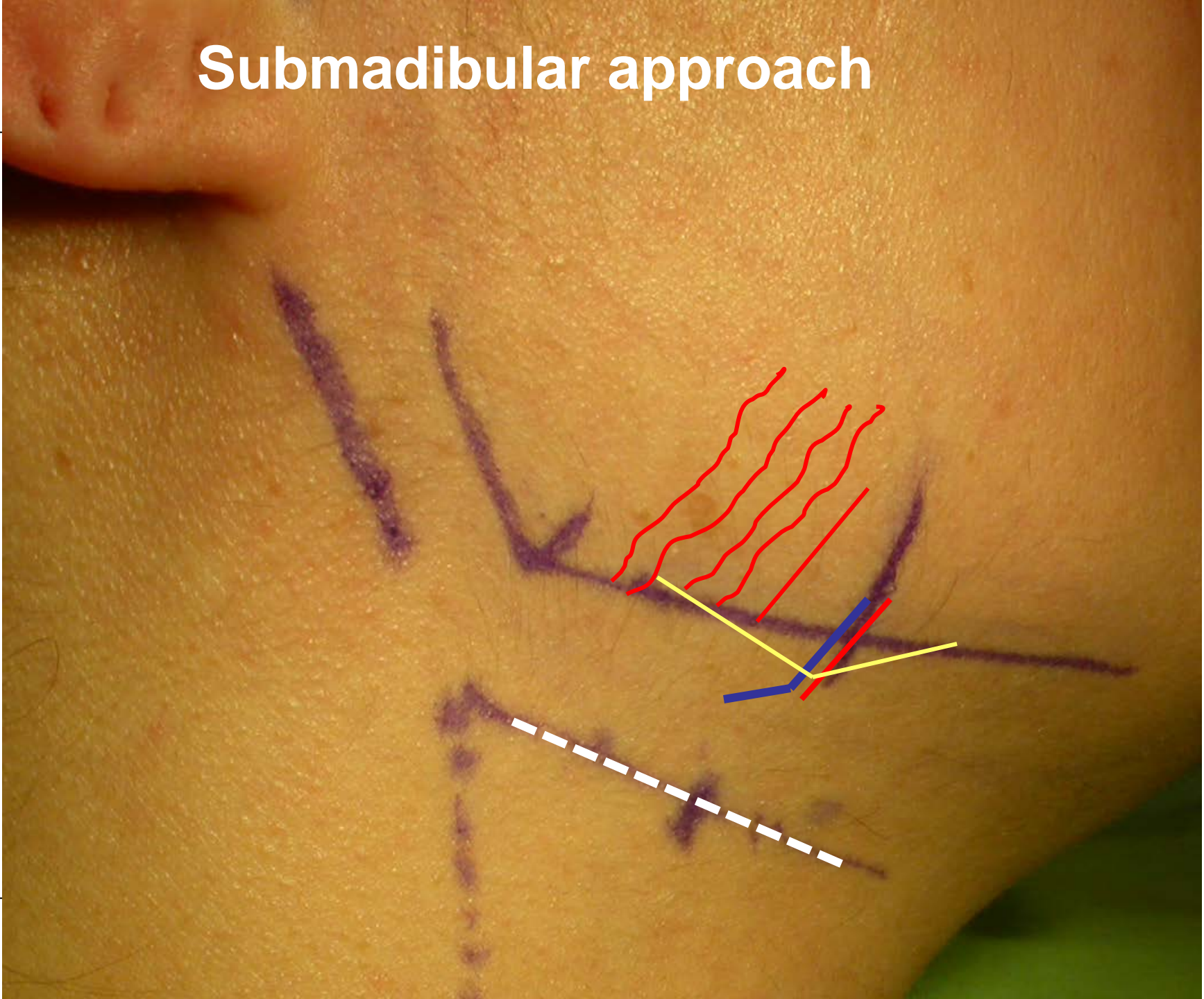


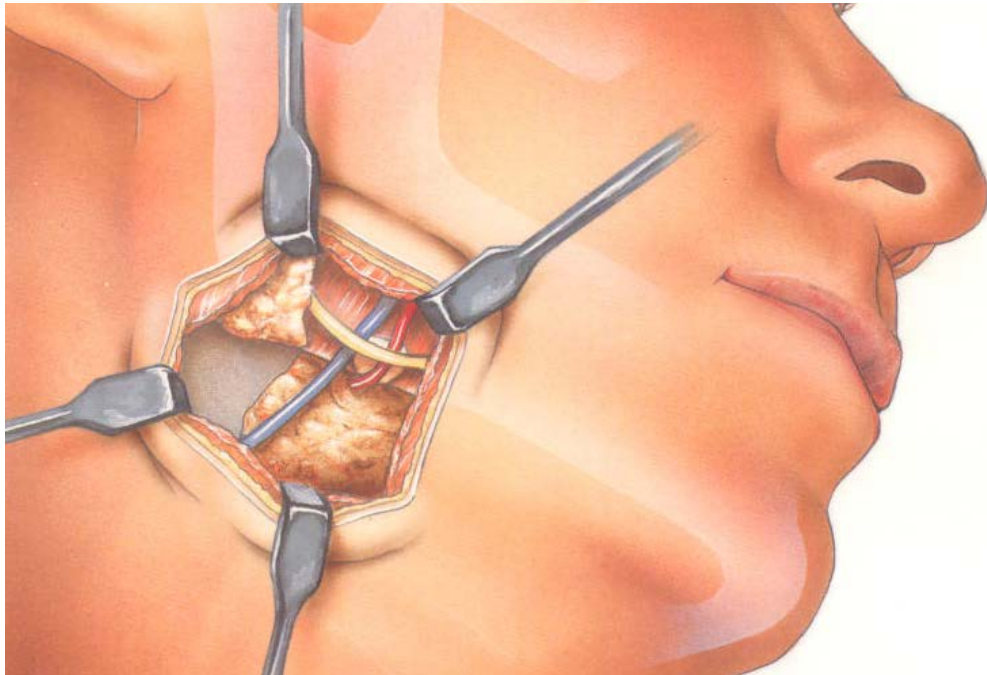
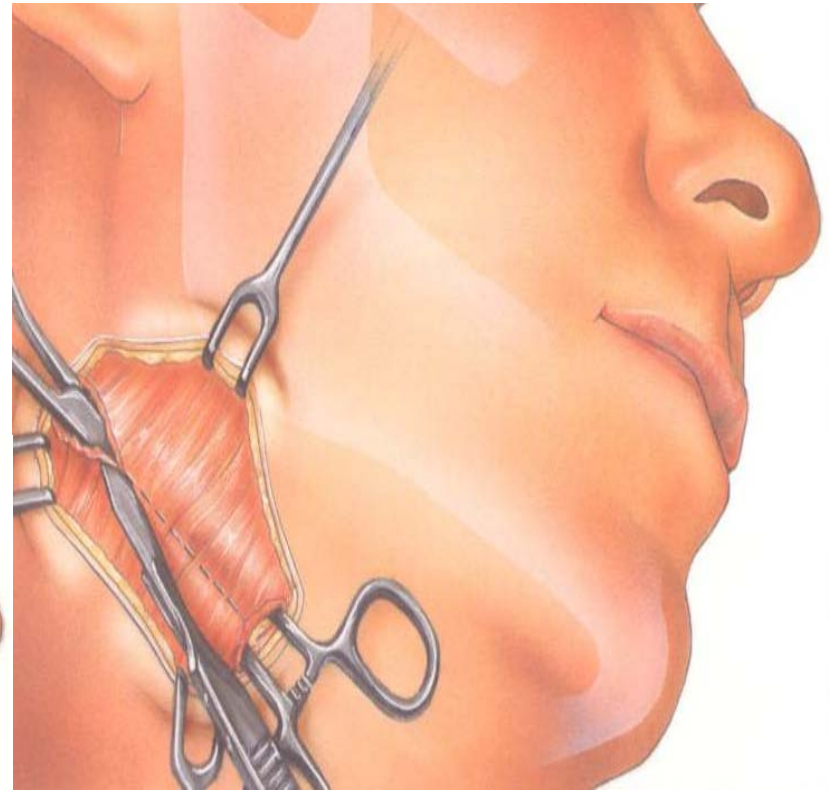
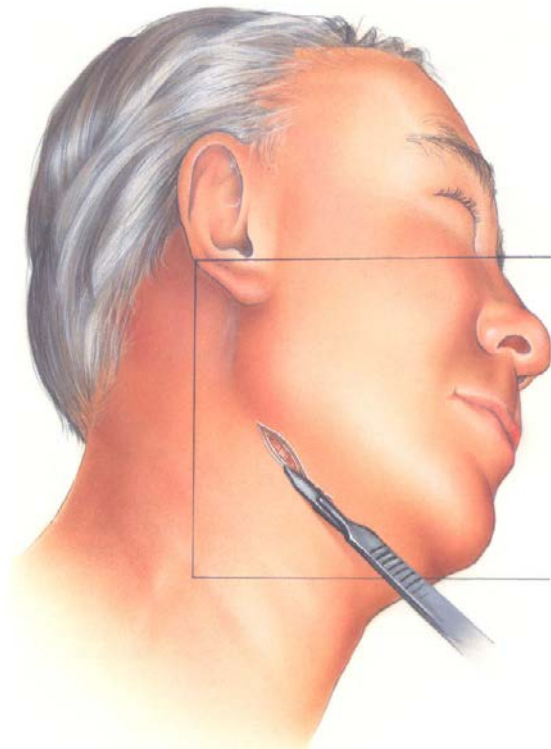
**tumor excision
and reconstruction**

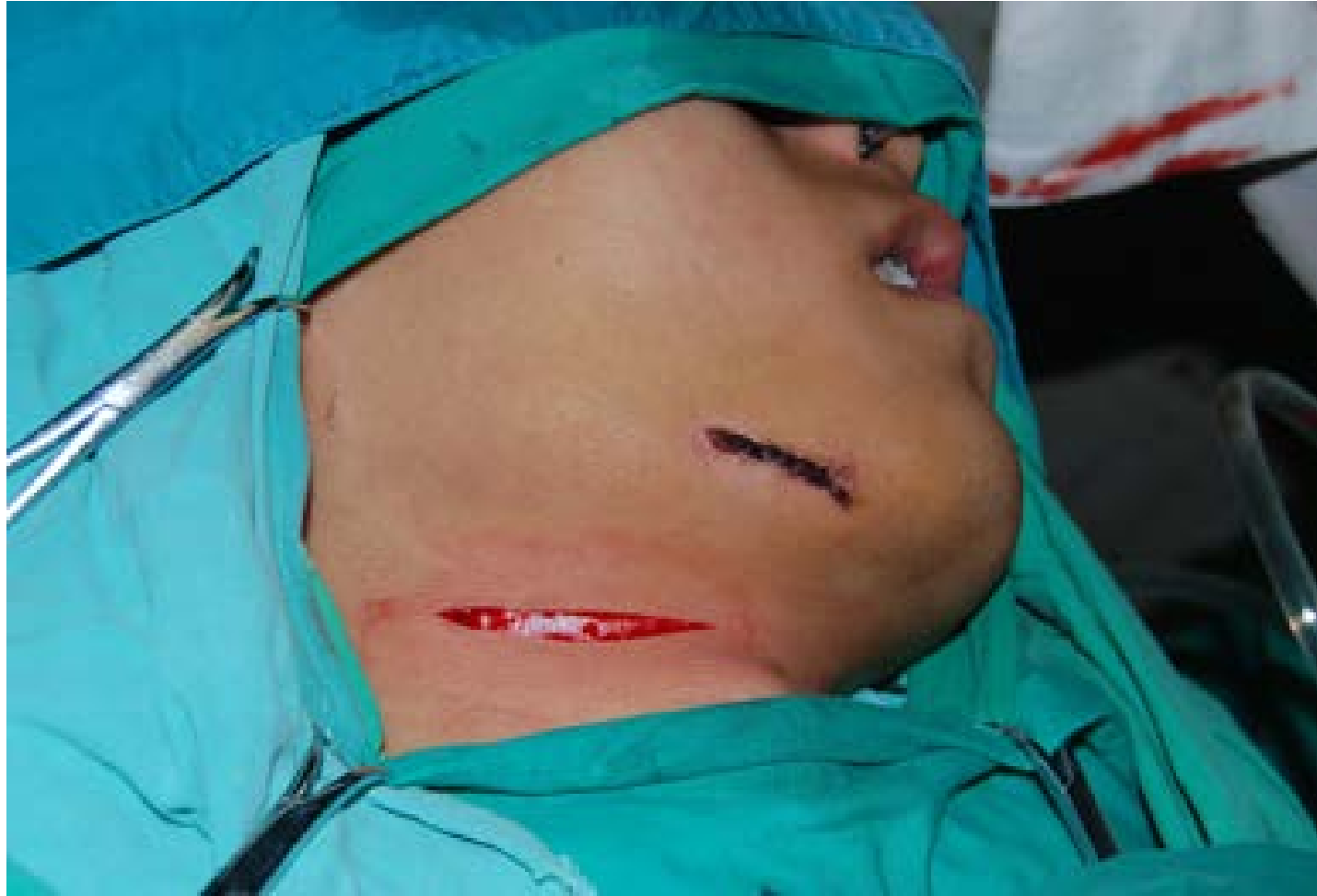



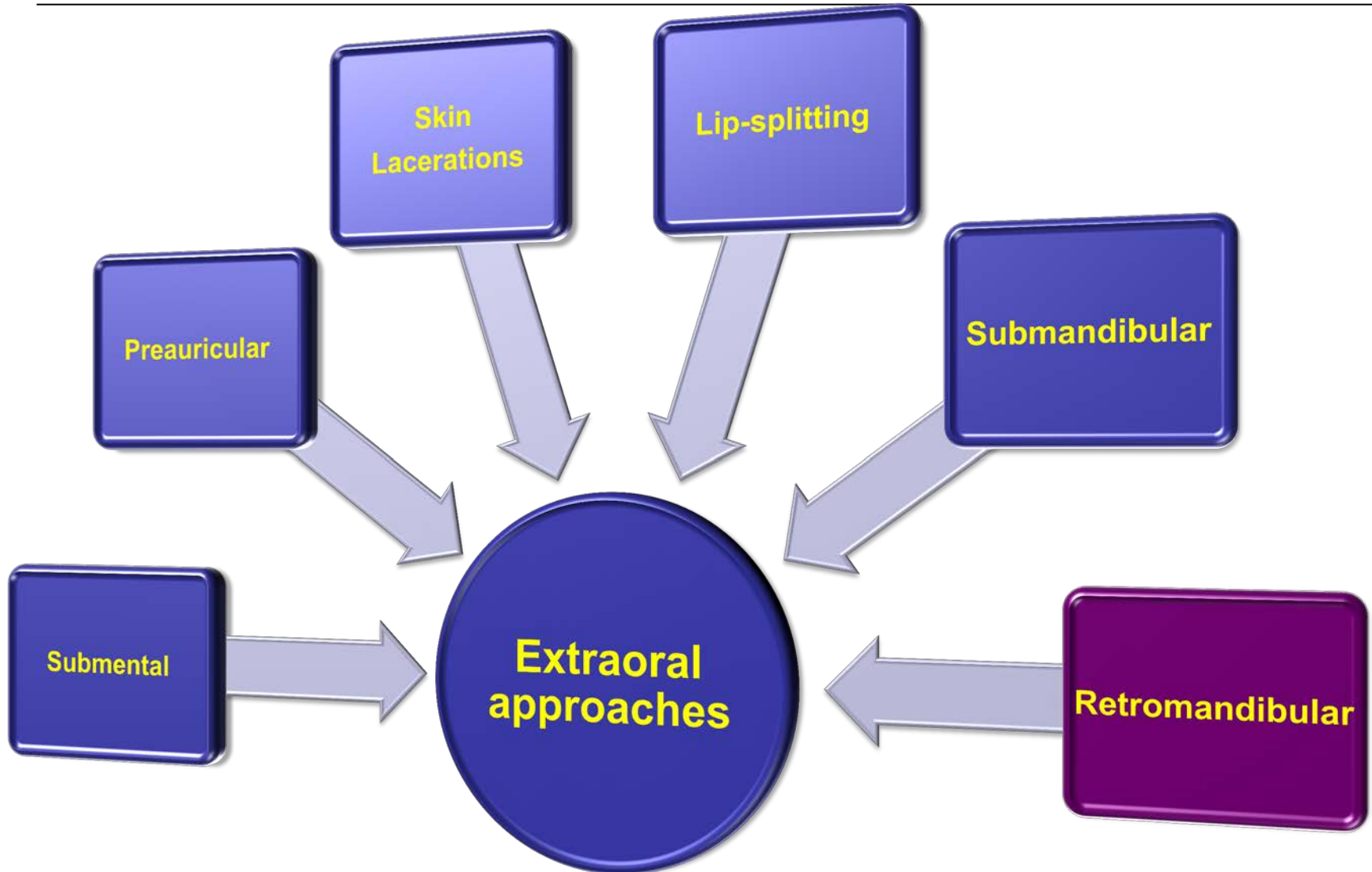
Submadibular approach







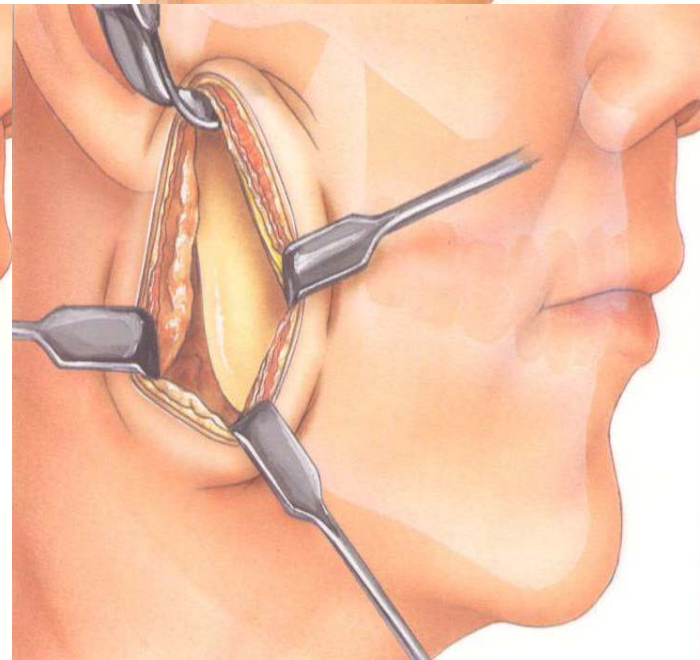
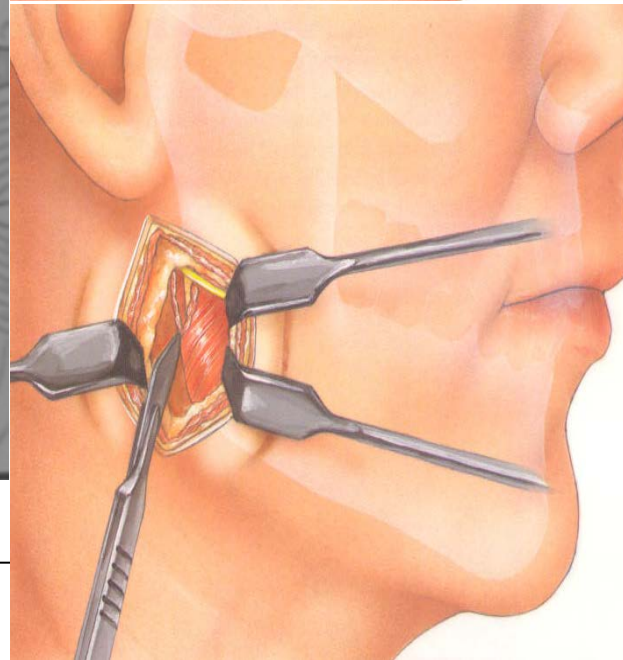
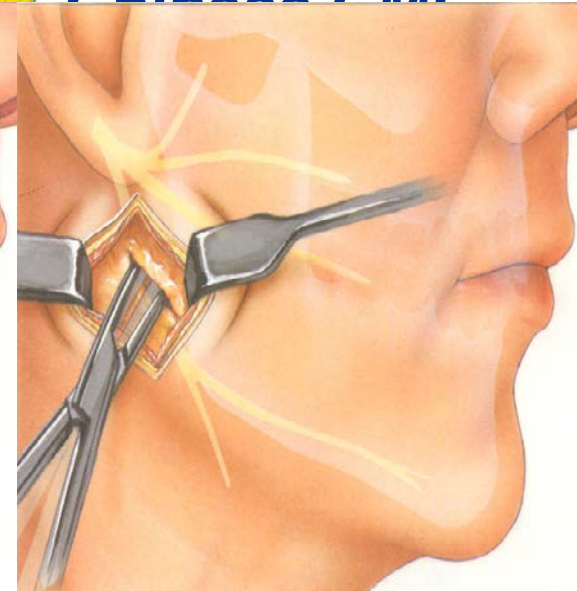
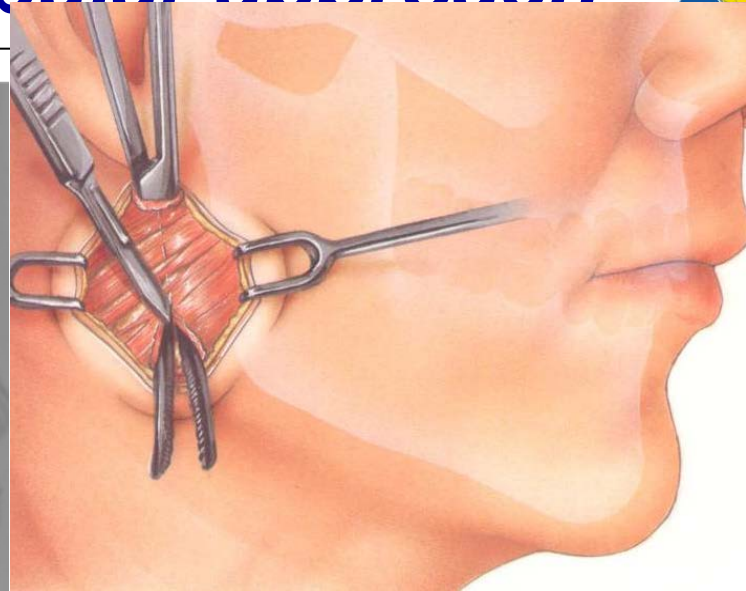
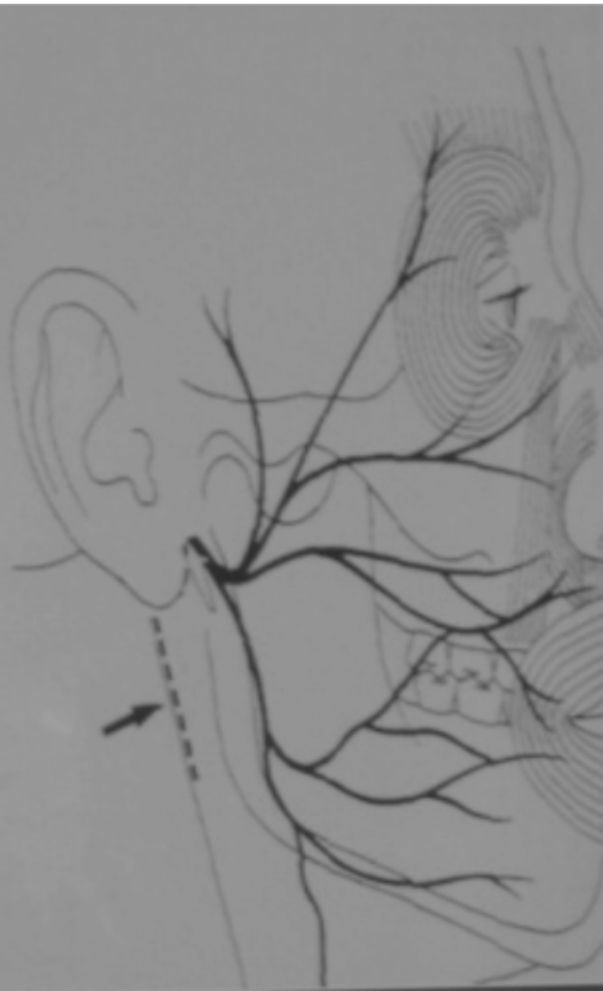Extraoral approach to mandible Chinese CMF



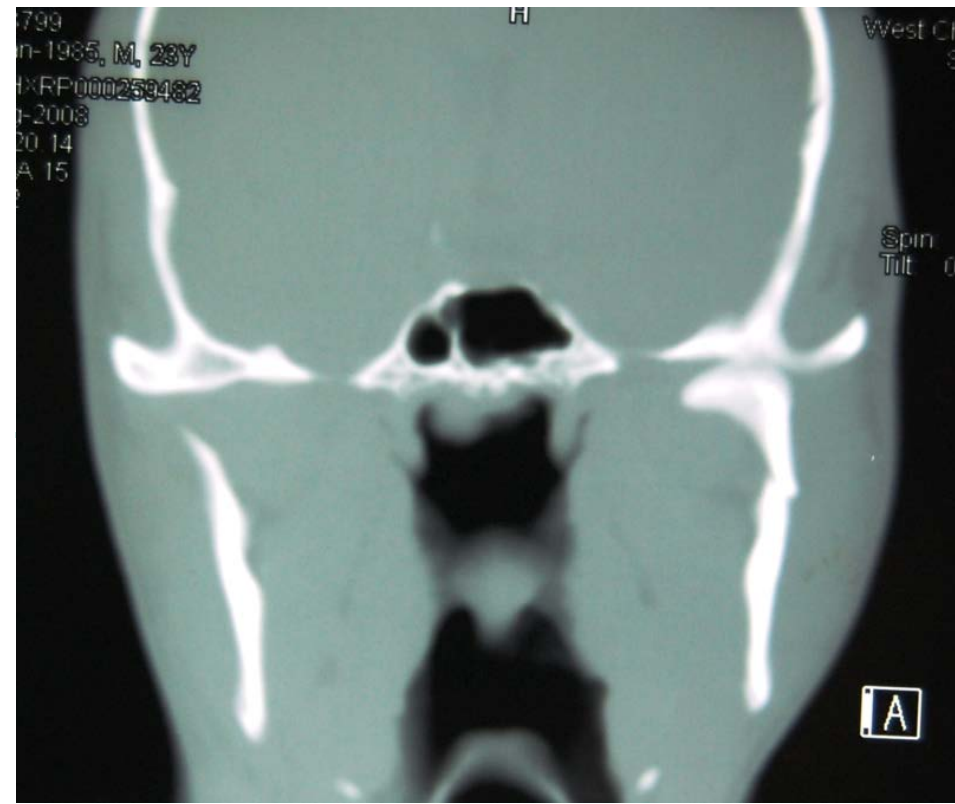
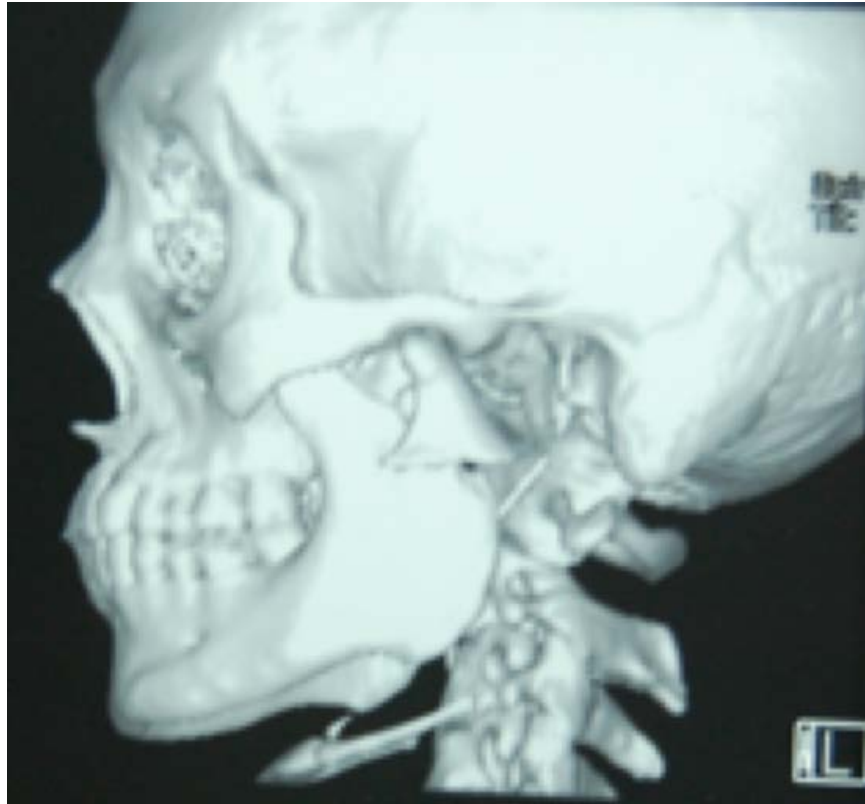
retromandibular approach

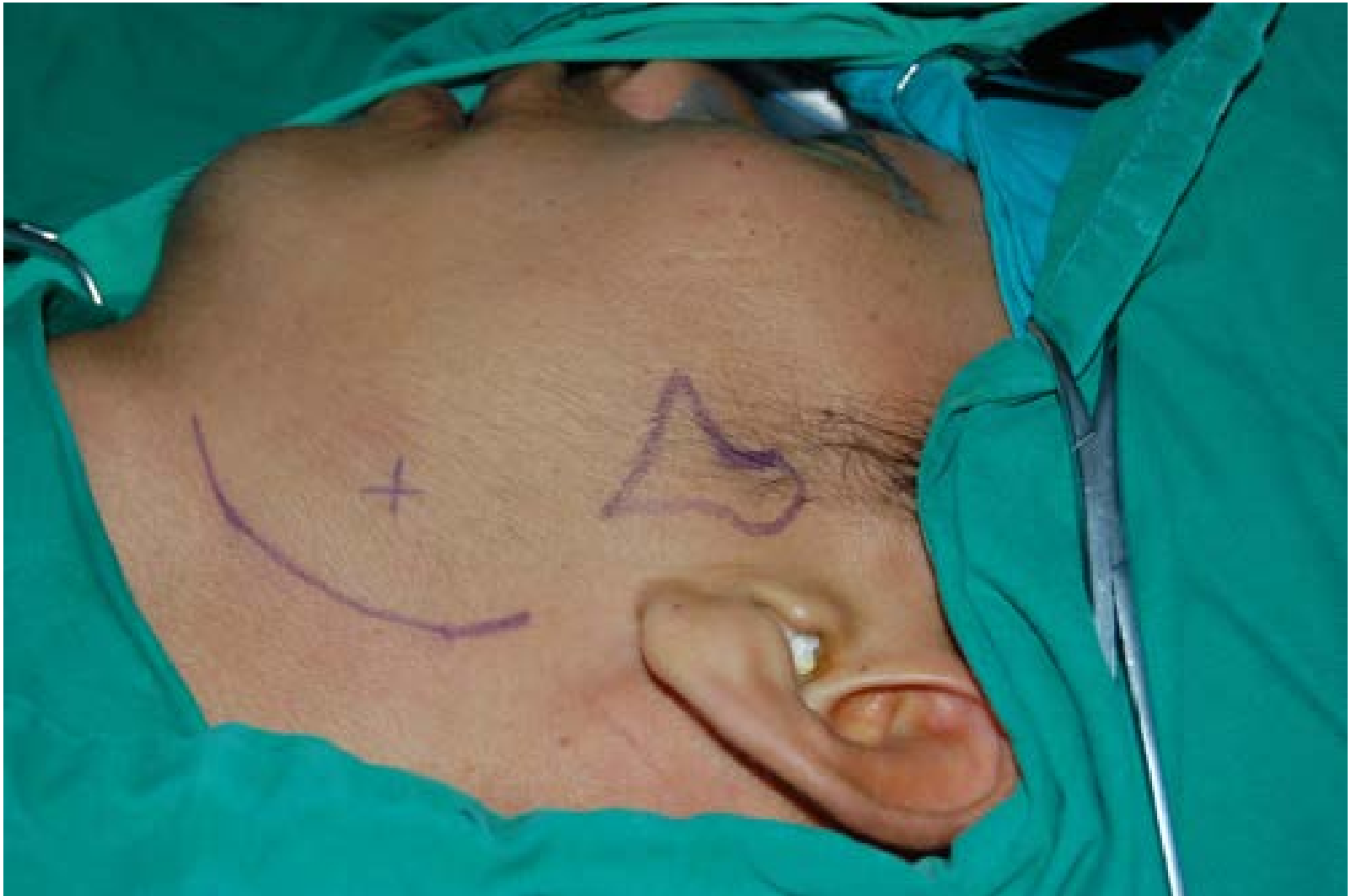

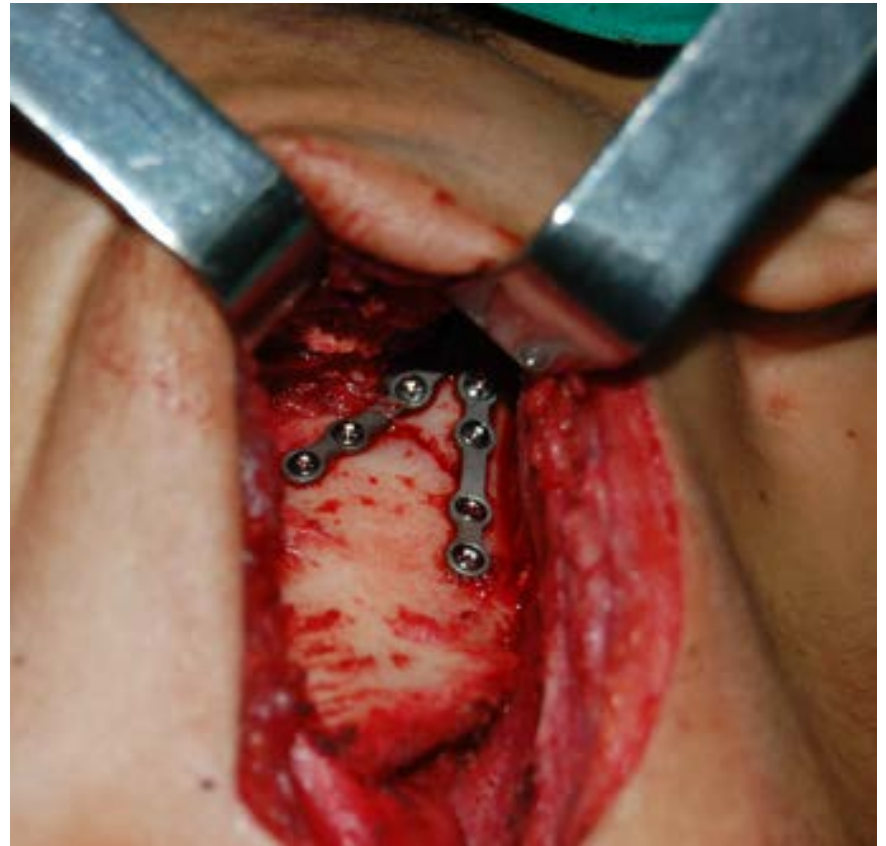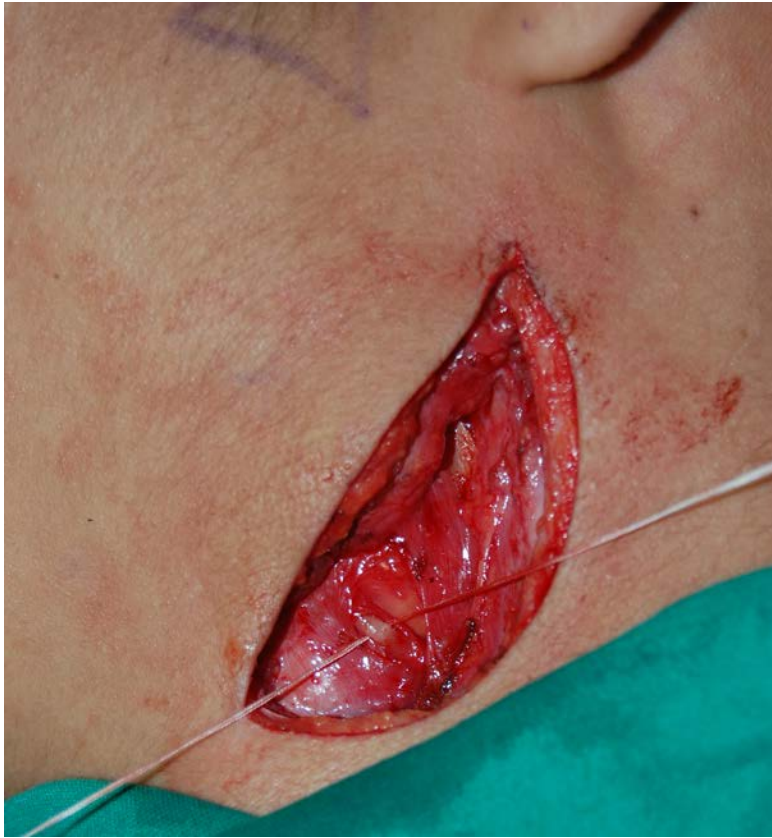Chinese CMF



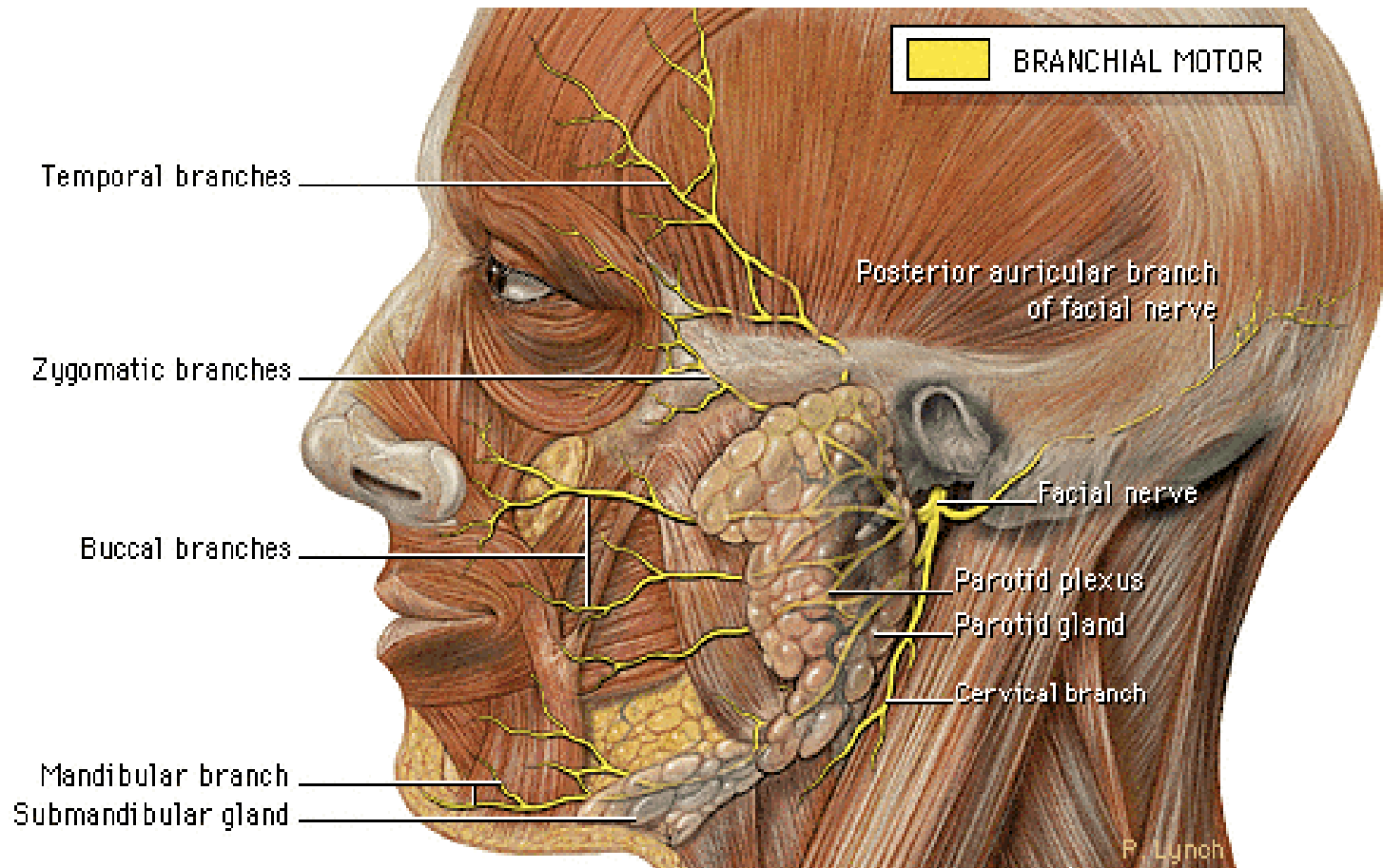
Subcondylar fracture



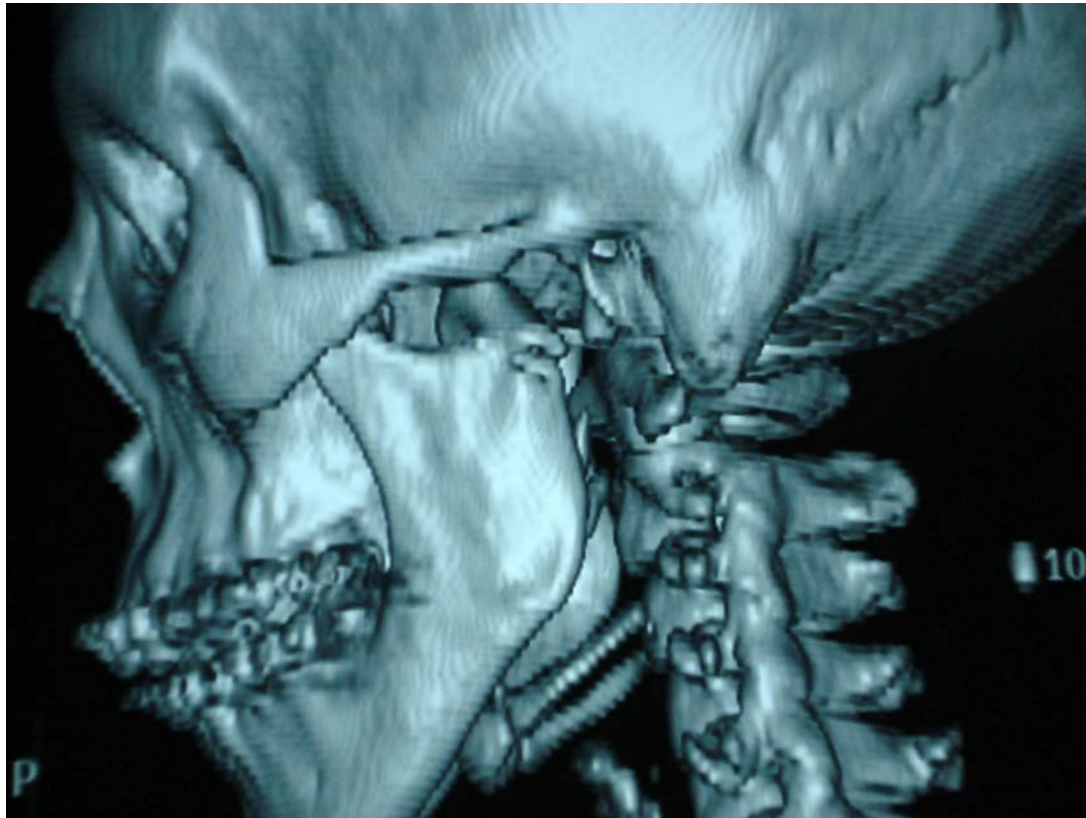


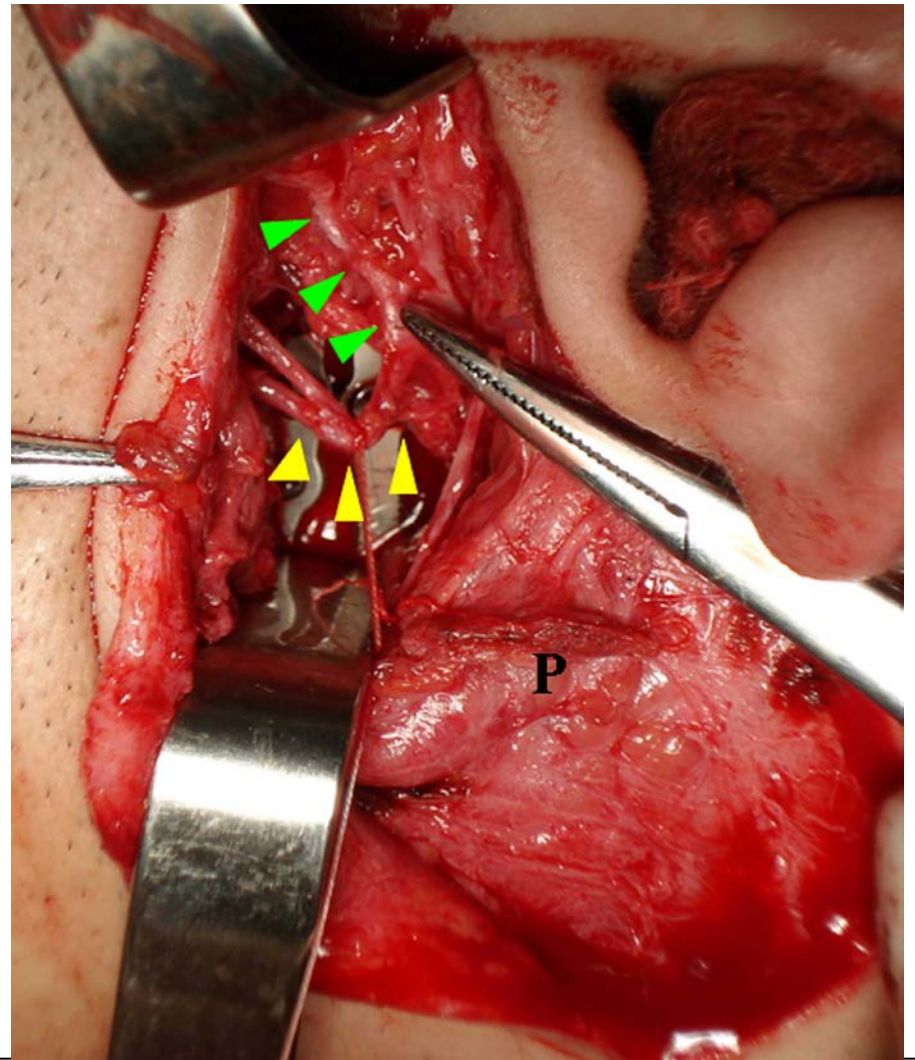
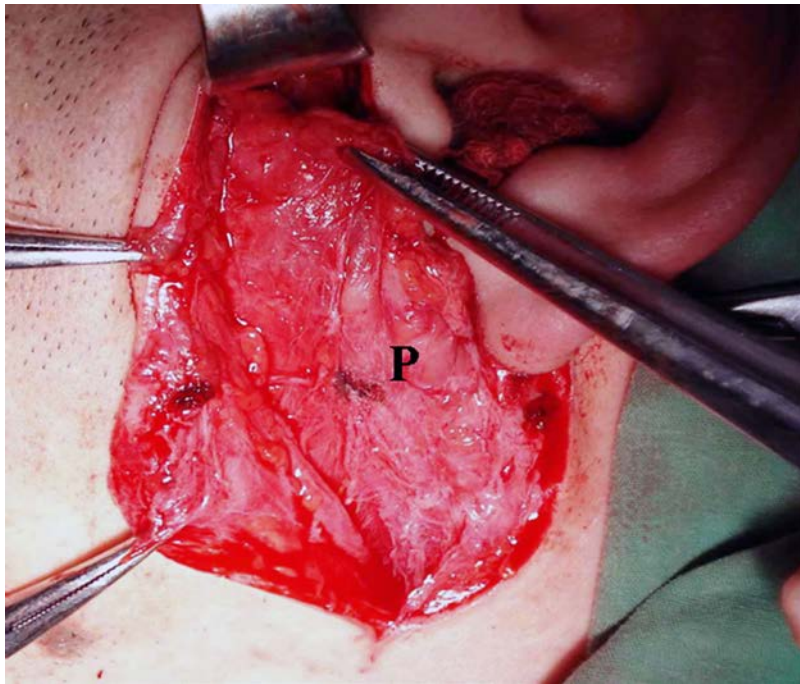


Modified Retromandibular approach from anterior edge of parotid gland

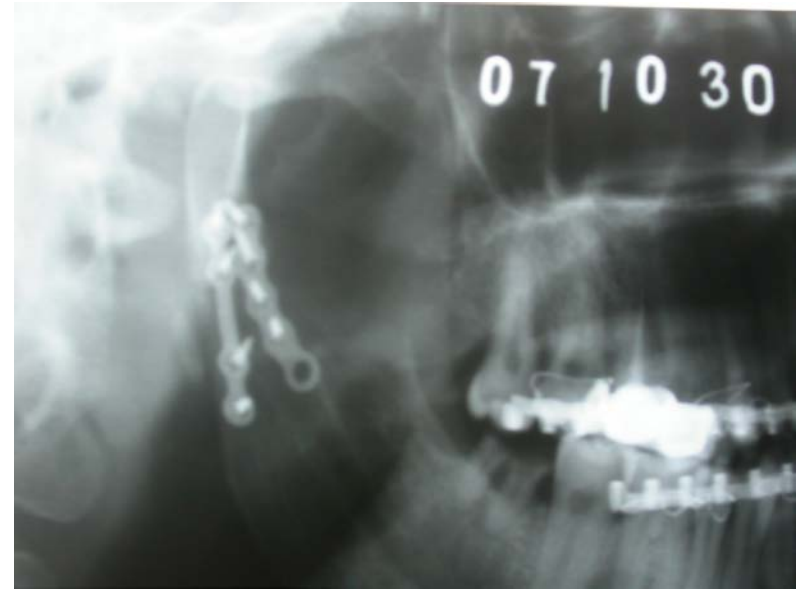
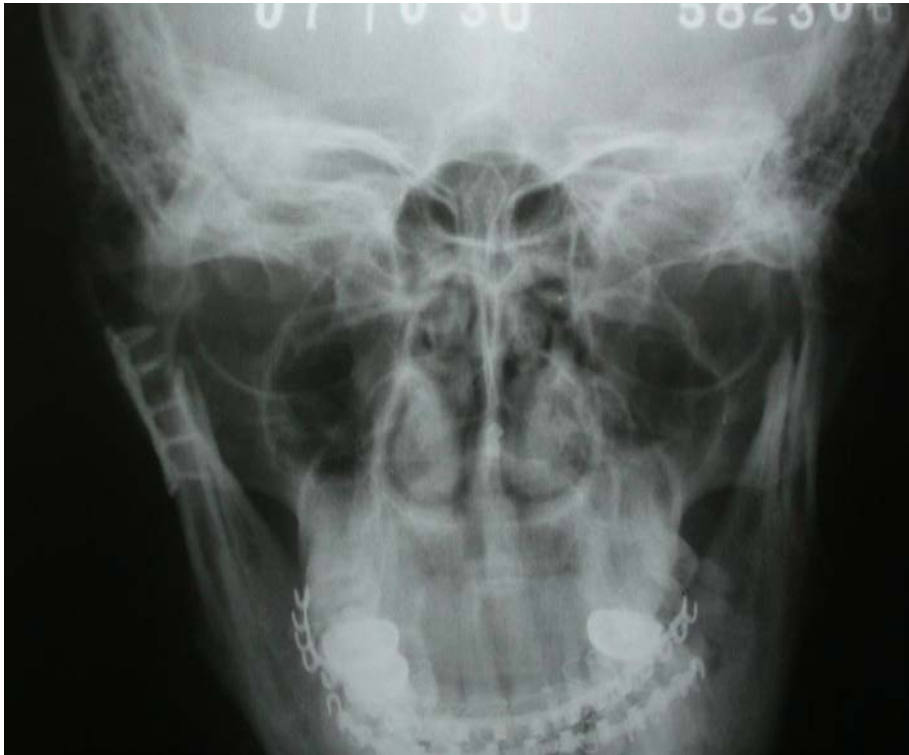
case 1



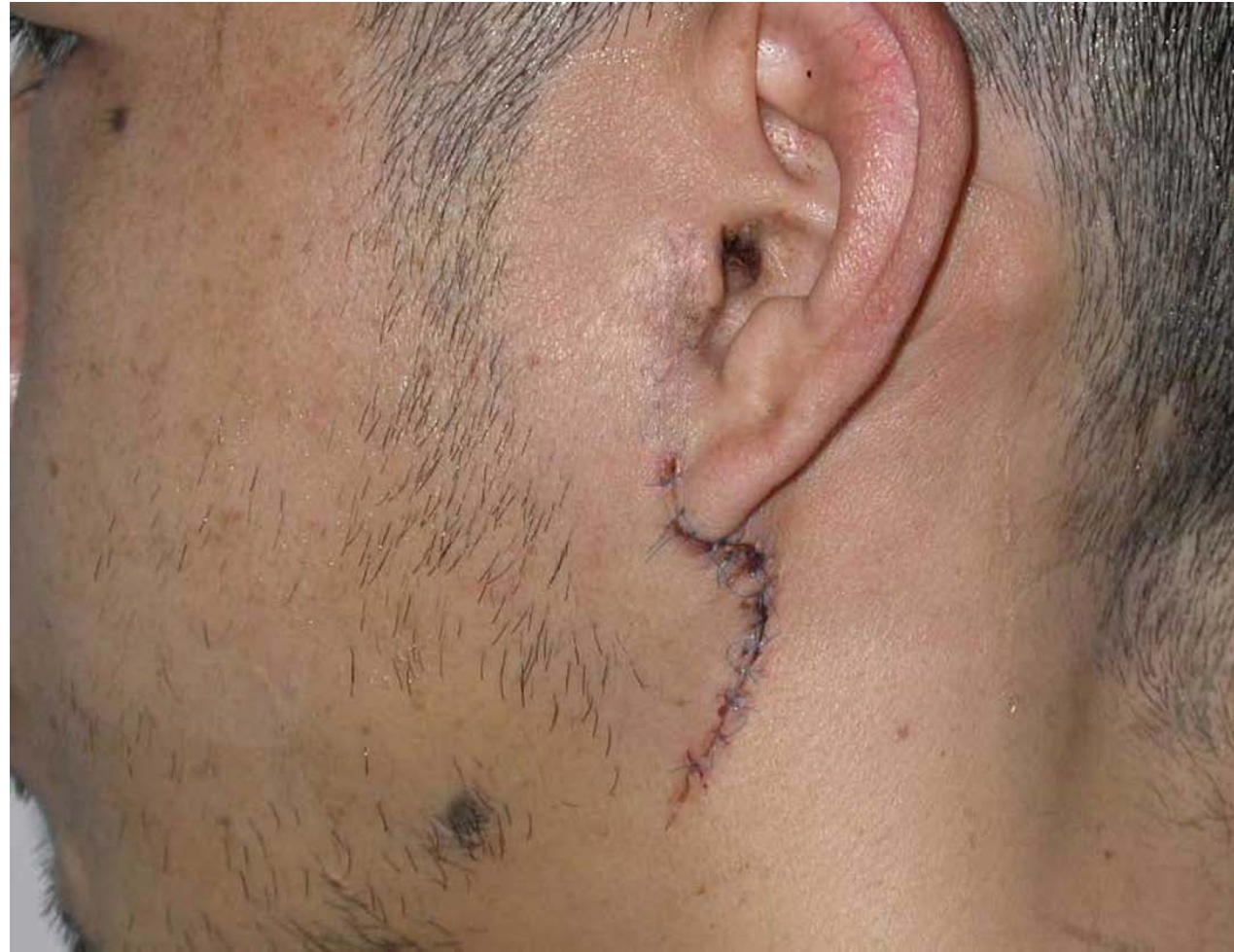

green: temporal branch
yellow: zygomatic branch



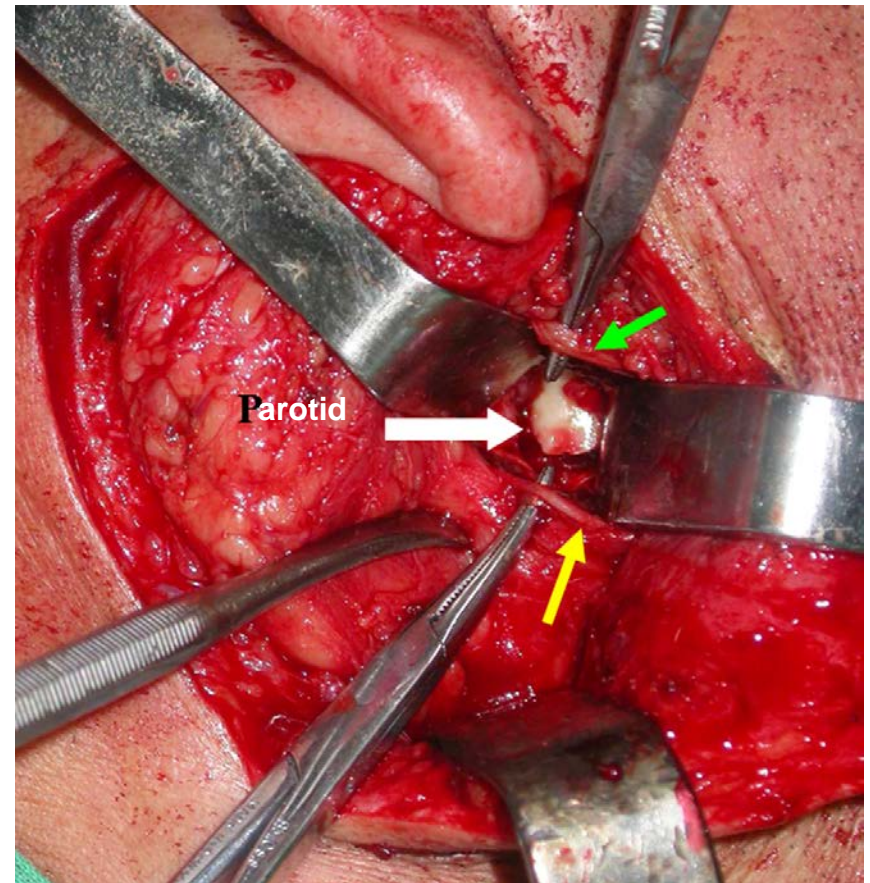
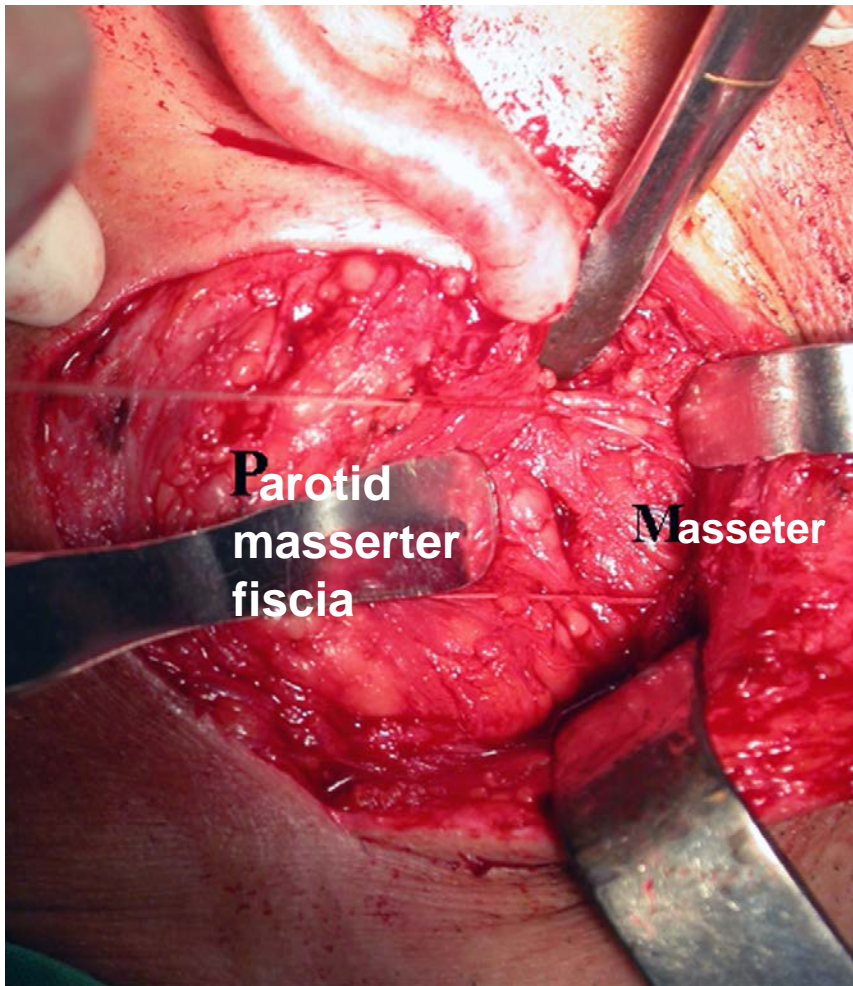
Post-OP 1 Week

Incision scar
1 week after OP

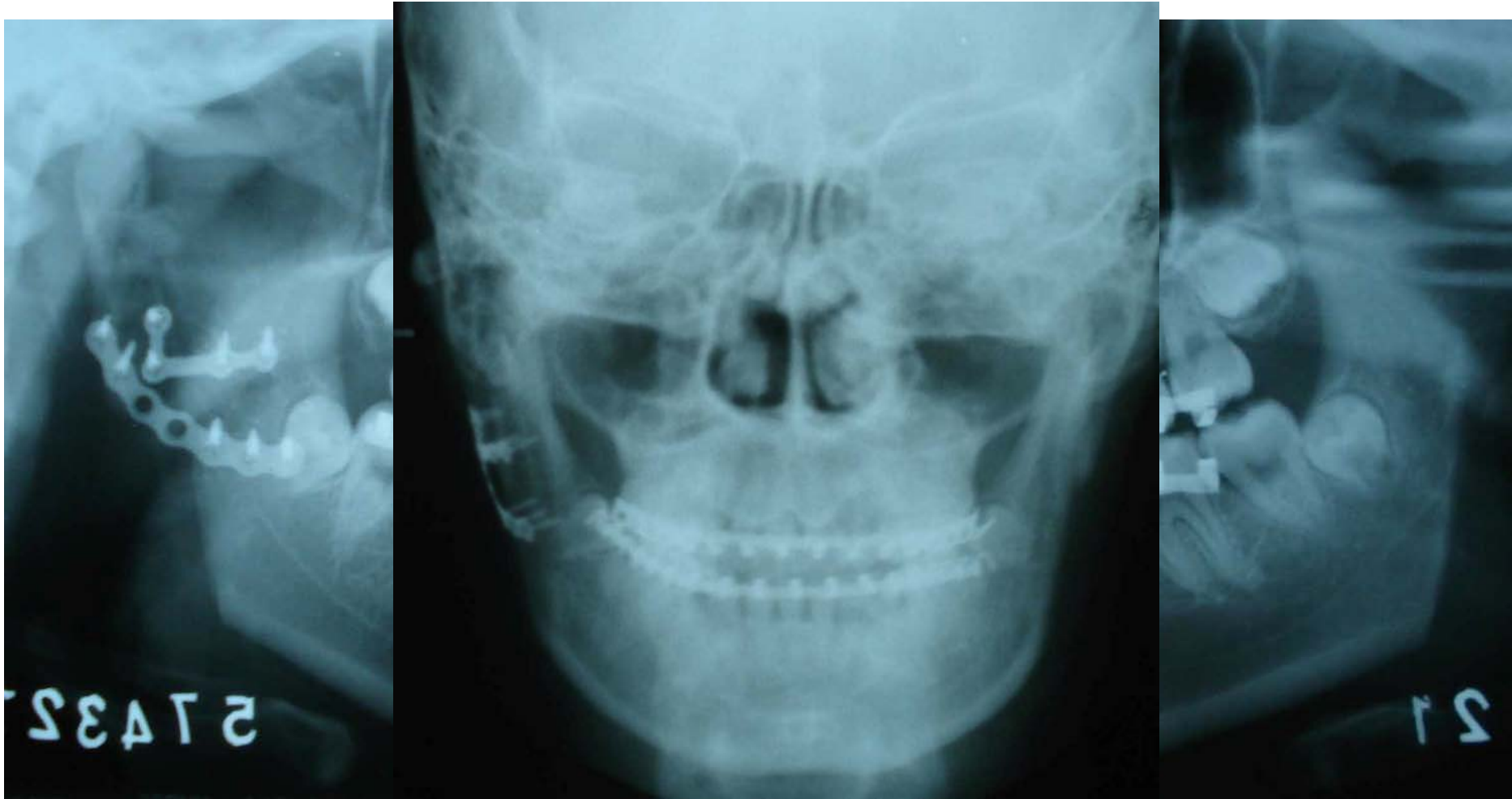

Case 2

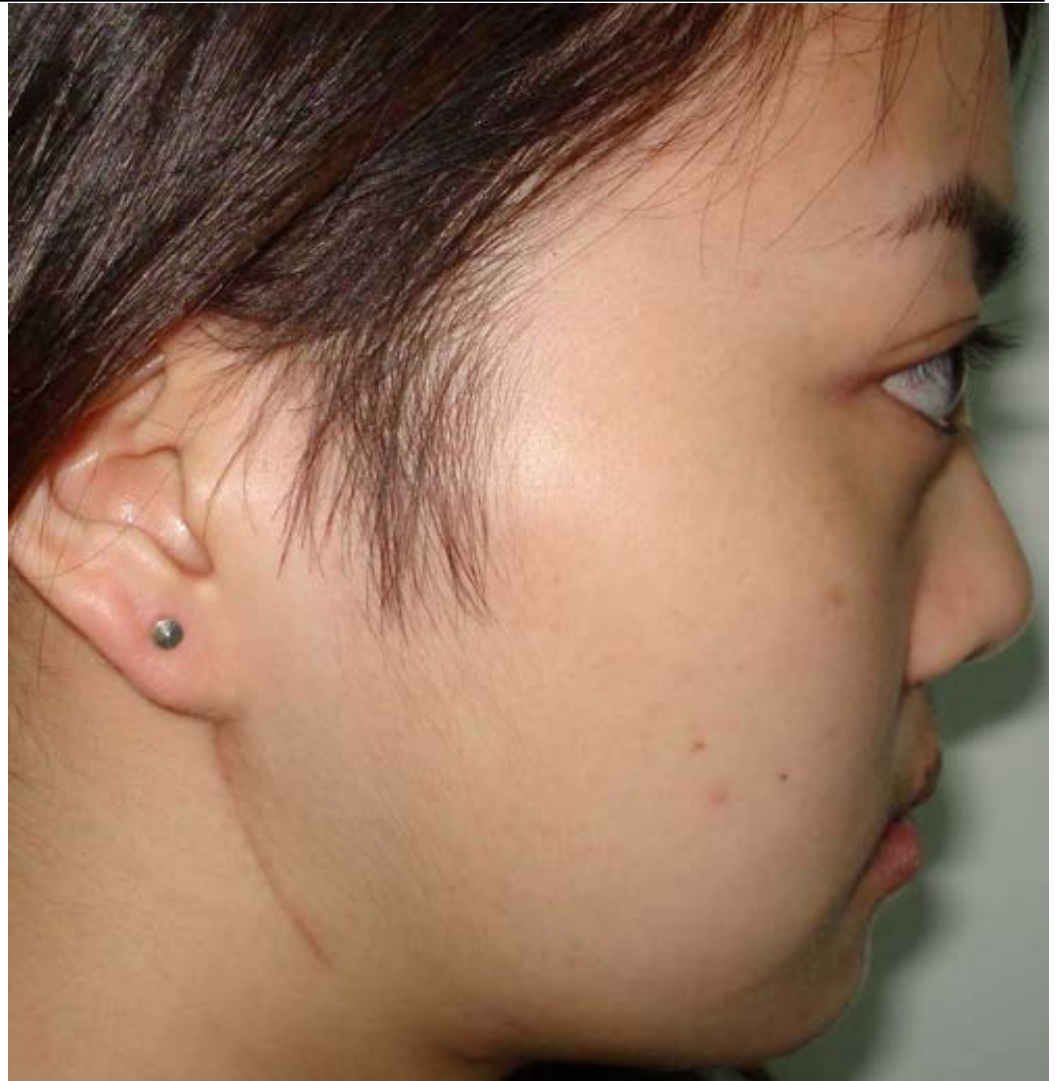Right subcondylar fracture
after inappropriate operation of mandibular angle resection.



green: paritid duct
white: fracture
yellow: buccal branch



Inconspicuous scars
3 months after OP



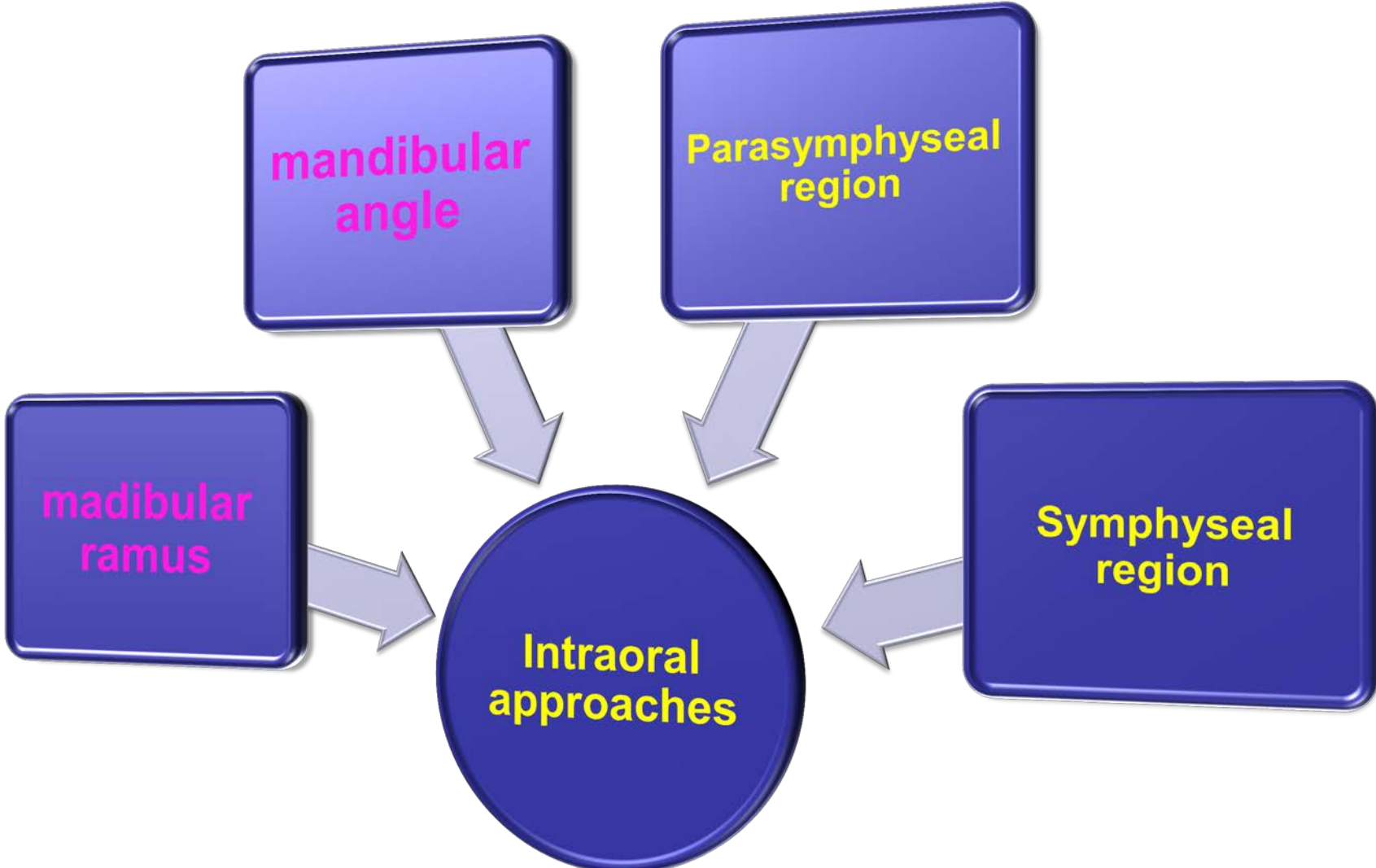
Modified retromandibular approach
indirectly from anterior edge of parotid
gland:

Clear exposure

Easy to fix the plate-screw system

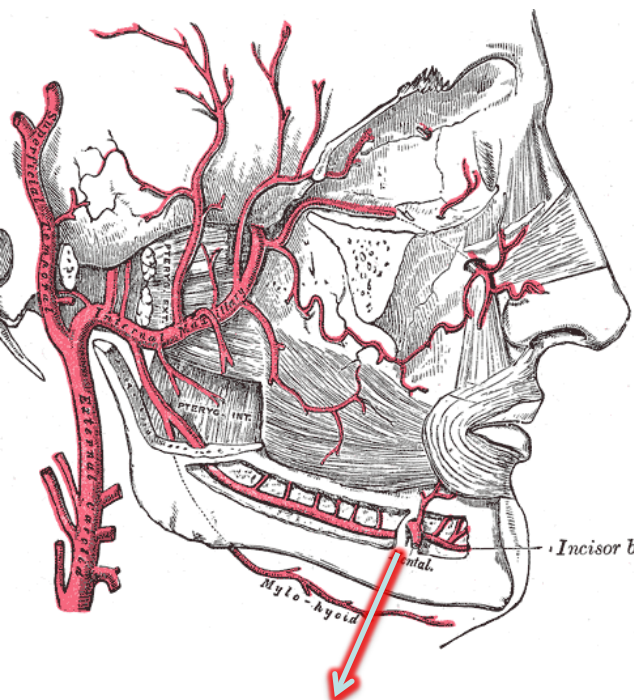
Reduce the risk of nerve damage

Suitable for condylar, ramus and coronoid
process fractures

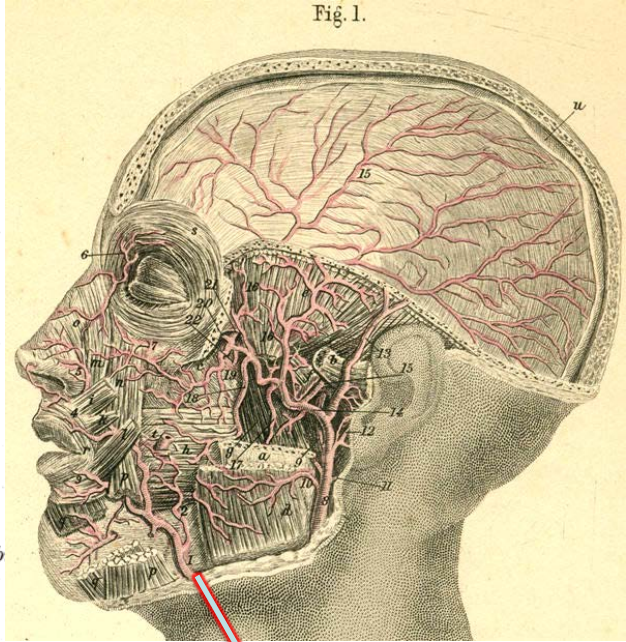


Mandibular vestibular approach

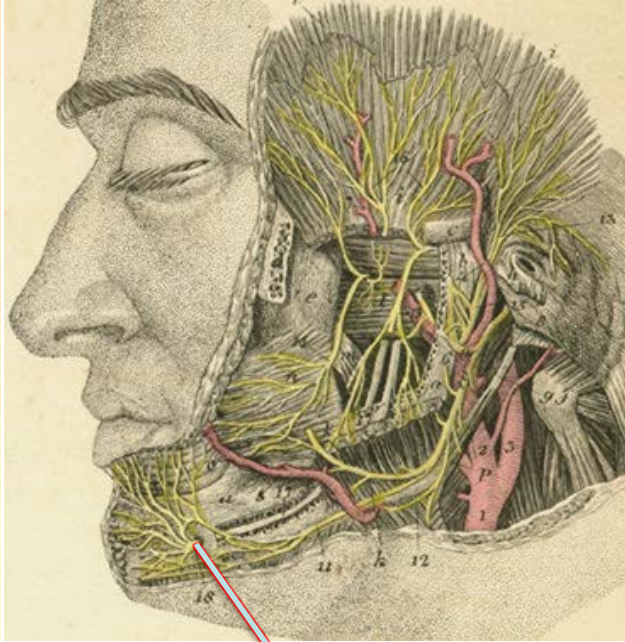
Allows safe access to the mandibular skeleton from the condyle to the symphysis and to control the occlusion during surgery



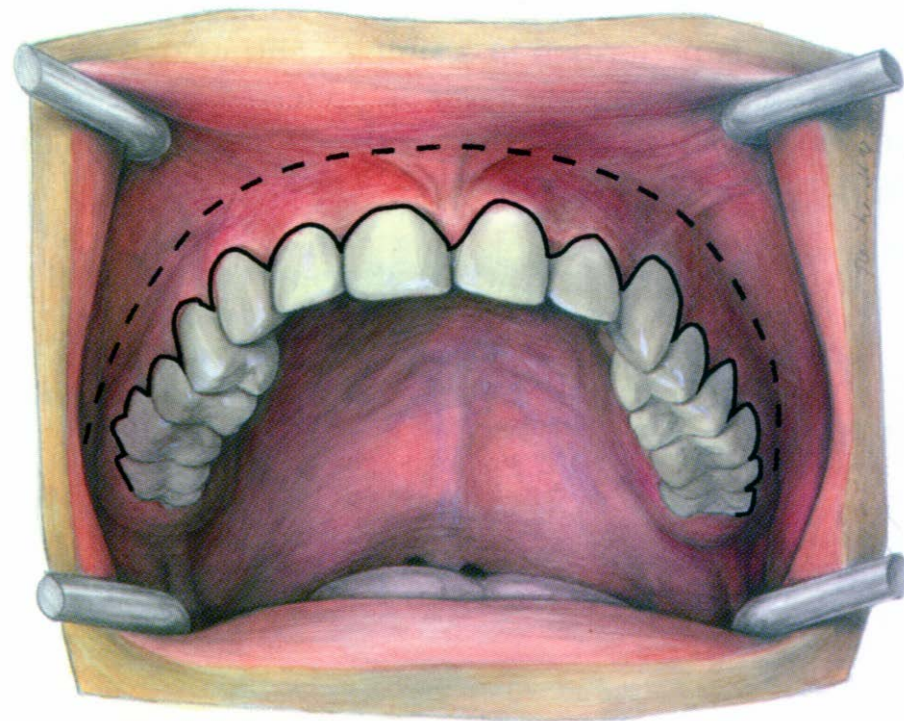
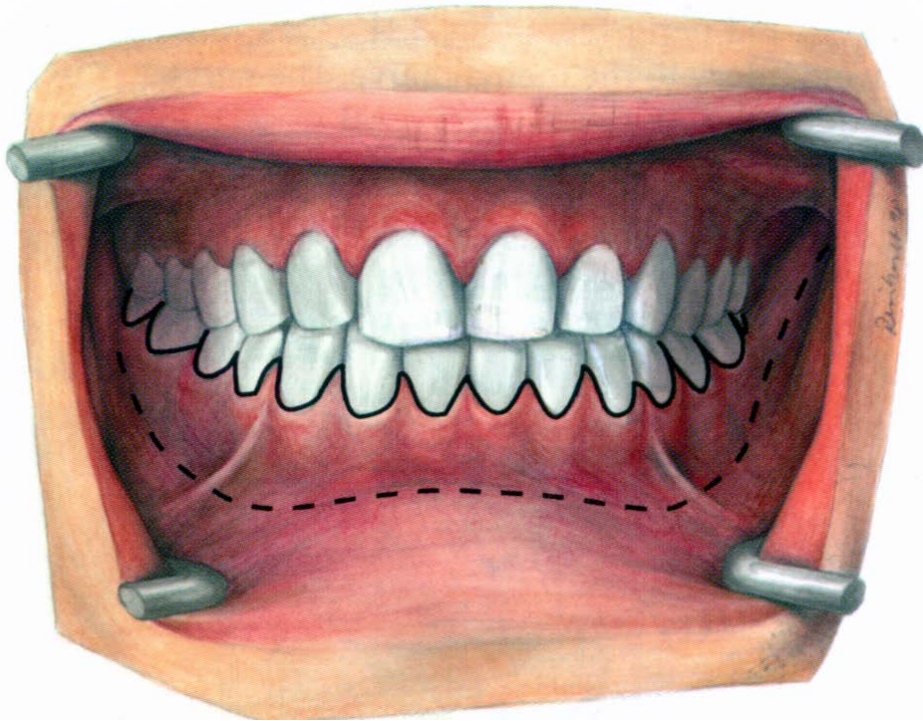
Mental artery

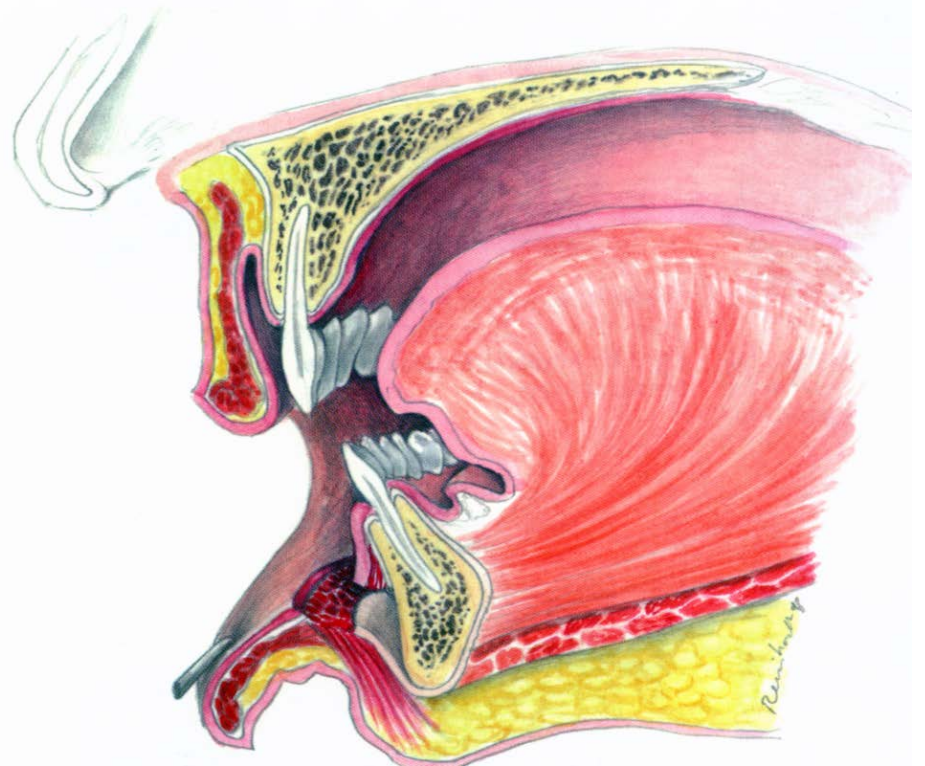
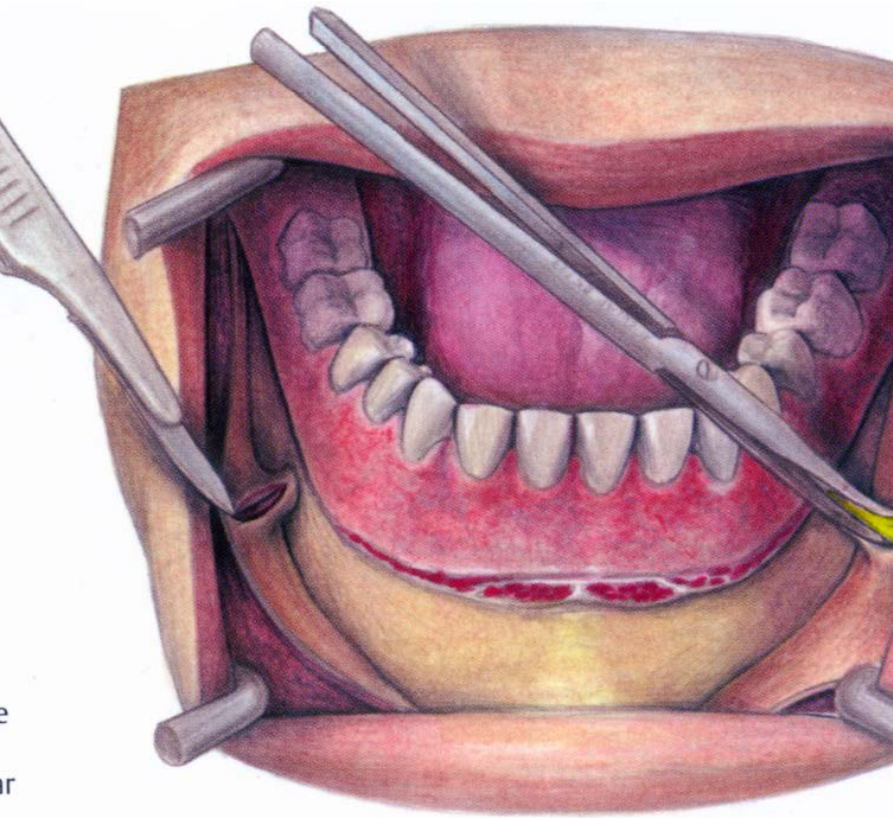


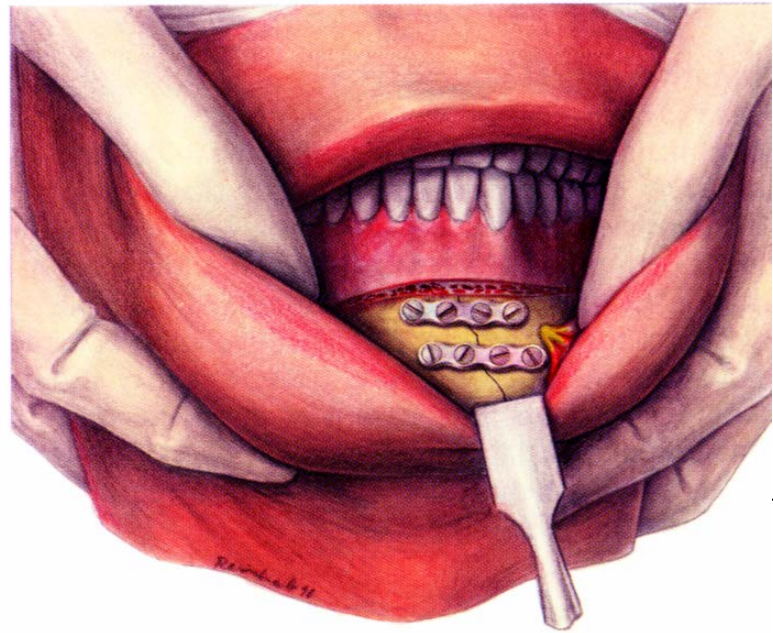
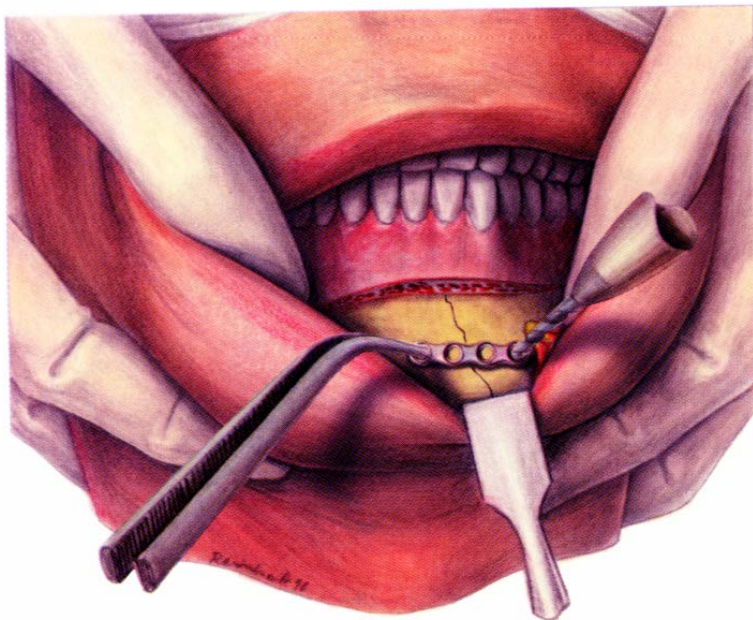
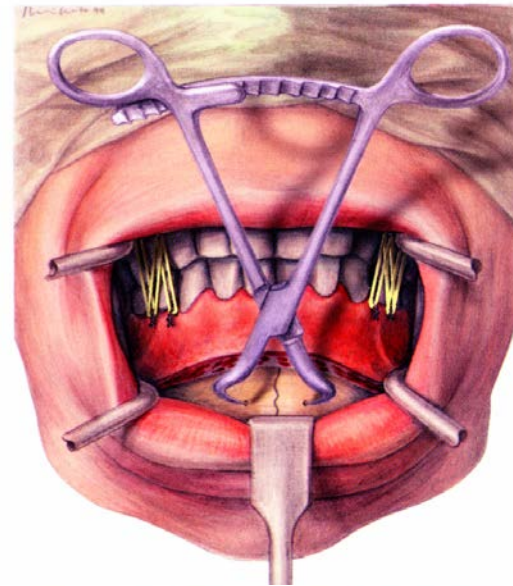
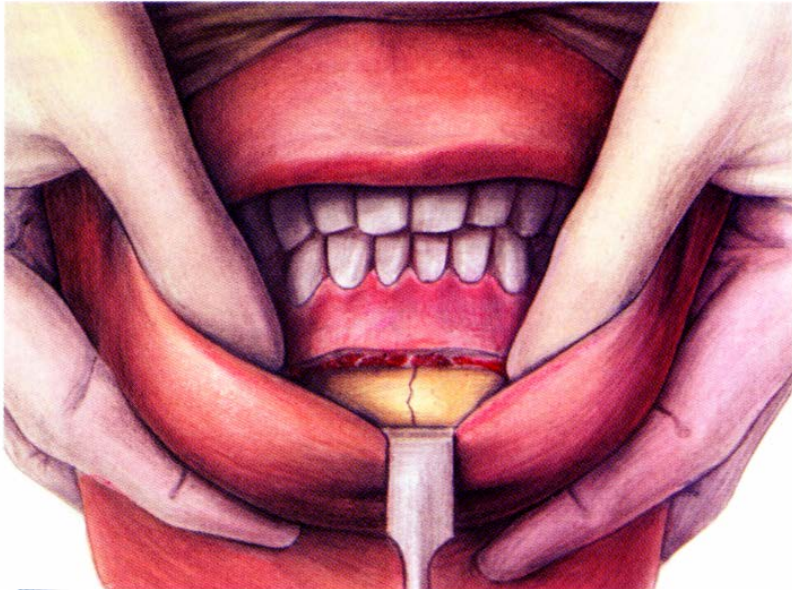
Facial artery

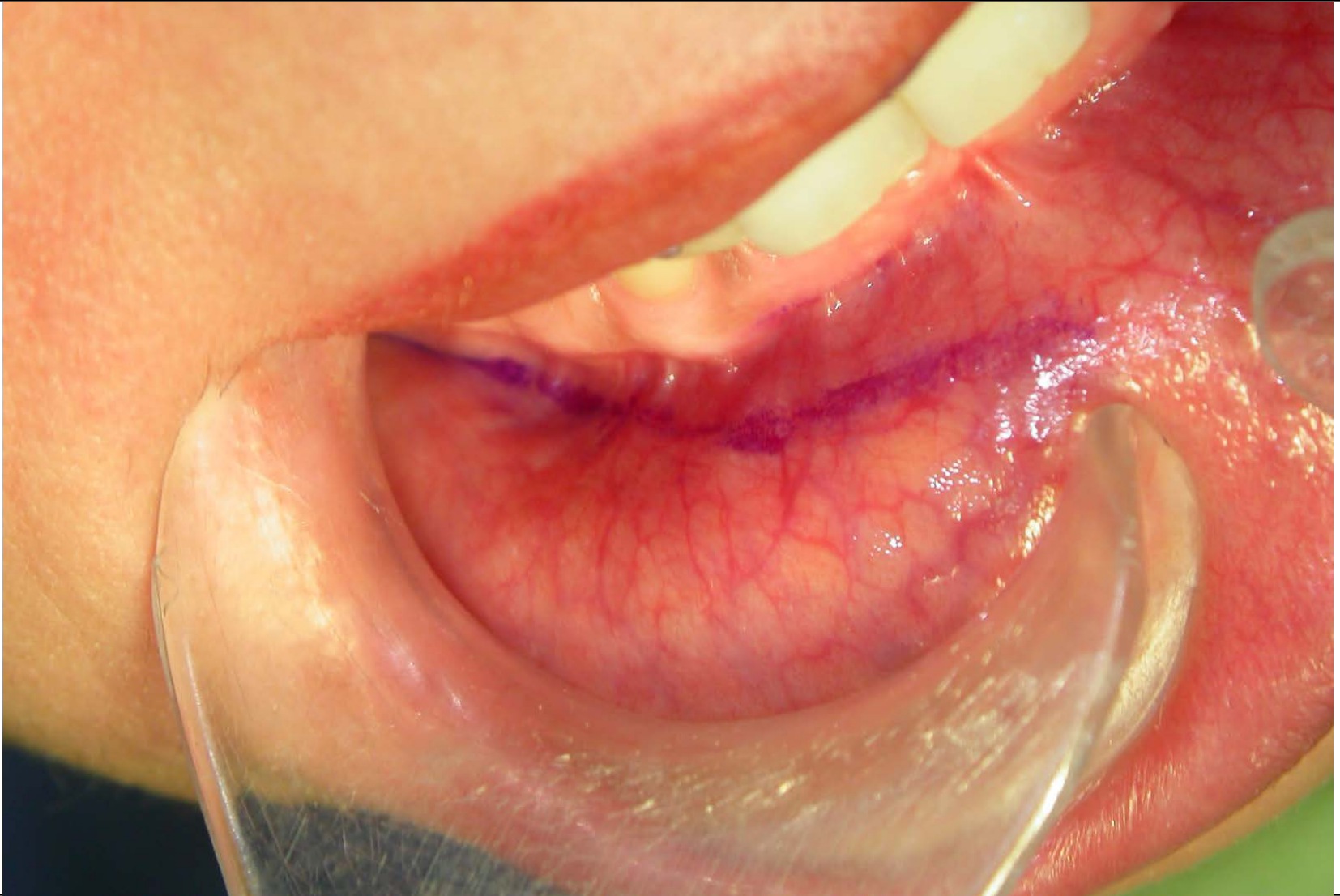

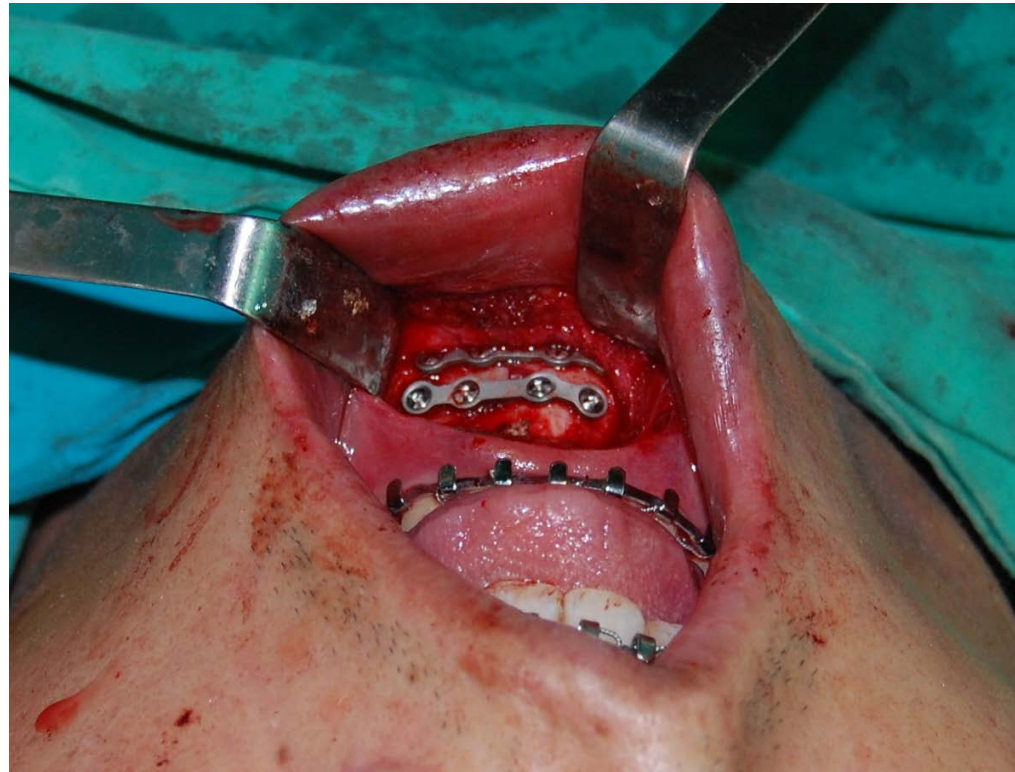
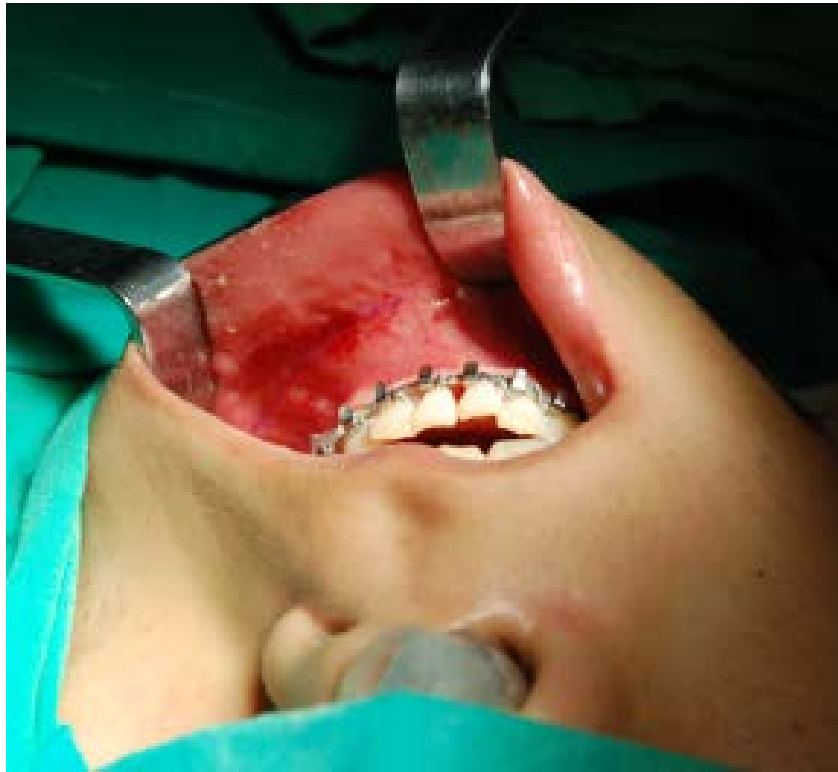Mental nerve

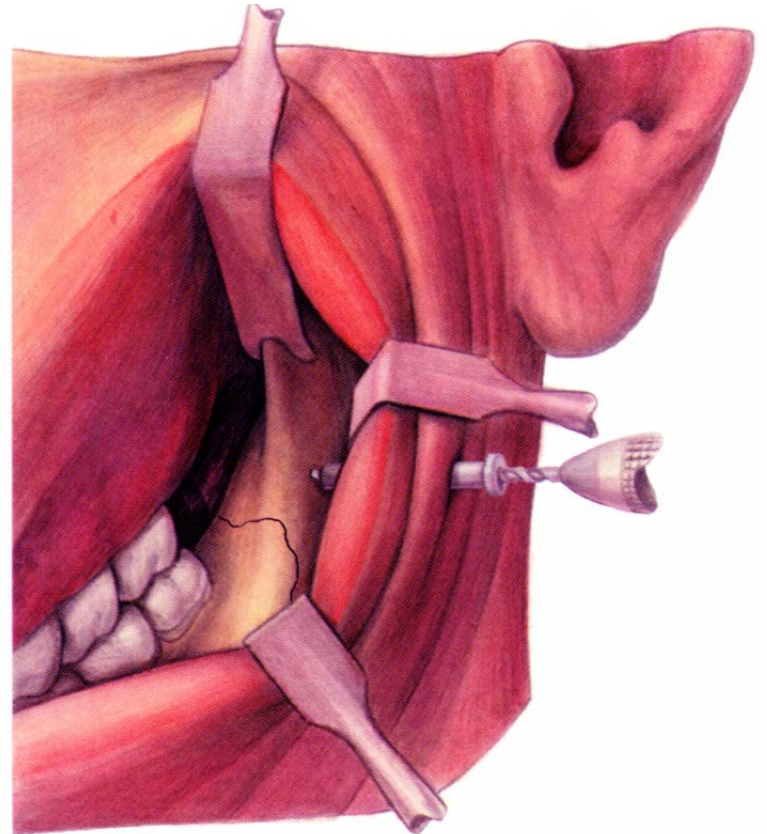
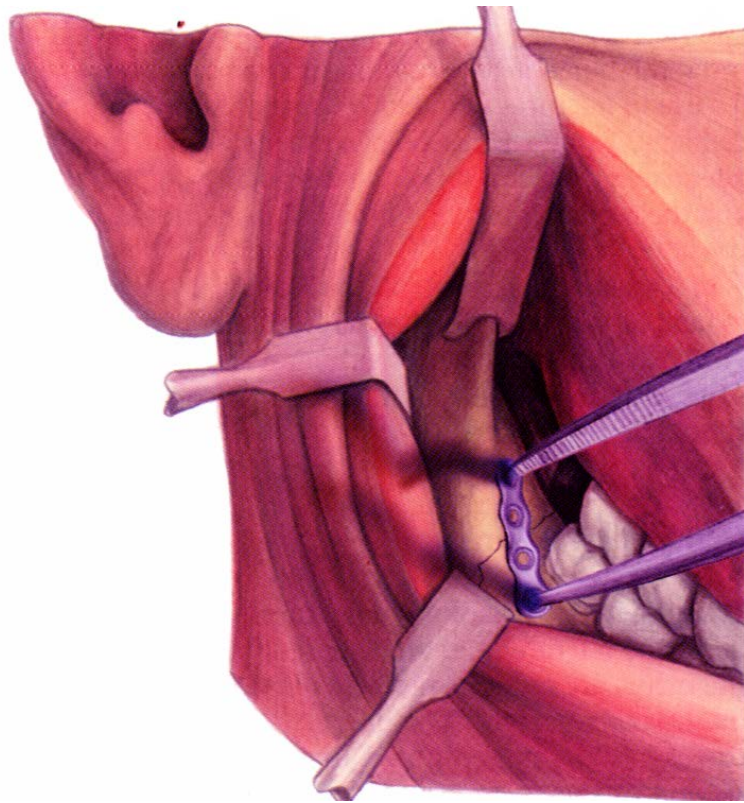




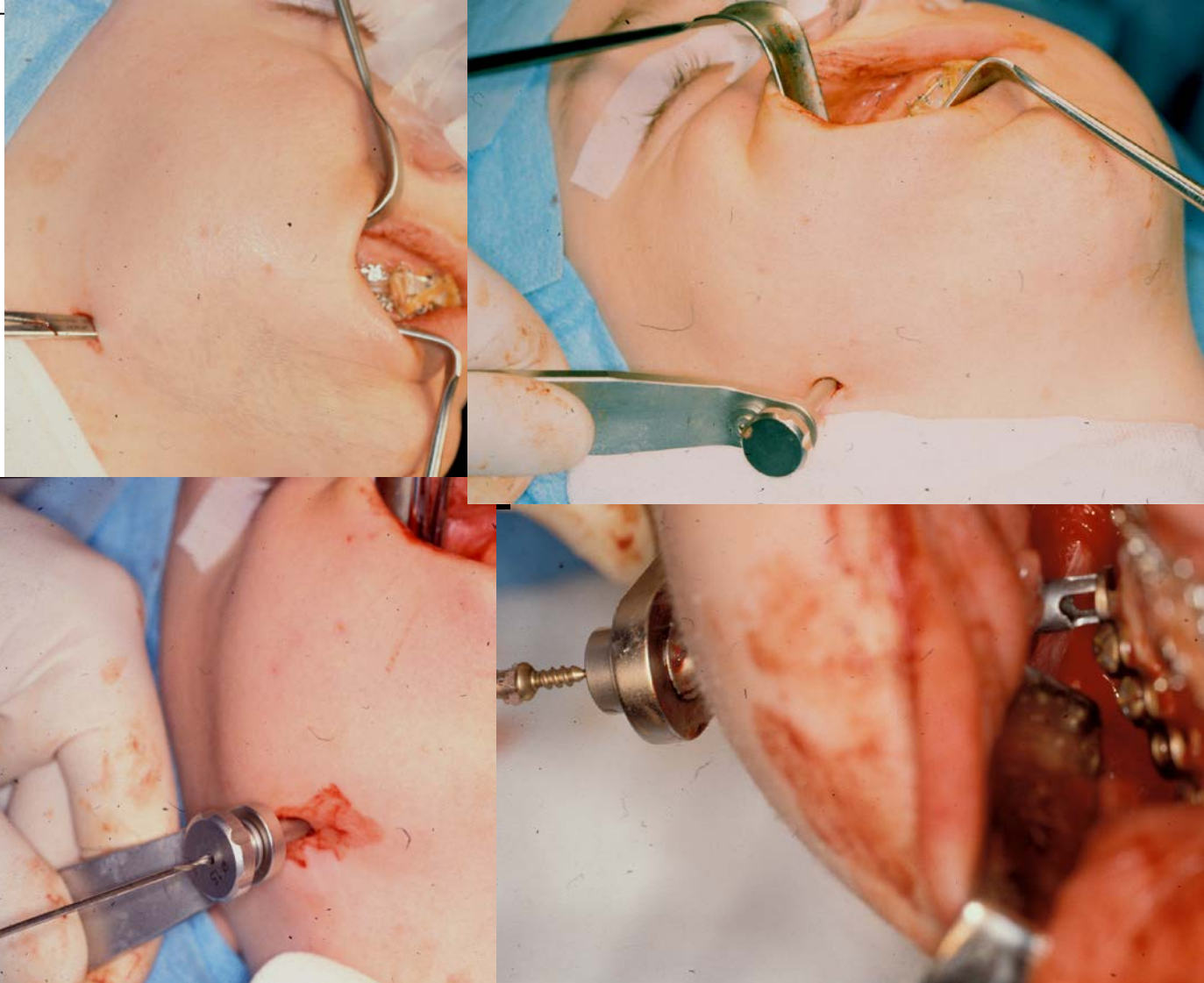


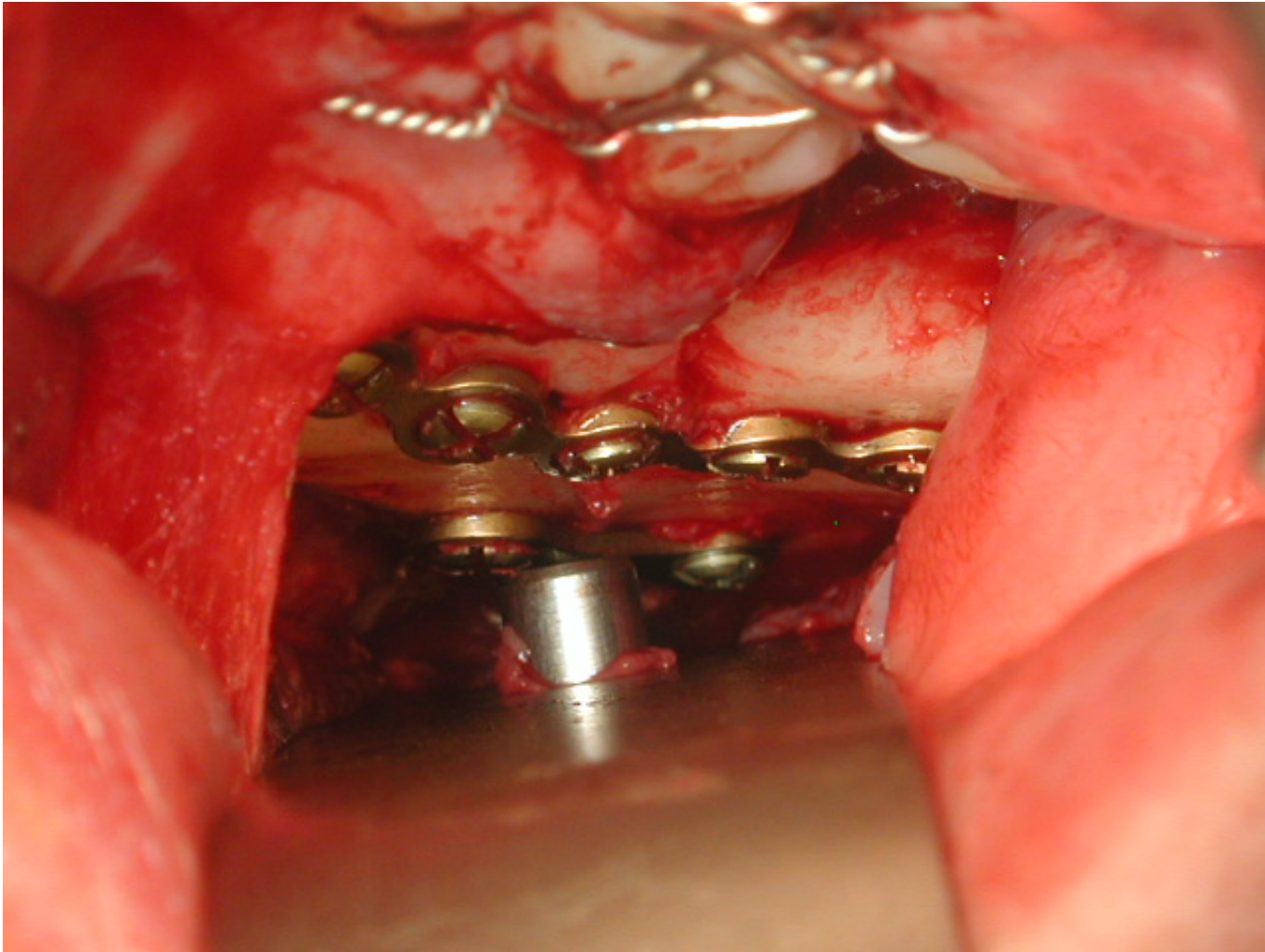


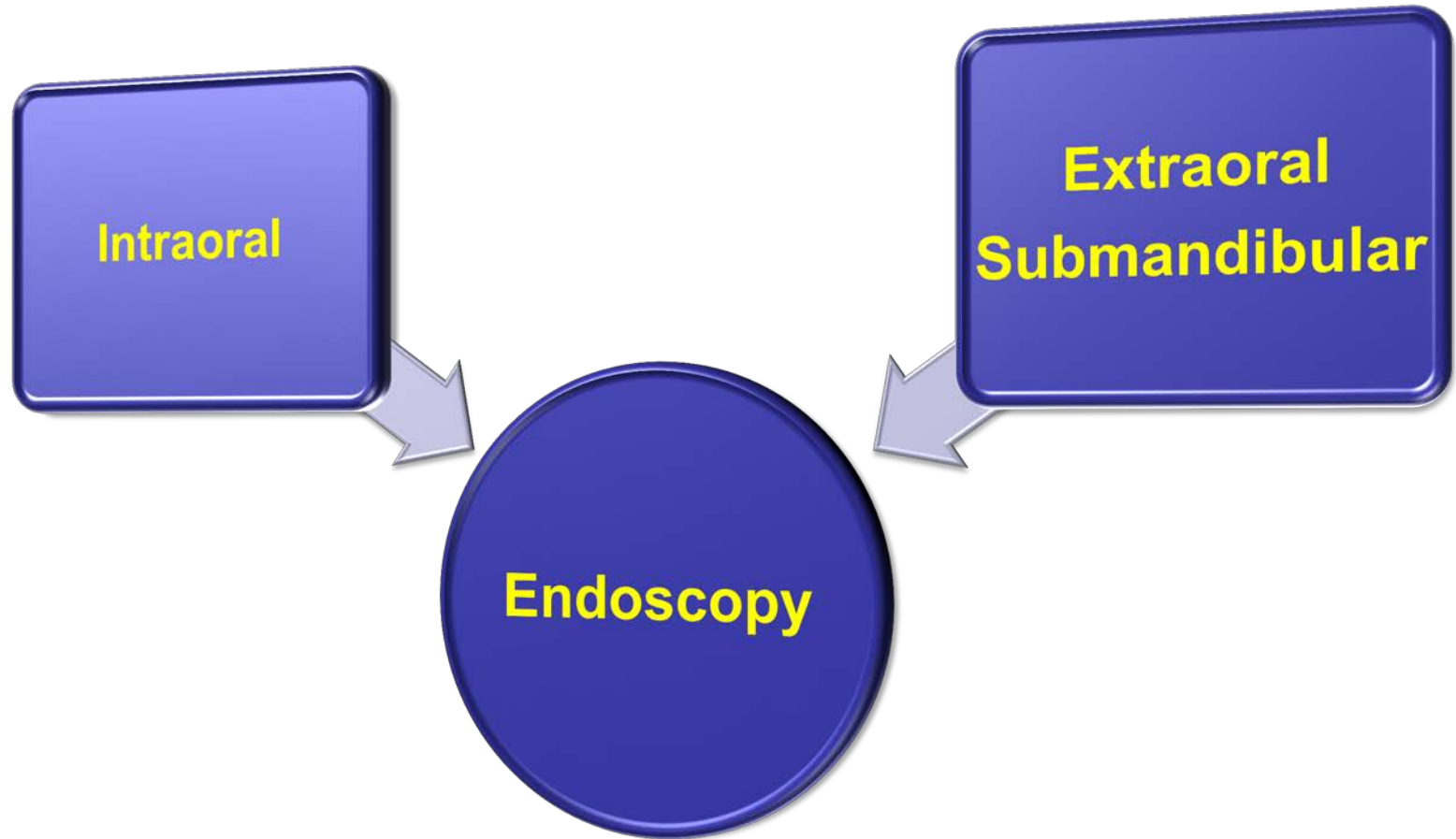




Transbucular Approach

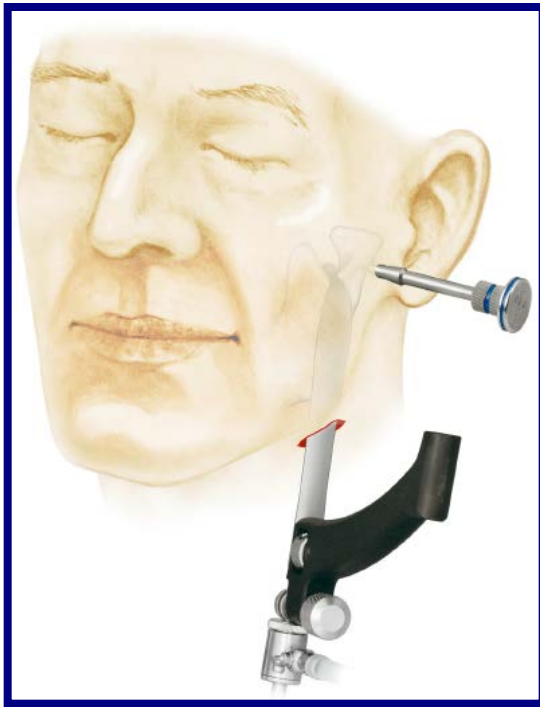




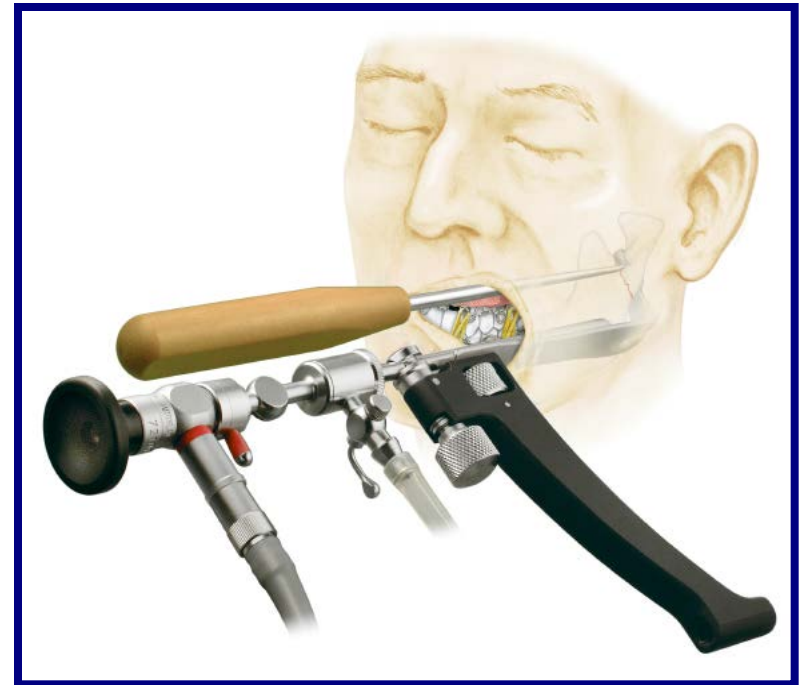

Less Invasive Surgery

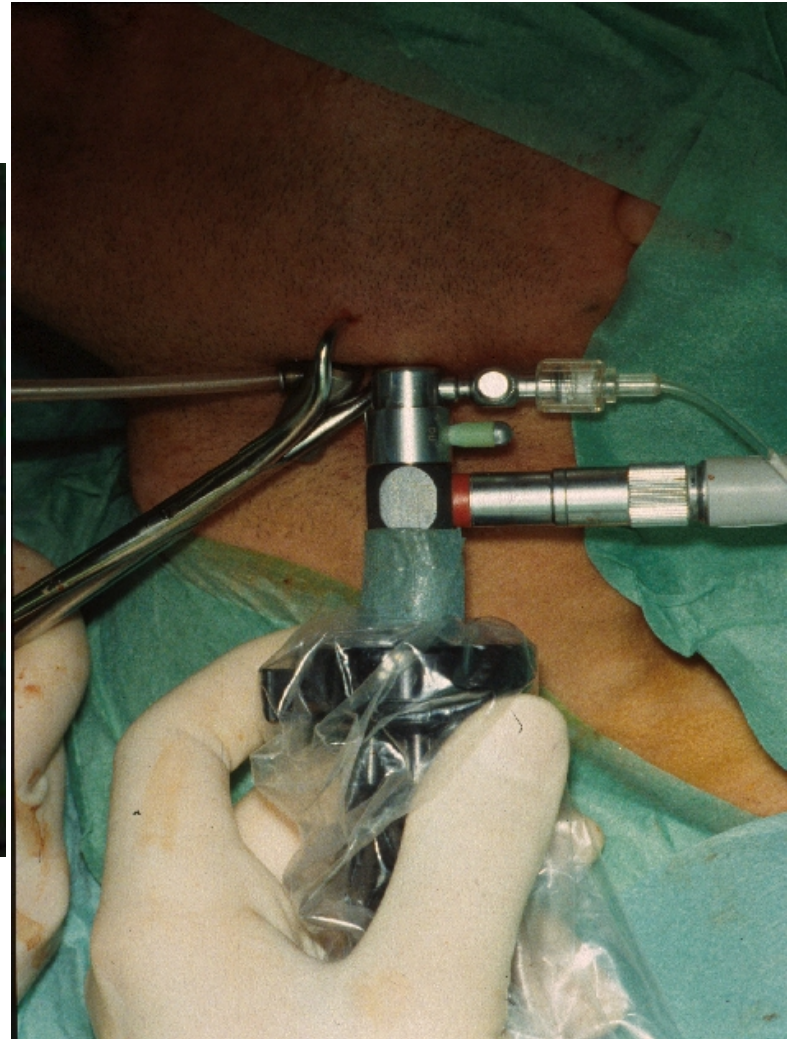
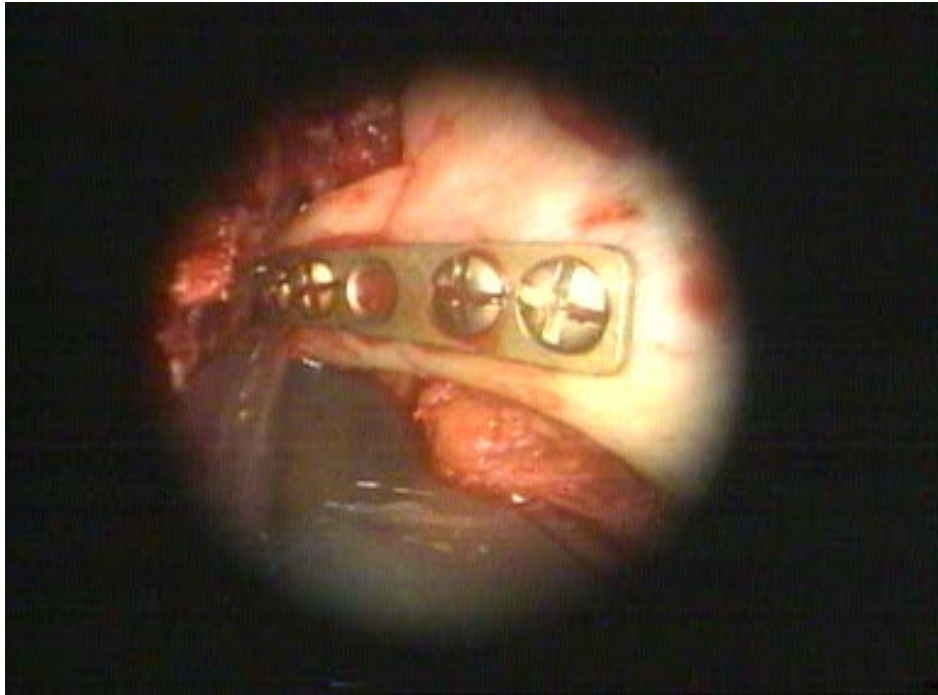
Endoscopic Surgical Approach Options



**Extraoral
Submandibular**



Intraoral



- **What's your treating plan?
which miniplate-screw system?**
 - **Difficult to reposition and fixation?**
 - **Avoid v.&n. damagement**
 - **Good looking**
-

Thanks for your kind attention



Intraoral

Extraoral

Fast exposure

No facial nerve damage

Limited vision

Repositioning

/ Fixation difficult

Severely dislocated

Bilateral fracture

Medial override

Comminution

Risk of Facial Nerve

Damage

Visible Scars