

Case Report

Dentofacial Growth in Patients with Sotos Syndrome

Kunio Takei, Kenji Sueishi, Hideharu Yamaguchi* and Yumi Ohtawa**

Division of Orthodontics, Department of Clinical Oral Health Science, Tokyo Dental College, 2-9-18 Misaki-cho, Chiyoda-ku, Tokyo 101-0061, Japan

** Department of Orthodontics, Tokyo Dental College, 1-2-2 Masago, Mihama-ku, Chiba 261-8502, Japan*

*** Division of Pediatrics, Department of Clinical Oral Health Science, Tokyo Dental College, 2-9-18 Misaki-cho, Chiyoda-ku, Tokyo 101-0061, Japan*

Received 5 March, 2007/Accepted for publication 18 May, 2007

Abstract

Sotos syndrome is an overgrowth syndrome leading to peculiar facial characteristics, large hands and feet, and mental retardation. The maxillofacial characteristics are metopic protrusion, a high and narrow palate and a tapered mandible. In this study, we evaluated changes in maxillofacial growth in 2 patients with cerebral gigantism during the peripubertal period.

Patient 1 was a boy aged 8 years at the first examination. The face showed midface retraction and a tapered mandible.

Maxillary median diastema with an OJ of 2.5 mm and OB of 1.0 mm was observed, and the molar region showed mandibular mesial occlusion. Radiography revealed a lack of 15, 25, 37, 47, 14, 24, 34 and 44. Cephalometrics demonstrated maxillary and mandibular retrusion with an SNA of 68° and an SNB of 70°, and the patient had leptoprosopia with a mandibular plane of 38.0°. This plane was 45° at the time of re-examination when the patient was 14 years old, showing an increase in the lower facial height and decreases in facial axis and depth. Patient 2 was a boy aged 14 years at the first examination. The face showed mandibular retrusion and tapering. The occlusion was angle class II div. 1, OJ 14 mm, and OB –1 mm. Cephalometrics demonstrated maxillary and mandibular retrusion with an SNA of 74.5° and an SNB of 69.5°, and the patient had leptoprosopia with a mandibular plane of 37.0°. At the time of re-examination, when the patient was 16 years old, the mandibular plane was 42.5°, showing an increase in lower facial height and decreases in facial axis and depth.

In this syndrome, excessive facial height without mandibular forward overgrowth is observed. Since the facial height tended to increase by growth during the peripubertal period, maxillofacial vertical growth is considered important in the treatment of this syndrome.

Key words: Sotos syndrome—Cephalometrical radiographs—Vertical growth pattern

Objectives

Cerebral gigantism (Sotos syndrome), showing heavy body weight at birth and excessive

growth over 4 years after birth, is an overgrowth syndrome²⁾ characterized by bone age acceleration, specific facial characteristics such as mandibular prognathism, large hands

and feet, valgus and mental retardation, and was first reported in 1964 by Sotos *et al.*⁷⁾. The maxillofacial characteristics are megacephaly, dolichocephalia, metopic protrusion, anterior fontanel dilation, strabismus, ocular hypertelorism, a high and narrow palate, a tapered mandible, and early eruption of

teeth⁶⁾. There have been studies on maxillofacial growth and pronunciation in infants with this syndrome⁴⁾, but no studies during the peripubertal period were found. In this study, we evaluated changes in maxillofacial growth in 2 patients with cerebral gigantism during the peripubertal period.

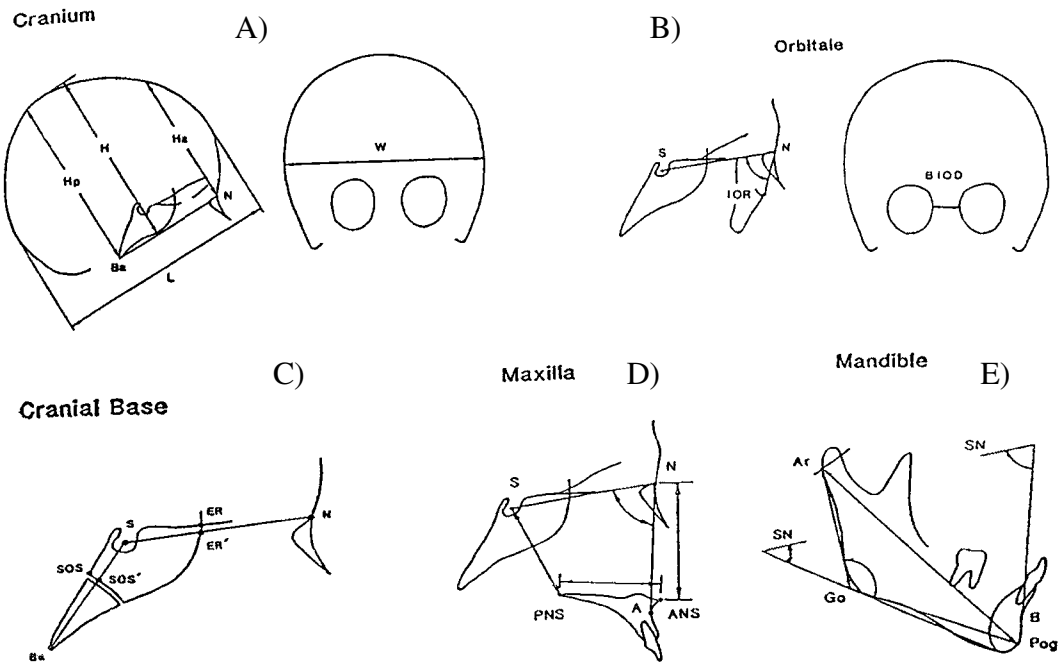


Fig. 1 Morphological analysis of maxillofacial skull (Susami *et al.*⁸⁾)

- A) Calvarial region: H, maximal cranial height; L, maximal cranial major diameter; Ha, anterior cranial height in N region; Hp, posterior cranial height in Ba region; W, maximal cranial width; Cranial indices, H/L , H/W , W/L , Hp/Ha ; Cranial capacity index, $H + L + W/3$.
- B) Basicranial region: S-N, cranial major diameter; S-Ba, major diameter of posterior skull; S-ER', sphenoidal major diameter in anterior skull base; S-SOS', sphenoidal major diameter in posterior skull base; NSBa, basicranial angle; S-ER'/S-N, sphenoidal ratio in anterior skull base; S-SOS'/S-Ba, sphenoidal ratio posterior skull base; S-Ba/S-N, anteroposterior ratio in skull base.
- C) Maxillary region: N-ANS, anterior maxillary height; S-PNS, posterior maxillary height; ANS-PNS, anteroposterior major diameter in upper jaw; S-PNS/N-ANS, anteroposterior ratio of maxillary height.
- D) SN-IOR, protrusion of orbital anterior margin; BIOD, interorbital bone distance; BIOD/W, ratio of interorbital bone distance to cranial width.
- E) Ar-Go, mandibular ramus height; Go-Pog, mandibular corpus length; Ar-Pog, mandibular length; Ar-Go/Go-Pog, ratio of mandibular ramus height to mandibular corpus length.
- A) Shows diagram of how evaluation was performed for length of skull, width, diameter, and ratio according to radiography of profile and frontal image.
- B) Shows diagram of how evaluation was performed for length of base of skull, and ratio according to radiography of profile.
- C) Shows diagram of how evaluation was performed for maxillary positional relationship according to radiography of profile.
- D) Shows diagram of how evaluation was performed for length of eye socket, and positional relationship according to radiography of profile and frontal image.
- E) Shows diagram of how evaluation was performed for length of maxillary bone, and positional relationship according to radiography of profile.

Case Report

This study was performed using frontal and lateral cephalometrical radiographs taken at the first examination and re-examination in 2 patients with Sotos syndrome who consulted the Orthodontic Department of Suidobashi Hospital, Tokyo Dental College. Ricketts analysis, Downs & Northwestern analysis, and analysis of maxillofacial skull morphology by Susami *et al.*⁸⁾ (Fig. 1) were used to evaluate the radiographs.

Patient 1 was a boy aged 8 years 6 months at the first examination. His height was 142.2 cm, body weight 37 kg, and bone age⁵⁾ 11.0 years. The patient consulted our hospital with chiefly for median diastema and a lack of teeth. The face was symmetric, with midface retraction and a tapered mandible (Fig. 2). In the oral cavity, maxillary median diastema with an OJ of 2.5 mm and OB of 1.0 mm was observed, and the molar region was angle II. Eruption of the first maxillary

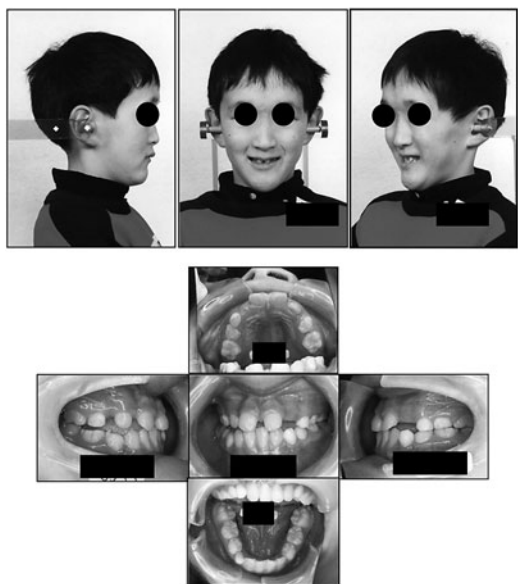


Fig. 2 Patient 1: First examination

Face was symmetric with midface retraction and tapered mandible. In oral cavity, maxillary median diastema with OJ of 2.5 mm and OB of 1.0 mm was observed, and molar region was angle II. Eruption of first maxillary molar was delayed.

molar was delayed (Fig. 2). Radiography revealed a lack of bilateral second premolars and molars in the lower jaw and bilateral first premolars in the upper and lower jaws.

Ricketts analysis of the profile obtained by radiographic cephalometry (Tables 1-1, 1-2, and 1-3) demonstrated that convexity (-4.5°) was small, showing mandibular prognathism, and the facial axis (82.0°), facial depth (83.0°), mandibular plane (37.5°), and lower facial height (51.0°) were large, revealing a dolichofacial pattern.

Downs & Northwestern analysis indicated that the SNA (68°) and SNB (70°) were small, showing maxillary and mandibular retrusion. It was also noted that the mandibular plane (38.0°) and gonial angle (133.5°) were large, and that the ramus angle (80°) was small, showing a high angle.

Analysis by the method of Susami *et al.*⁸⁾ demonstrated that, in the calvarial region, maximal cranial height (H, 160 mm), maximal cranial major diameter (L, 216 mm), posterior cranial height in the Ba region (Hp, 158.5 mm), and cranial capacity index ($H+L+W/3$, 181) were large, revealing megacephaly and leptoprosopia. In the basi-cranial region, the major diameter (S-N, 76 mm) was long, showing leptoprosopia. Anterior maxillary height (N-ANS, 61 mm) was large in the maxillary profile, and inter-orbital bone distance (BIOD, 26.5 mm) was also large on the frontal maxillary image. In the mandibular profile, the mandibular corpus length (Go-Pog, 75.5 mm) and mandibular length (Ar-Pog, 109 mm) were large, showing a high angle.

At the time of re-examination (Figs. 3 and 4, Tables 1-1, 1-2, and 1-3), the patient was 14 years 6 months old.

Ricketts analysis demonstrated that the facial axis and depth had decreased to 80° and 82° , respectively, and that the mandibular plane and lower facial height had markedly increased to 40° and 53° , respectively, revealing an increase in the dolichofacial pattern.

Downs & Northwestern analysis indicated that the gonial angle had increased to 136° , showing an increase in the high angle.

Table 1-1 Ricketts 10 factor analysis

	Clinical norm	8y6m	Clinical norm	14y6m
Facial axis	86	82	86	80
Facial depth	85.5	83	88.5	82
Mandibular plane	30.2	37.5	29	38
Lower facial height	49	51	49	53
Mandibular arc	30.2	21	26.4	23.5
Convexity	3.2	-4.5	2	-4.5
L1 to APO (distance)	3	2	3	1.5
L1 to APO (degree)	25	23	25	25
Upper molar to PTV	10	12	16	14
Lower lip E-plane	2	-3.5	2	-2
Cranial deflection	28	29	28	29
Cranial length	54.2	64.5	59	66.5
Facial height	55.3	69	65.5	78
Ramus position	75	73	75	75
Porion location	-38.5	-45	-41.5	-43
Corpus length	61.5	66.5	70.5	72
	Clinical norm	8y6m	Clinical norm	14y6m
Molar relation right	1.5	0.5	1.5	0
Molar relation left	1.5	-1	1.5	0
Intermolar width	57	59	57	59
Inter canine width	23	24	23	29.5
Denture midline	0	6	0	6
Max-Mand width left	-11	-12	-11	-15.5
Max-Mand width right	-11	-14	-11	-15
Max-Mand width midline (DEG)	0	1.5	0	1
Molar to jaw left (Mand)	6.7	7	6.7	10
Molar to jaw right (Mand)	6.7	3	6.7	5
Denture-jaw midline	0	4	0	5
Occlusal plane tilt	0	0.5	0	-2.3
Postural symmetry (DEG)	0	2	0	2
Nasal width	27	27	31.2	29
Nasal height	46	51	52	56
Max. width	63	57.5	67.2	62
Mand. width	82	81	89.8	88
Facial width	124	132	137.2	144

Ricketts analysis demonstrated that the facial axis and depth had decreased to 80° and 82°, respectively, and that mandibular plane and lower facial height markedly increased to 40° and 53°, respectively, revealing increase in dolichofacial pattern.

Table 1-2 Downs & Northwestern analysis

	Clinical norm	8y6m	14y6m
Facial angle	86.1	82	75
Convexity	6.4	9	7.3
A-B plane	-5.2	-2	-1
Mandibular plane	24.8	38	45
Y-axis	64	68.3	75
Occlusal plane	8.4	20	30.5
Interincisal	131.6	136	133
L-1 to occlusal	21.3	4	4.8
L-1 to mandibular	97.1	77	80
U-1 to A-P plane	7.8	4	6
F-H to SN plane	5.4	10	3.2
SNA	83.4	68	69.5
SNB	80	70	70.5
ANB	3.4	-2	-1
U-1 to FH plane	110.8	109	101
L-1 to FH plane	61.6	65	55
Gonial angle	117.5	133.5	136
Ramus angle	88.5	80	88.5

Downs & Northwestern analysis indicated that gonial angle had increased to 136°, showing increase in high angle.

Table 1-3 Susami *et al.* analysis

	Clinical norm	8y6m	Clinical norm	14y6m
A) Calvarial region				
Profile a standard on N-Ba plane				
H; Maximal cranial height	150.1	160	156.1	161
L; Maximal cranial major diameter	187.6	216	195.7	220.5
Ha; Anterior cranial height in the N region	109.4	116	105.1	112
HP; Posterior cranial height in the Ba region	146.6	158.5	149.6	159
Frontal image				
W; Maximal cranial width	164.3	167	168.3	169
Cranial indices				
H/L	0.81	0.741	0.8	0.73
H/W	0.91	0.958	0.93	0.953
W/L	0.88	0.773	0.86	0.766
Hp/Ha	1.33	1.366	1.43	1.42
Cranial capacity index				
H+L+W/3	167.3	181	173.4	183.5
B) Basicranial region				
Profile				
S-N; Cranial major diameter	64.8	76	72.9	79
S-Ba; Major diameter of the posterior skull	44	43	52.3	45
S-ER'; Sphenoidal major diameter in the anterior skull base	28.2	32	29.7	32.5
SSOS'; Sphenoidal major diameter in the posterior skull base	15.7	17	21.1	18.5
NSBa; Basicranial angle	131.1	130	129	129
S-ER'/S-N; Sphenoidal ratio in the anterior skull base	0.44	0.428	0.41	0.551
SSOS'/S-Ba; Sphenoidal ratio in the posterior skull base	0.36	0.395	0.41	0.411
S-Ba/S-N; Anteroposterior ratio in the skull base	0.68	0.566	0.72	0.57
C) Maxillary region				
Profile				
N-ANS; Anterior maxillary height	49.8	61	61.9	68
S-PNS; Posterior maxillary height	44.2	48	55.6	53.5
ANS-PNS; Anteroposterior major diameter in the upper jaw	47	50	55.5	54.5
SNA	80.4	68	81.8	69
S-PNS/N-ANS; Anteroposterior ratio of the maxillary height	0.89	0.787	0.9	0.787
D) Orbital region				
Profile				
SN-IOR; Protrusion of the orbital anterior margin	65.9	54	68	54
Frontal image				
BIOD; Interorbital bone distance	20.7	26.5	23.7	28
BIOD/W; Ratio of the interorbital bone distance to the cranial width	0.13	0.159	0.14	0.166
E) Mandibular region				
Profile				
Ar-Go; Mandibular ramus height	43.1	43	60	49
Go-Pog; Mandibular corpus length	66.4	75.5	82.6	80
Ar-Pog; Mandibular length	97.1	109	123	117
Gonial angle	128.1	139	123.4	138
Mandibular plane-SN, SNB	76.1	70	79	70
Ar-Go/Go-Pog; Ratio of the mandibular ramus height to the mandibular corpus length	0.65	0.57	0.73	0.613

Analysis by method of Susami *et al.* demonstrated that maximal cranial major diameter, mandibular ramus height, and cranial capacity index had increased to 220.5mm, 49mm (43mm at first examination), and 183.5, respectively.

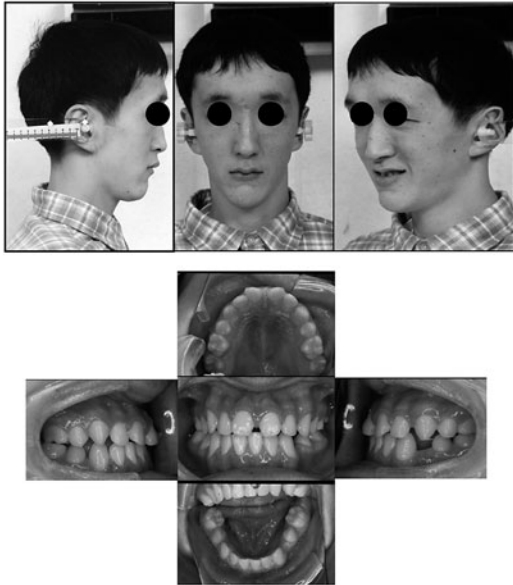


Fig. 3 Patient 1: Re-examination

Countenance: marked growth of face was observed. Oral cavity revealed lack of 15, 25, 37, 47, 14, 24, 34 and 44. Maxillary median diastema was observed, and molar region was angle II.

Analysis by the method of Susami *et al.* demonstrated that the maximal cranial major diameter, mandibular ramus height, and cranial capacity index had increased to 220.5 mm, 49 mm (43 mm at the first examination), and 183.5, respectively.

Figure 4 shows the profile produced by superimposing the profile obtained at the first examination on that obtained at re-examination at the S point on the S-N plane, and the frontal image produced by superimposing the image obtained at the first examination on that obtained at re-examination at Cock's comb on the maxillofacial median. As in this figure, the skull and mandibular bone grew vertically, and a high angle was observed.

Ricketts 5-position analysis (Fig. 5) demonstrated a 2° dilation of the facial axis by the first superimposition, a 1.5-mm retraction of point A by the second superimposition, a 1-mm inclination of the maxillary medial incisor to the lip and a 1-mm mesial movement of the first maxillary molar by the third superimposition, a 2-mm inclination of the mandibular medial incisor to the tongue and a 1-mm mesial movement of the first mandibular molar by the fourth superimposition, and a

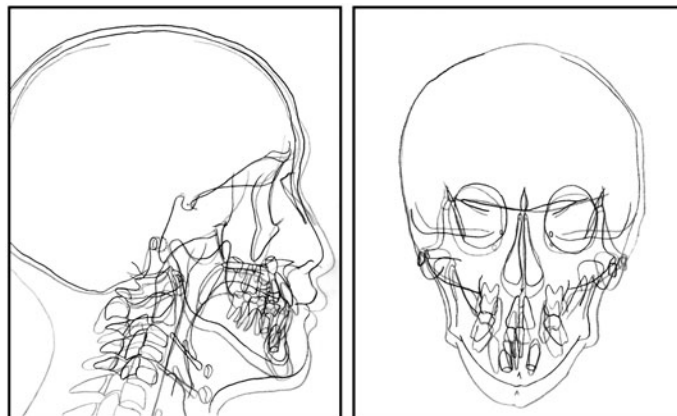


Fig. 4 Patient 1: Superimposition points

————— : Examination - - - - - : Re-examination
 Superimposition points: Profile: S point on the SN plane. Frontal image: Midpoint of Cock's comb on the maxillofacial median.
 In profile, skull and mandibular bone grew vertically, and high angle was observed. In frontal image, facial height had increased.

1.5-mm retraction of the lower lip with respect to the E-line by the fifth superimposition.

Patient 2 was a boy aged 14 years 6 months at the first examination. His height was 174cm, body weight 50.0kg, and bone age 14.8 years. Mental retardation was observed. The patient consulted our hospital chiefly for maxillary anterior tooth protrusion. The face was symmetric, and showed mandibular retrusion and tapering (Fig. 6). The occlusion was angle class II div. 1, OJ 14mm, and OB -1 mm (Fig. 6).

Ricketts 10-factor analysis of the profile obtained by radiographic cephalometrics (Tables 2-1, 2-2, and 2-3) demonstrated that the facial axis (87°), facial depth (83.0°),

mandibular plane (36°), lower facial height (57°), and cranial length (63.5°) were large, showing a high angle. Ricketts analysis of the frontal image demonstrated a small facial width (132°).

Downs & Northwestern analysis indicated that the mandibular plane (37°) and gonial angle (133°) were large, and that the ramus angle (84°), SNA (74.5°), and SNB (69.5°) were small, showing maxillary and mandibular retrusion.

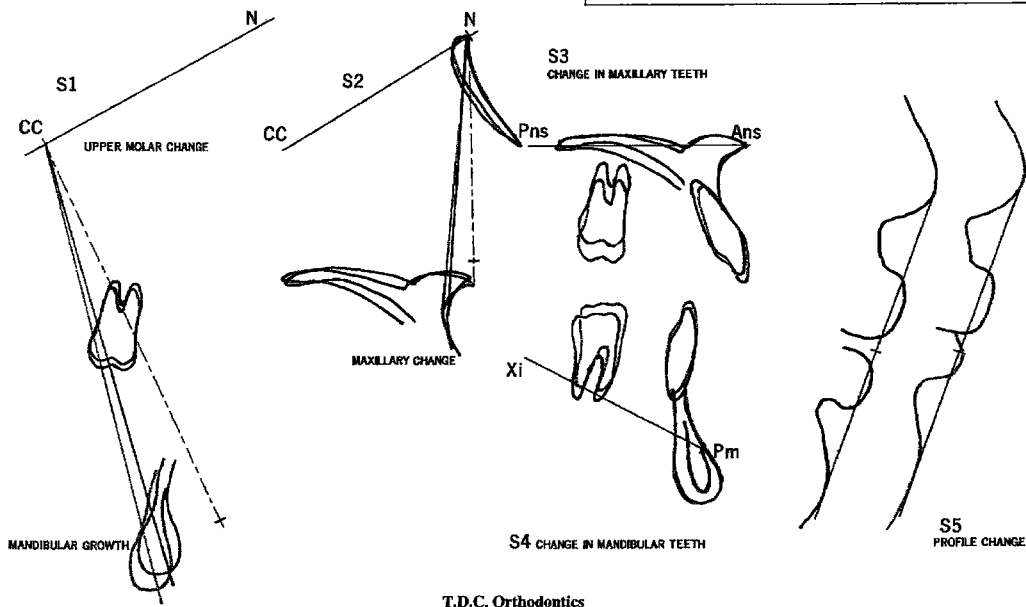
Analysis by the method of Susami *et al.*⁸⁾ demonstrated leptoprosopia, with a maximal cranial height (H) of 151 mm, maximal cranial major diameter (L) of 167 mm, anterior cranial height in the N region (Ha) of

Treatment Results 5 POSITION ANALYSIS

Name: 症例 2
 Pre. :Black 14y6m
 Post. :Red 16y11m

SUMMARY OF TREATMENT RESULTS

- S1 Ex: 2.5° open
- S2 Point A: 1.5° reduction
- S3 U1: 1mm flare
- U6: no change
- S4 L1: no change
- L6: 1mm loss
- S5 Lower Lip: -1mm from Esthetic line



T.D.C. Orthodontics

Fig. 5 Patient 1: 5-positions analysis

Ricketts 5-position analysis demonstrated 2° dilation of facial axis by first superimposition, 1.5-mm retraction of point A by second superimposition, 1-mm inclination of maxillary medial incisor to lip and 1-mm mesial movement of first maxillary molar by third superimposition, 2-mm inclination of mandibular medial incisor to tongue and 1-mm mesial movement of first mandibular molar by fourth superimposition, and 1.5-mm retraction of lower lip with respect to E-line by fifth superimposition.

109.5 mm, and posterior cranial height in the Ba region (Hp) of 143 mm in the calvarial profile, a maximal cranial width (W) of 164.5 mm on the frontal image, and a cranial major diameter (S-N) in the basicranial profile of 70 mm. In the maxillary profile, the anterior maxillary height (N-ANS) was 61.5 mm, posterior maxillary height (S-PNS) 51 mm, and anteroposterior maxillary diameter (ANS-PNS) 48.5 mm, and on the frontal image, the interorbital bone distance (BIOD) was 29.5 mm, showing ocular hypertelorism.

At the time of re-examination, the patient was 16 years 11 months old (Figs. 7 and 8, Tables 2-1, 2-2, and 2-3).

Ricketts 10-factor analysis demonstrated that the facial axis had decreased to 84° , showing a dolichofacial pattern. Ricketts analysis of the frontal image indicated that the maxillary width (63 mm), mandibular width (99 mm), and facial width (144 mm) were large.

Downs & Northwestern analysis revealed

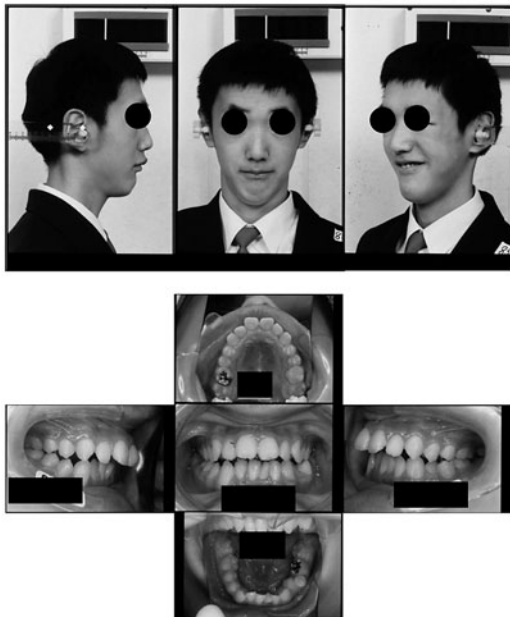


Fig. 6 Patient 2: First examination

Face was symmetric, and showed mandibular retrusion and tapering. Occlusion was angle class II div. 1, OJ 14 mm, and OB - 1 mm.

that the Y-axis was large (72°), revealing an increase in the high angle.

Analysis by the method of Susami *et al.* demonstrated that the maximal cranial major diameter was 185 mm in the calvarial profile, and the sphenoidal major diameter in the anterior skull base (S-ER') was 28.5 mm in the basicranial profile, indicating enhancement of the dolichofacial pattern. In the maxillary profile, the anterior maxillary height (N-ANS), posterior maxillary height (S-PNS), and anteroposterior major diameter in the upper jaw (ANS-PNS) had markedly increased to 63.5 mm, 52.5 mm, and 51 mm, respectively, and in the mandibular profile, the mandibular ramus height (Ar-Go) and mandibular length (Ar-Pog) had also increased to 48.5 mm and 113 mm, respectively, indicating an increase in the high angle.

Figure 8 shows the profile produced by superimposing the profile obtained at the first examination on that obtained at re-examination at the S point on the S-N plane, and the frontal image produced by superimposing the image obtained at the first examination on that obtained at re-examination at Cock's comb on the maxillofacial median. As seen in this figure, the skull and mandibular bone had grown vertically, and a high angle was observed.

Ricketts 5-position analysis (Fig. 9) demonstrated a 2.5° dilation of the facial axis by the first superimposition, a 1.5-mm retraction of point A by the second superimposition, a 1-mm inclination of the maxillary medial incisor to the lip without any movement of the maxillary molars by the third superimposition, a 1-mm mesial movement of the mandibular molars without any movement of the mandibular anterior teeth by the fourth superimposition, and a 1-mm retraction of the lower lip with respect to the E-line by the fifth superimposition.

Discussion

In Sotos syndrome, as in other overgrowth syndromes such as Wiedeman-Beckwith syn-

Table 2-1 Ricketts 10-factor analysis

	Clinical norm	14y6m	Clinical norm	16y11m
Facial axis	86	87	86	84
Facial depth	88.5	83	89.5	81
Mandibular plane	29	36	28.8	41
Lower facial height	49	57	49	61
Mandibular arc	26.4	25	27	29
Convexity	2	3	1.6	3
L1 to APO (distance)	3	-4	3	-3
L1 to APO (degree)	25	11	25	18
Upper molar to PTV	16	13.5	18	15
Lower lip E-plane	2	1.5	2	0.5
Cranial deflection	28	30	28	30
Cranial length	59	63.5	60.6	65
Facial height	65.5	65	67.9	67
Ramus position	75	64	75	73
Porion location	-41.5	-41	-42.5	-39.5
Corpus length	70.5	68.5	73.5	68.7
	Clinical norm	14y6m	Clinical norm	16y11m
Molar relation right	1.5	-1	1.5	-1
Molar relation left	1.5	2.5	1.5	1
Intermolar width	57	56.5	57	56.5
Inter canine width	23	27.5	23	27
Denture midline	0	1	0	2
Max-Mand width left	-11	-18	-11	-20
Max-Mand width right	-11	-20	-11	-19
Max-Mand width midline (DEG)	0	1	0	3
Molar to jaw left (Mand)	6.7	9.5	6.7	11
Molar to jaw right (Mand)	6.7	11	6.7	13.5
Denture-jaw midline	0	1.5	0	2.5
Occlusal plane tilt	0	2	0	0
Postural symmetry (DEG)	0	0	0	0.5
Nasal width	31.2	31	32.6	31
Nasal height	52	55	54	55
Max. width	67.2	61	68.6	63
Mand. width	89.8	96	92.4	99
Facial width	137.2	140	141.6	144

Ricketts 10-factor analysis demonstrated that facial axis had decreased to 84°, showing dolichofacial pattern. Ricketts analysis of frontal image indicated that maxillary width (63mm), mandibular width (99mm), and facial width (144mm) were large.

Table 2-2 Downs & Northwestern analysis

	Clinical norm	14y6m	16y11m
Facial angle	86.1	83	80
Convexity	6.4	5	6
A-B plane	-5.2	-10	-9
Mandibular plane	24.8	37	42.5
Y-axis	64	67.5	72
Occlusal plane	8.4	11.5	15
Interincisal	131.6	128	126
L-1 to occlusal	21.3	11	4
L-1 to mandibular	97.1	76	80
U-1 to A-P plane	7.8	9.5	11
FH to SN plane	5.4	11.8	9
SNA	83.4	74.5	73.5
SNB	80	69.5	68.5
ANB	3.4	5	5
U-1 to FH plane	110.8	119	118
L-1 to FH plane	61.6	67	57.5
Gonial angle	117.5	133	137.5
Ramus angle	88.5	84	85

Downs & Northwestern analysis revealed that Y-axis was large (72°), revealing increase in high angle.

Table 2-3 Susami *et al.* analysis

	Clinical norm	14y6m	16y11m
A) Calvarial region			
Profile a standard on N-Ba plane			
H; Maximal cranial height	156.1	151	153.5
L; Maximal cranial major diameter	195.7	167	185
Ha; Anterior cranial height in the N region	105.1	109.5	111.5
HP; Posterior cranial height in the Ba region	149.6	143	143
Frontal image			
W; Maximal cranial width	168.3	164.5	163.5
Cranial indices			
H/L	0.8	0.904	0.83
H/W	0.93	0.918	0.939
W/L	0.86	0.985	0.884
Hp/Ha	1.43	1.306	1.283
Cranial capacity indexes			
H + L + W/3	173.4	160.83	167.3
B) Basicranial region			
Profile			
S-N; Cranial major diameter	72.9	70	71.5
S-Ba; Major diameter of the posterior skull	52.3	49	50
S-ER'; Sphenoidal major diameter in the anterior skull base	29.7	27	28.5
S-SOS'; Sphenoidal major diameter in the posterior skull base	21.1	25	26.5
NSBa; Basicranial angle	129	136	133
S-ER'/S-N; Sphenoidal ratio in the anterior skull base	0.41	0.386	0.4
S-SOS'/S-Ba; Sphenoidal ratio in the posterior skull base	0.41	0.51	0.53
S-Ba/S-N; Anteroposterior ratio in the skull base	0.72	0.7	0.699
C) Maxillary region			
Profile			
N-ANS; Anterior maxillary height	61.9	61.5	63.5
S-PNS; Posterior maxillary height	55.6	51	52.5
ANS-PNS; Anteroposterior major diameter in the upper jaw	55.5	48.5	51
SNA	81.8	73	73
S-PNS/N-ANS; Anteroposterior ratio of the maxillary height	0.9	0.829	0.827
D) Orbital region			
Profile			
SN-IOR; Protrusion of the orbital anterior margin	68	56	55.5
Frontal image			
BIOD; Interorbital bone distance	23.7	29.5	29.5
BIOD/W; Ratio of the interorbital bone distance to the cranial width	0.14	0.179	0.18
E) Mandibular region			
Profile			
Ar-Go; Mandibular ramus height	60	44.5	48.5
Go-Pog; Mandibular corpus length	82.6	77	76.5
Ar-Pog; Mandibular length	123	110.5	113
Gonial angle	123.4	132	137
Mandibular plane-SN, SNB	79	68	67.5
Ar-Go/Go-Pog; Ratio of the mandibular ramus height to the mandibular corpus length	0.73	0.571	0.642

Analysis by method of Susami *et al.* demonstrated that maximal cranial major diameter was 185 mm in calvarial profile, and sphenoidal major diameter in anterior skull base (S-ER') was 28.5 mm in basicranial profile, indicating enhancement of dolichofacial pattern. In maxillary profile, anterior maxillary height (N-ANS), posterior maxillary height (S-PNS), and anteroposterior major diameter in upper jaw (ANS-PNS) had markedly increased to 63.5 mm, 52.5 mm, and 51 mm, respectively, and in mandibular profile, mandibular ramus height (Ar-Go) and mandibular length (Ar-Pog) had also increased to 48.5 mm and 113 mm, respectively, indicating increase in high angle.

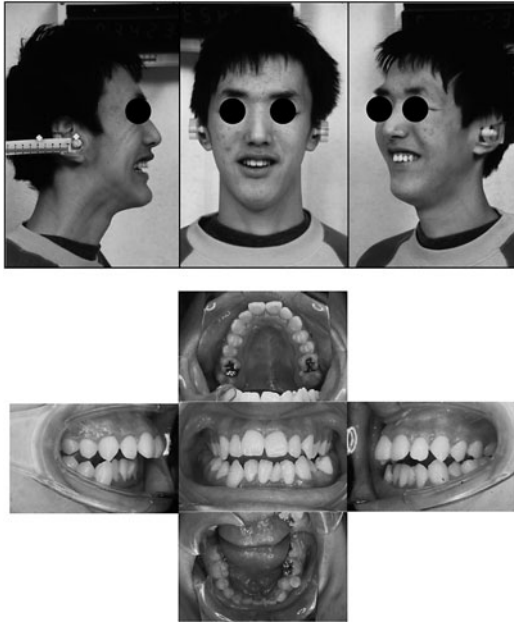


Fig. 7 Patient 2: Re-examination
 Countenance: growth of face was observed. In oral cavity, occlusion was angle class II div. 1.

drome³⁾, maxillary and mandibular retrusion and excessive facial height without mandibular forward overgrowth are observed. Morphologically, the maximal cranial major diameter and anterior maxillary height are markedly larger in this syndrome than in Apert's syndrome or Crouzon's disease⁵⁾, indicating the characteristics of megacephaly.

Motohashi *et al.*⁴⁾ performed a cross-sectional analysis of the morphology in infants with Sotos syndrome using Bolton standards. The subjects consisted of 4 patients: 3 boys aged 2 years 3 months, 3 years 1 month, and 5 years 8 months, and 1 girl aged 2 years 9 months. The cranial length, height, and width, maxillary and mandibular lengths, mandibular angle, and interorbital distance were measured on lateral and frontal cephalometrical radiographs, and slight maxillary and mandibular retrusion, a large gonial angle, increases in the N-S-Gn angle in the mental region, increases in the Ar-Go-Gn angle, and slight increases in the facial height were detected.

Welbury and Fletcher⁹⁾ reported an 11-year-old female and a 16-year-old male with Sotos syndrome, and noted their values by cephalometric analysis. Anterior cranial base (Sella-

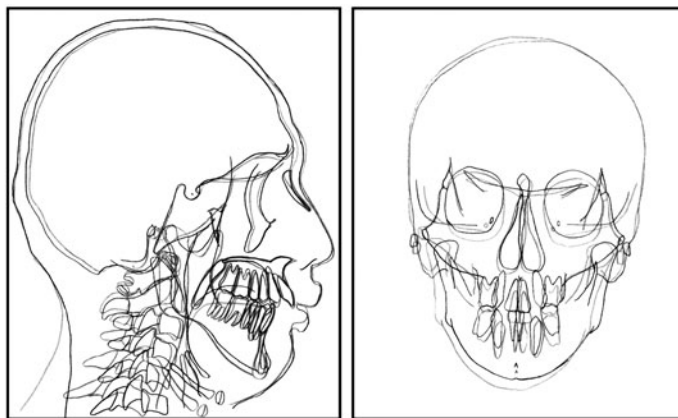


Fig. 8 Patient 2: Superimposition points
 — : Examination - - - : Re-examination
 Superimposition points: Profile: S point on SN plane. Frontal image: Midpoint of Cock's comb on maxillofacial median.
 In profile, the skull and mandibular bone grew vertically, and high angle was observed. In frontal image, maxillary width, mandibular width and facial width had increased.

Nasion) exceeded the norm in one patient, SNA was decreased, and SNPog was average or small. Mandibular body length (Go-Pog) was large and Gonial angle was average or small.

Our patients had a large anterior cranial base and exhibited dolichocephaly, and small SNA and SNB values.

Allanson and Cole¹⁾ reported growth changes in facial appearance using anthropometric craniofacial measurements. With time, the normal process of facial change occurs. They superimposed their results on this normal Gestalt. The results, it's shamed that, as the face lengthened, the dominance of the forehead diminished and the chin achieved greater prominence. The mandible became

longer and more narrow inferiorly, square or pointed, but prognathism was rare.

In the present study, we performed longitudinal analysis of the morphology in adolescent patients with Sotos syndrome, and found that the vertical development of the maxillofacial plane observed in the infants continued. To treat disordered occlusion in Sotos syndrome, it is considered important to suppress the growth of facial height.

Conclusions

To evaluate morphological changes in growth in patients with cerebral gigantism, we examined the maxillofacial growth pattern in

Treatment Results 5 POSITION ANALYSIS

Name: 症例 1
 Pre. :Black 8y6m
 Post. :Red 14y6m

SUMMARY OF TREATMENT RESULTS

- S1 Fx: 2° open
- S2 Point A: 1.5° reduction
- S3 U1: 1mm flare
- U6: 1mm loss
- S4 L1: 2mm retraction
- L6: 1mm loss
- S5 Lower Lip: 1.5mm from Esthetic line

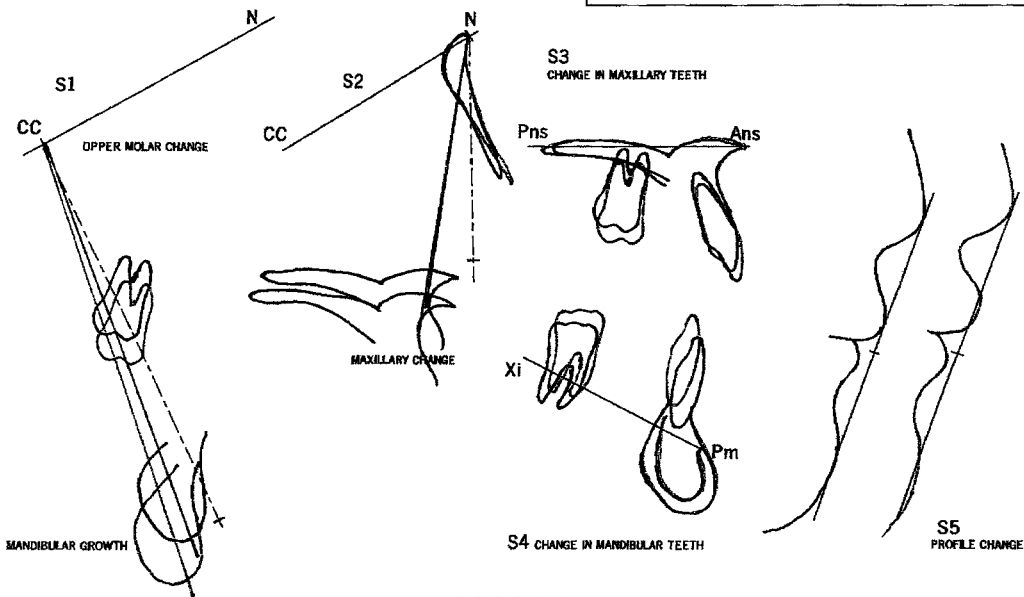


Fig. 9 Patient 2: 5-position analysis

Ricketts 5-position analysis demonstrated 2.5° dilation of facial axis by first superimposition, 1.5-mm retraction of point A by second superimposition, 1-mm inclination of maxillary medial incisor to lip without any movement of maxillary molars by third superimposition, 1-mm mesial movement of mandibular molars without any movement of mandibular anterior teeth by fourth superimposition, and 1-mm retraction of lower lip with respect to E-line by fifth superimposition.

early teens using cephalometrical radiographs of 2 patients who had consulted the Orthodontic Department of Suidobashi Hospital. (Patient 1 was 8 years 6 months old at the first examination and 14 years 6 months old at re-examination, and patient 2 was 14 years 6 months and 16 years 11 months old, respectively.) Ricketts and Downs & Northwestern analyses and analysis by the method of Susami *et al.* were performed using radiographs of the 2 patients.

In both patients, vertical growth of the maxillofacial plane was noted, and in patient 2, it was markedly enlarged.

The results showed that facial height increased in the patients, with cerebral gigantism occurring during the peripubertal period, together with changes in vertical growth. This suggests that these are important factors for orthodontic treatment.

References

- 1) Allanson JE, Cole TR (1988) Sotos syndrome: evolution of facial phenotype subjective and objective assessment. *Am J Med Genet* 79: 229–230.
- 2) Gorlin RJ, Cohen MM, Hennekam RCM (2001) *Syndromes of the Head and Neck*, 4th ed., pp. 408–409, Oxford University Press, New York.
- 3) Masubuchi M, Sueishi K, Sakamoto T, Negishi F, Yamaguchi H (2006) Orthodontic evaluation of eight case in Beckwith-Wiedemann syndrome. *Orthodontic Waves* 65:9–14.
- 4) Motohashi N, Pruzansky S, Kawata T (1981) Roentgencephalometric analysis of cerebral gigantism: Report of four patients. *J Craniofac Genet Dev Biol* 1:73–94.
- 5) Nakazawa O (1959) A method of assessing the skeletal age. *Orthopaedic Sci* 33:839–863.
- 6) Naritomi K (2001) Cerebral gigantism, *Nippon Rinsho Suppl Ryoikibetsu Shokogun Shirizu No.33 of Moformation Syndrome Dictionary*, pp.350–353. (in Japanese)
- 7) Sotos JF, Dodge PR, Muirhead D, Crawford J, Dtalbot NB (1964) Cerebral gigantism in childhood: A syndrome of excessively rapid growth with acromelic features and a non-progressive neurologic disorder. *N Engl J Med* 271:109–116.
- 8) Susami T, Terashima T, Lin T, Motohashi N, Kuroda T (1986) Morphological evaluation on craniofacial dysmorphology of Apert's syndrome and Crouzon disease. *Jpn Orthodo Soc* 45:674–686. (in Japanese)
- 9) Welbury RR, Fletcher HJ (1988) Cerebral gigantism (Sotos syndrome) — two case reports. *J Paediatr Dent* 4:41–44.

Reprint requests to:

Dr. Kunio Takei
 Division of Orthodontics,
 Department of Clinical Oral
 Health Science,
 Tokyo Dental College,
 2-9-18 Misaki-sho, Chiyoda-ku,
 Tokyo 101-0061, Japan