

Original Article

Tooth Axis and Skeletal Structures in Mandibular Molar Vertical Sections in Jaw Deformity with Facial Asymmetry using MPR Images

**Kunihiko Nojima, Taishi Yokose, Takenobu Ishii,
Makoto Kobayashi and Yasushi Nishii**

*Department of Orthodontics, Tokyo Dental College,
1-2-2 Masago, Mihama-ku, Chiba 261-8502, Japan*

Received 11 July 2007/Accepted for publication 18 September, 2007

Abstract

The objective of the present study was to investigate frontal morphological asymmetry in the mandibular molar region in terms of tooth axis and skeletal structures using vertical MPR sections in jaw deformity accompanied by facial asymmetry. Subjects consisted of 15 patients with jaw deformity accompanied by facial asymmetry aged 17.4 years to 37.8 years. There were four men and eleven women. Based on X-ray computed tomography (CT) scans, DICOM viewer software was used to prepare multiplanar reconstruction (MPR) sections. The mandible was then positioned on a reference plane based on the menton and left and right gonions, and a vertical MPR section passing through the mesial root of the first mandibular molar was prepared. The following measurements were made on both the shifted and non-shifted sides: maximum buccolingual width of the mandibular body; height of the mandibular body; inclination angle of the mandibular body; degree of buccal protrusion of the mandibular body; and inclination angle of the buccolingual tooth axis of the first molar. Furthermore, degree of median deviation in the menton was measured using frontal cephalograms. Differences in morphological parameters between the shifted and non-shifted sides were assessed. Furthermore, the relationship between median deviation and asymmetry were statistically analyzed. There was no significant asymmetry in the maximum buccolingual width of the mandibular body, the height of the mandibular body or the degree of buccal protrusion of the mandibular body. However, when compared to the shifted side, the inclination angle of the buccolingual tooth axis of the first molar for the non-shifted side was significantly greater. There was a relatively strong correlation between median deviation and inclination angle of the mandibular body.

The above findings clarified that, in orthognathic surgery for jaw deformity accompanied by facial asymmetry, actively improving asymmetry in the buccolingual inclination of the tooth axis of the molar region during presurgical orthodontic treatment is important in achieving favorable post-treatment occlusal stability and facial symmetry.

Key words: Jaw deformity—Facial asymmetry—X-ray CT—
Mandibular vertical section—Bucco-lingual inclination

Introduction

Jaw deformity patients often wish to improve not only physiological functions such as occlusion, articulation and mastication, but also facial esthetics¹¹⁾. However, in patients with jaw deformities accompanied by facial asymmetry, satisfactory facial symmetry cannot be achieved in some cases, even when properly reconstructing occlusion and matching the center of the maxillary and mandibular dentitions to the facial midline following orthognathic surgery. Clinical studies have reported similar cases^{4,6)}. The reasons for this may include asymmetry in the frontal morphology of the mandibular body; asymmetry in the buccolingual inclination of the molar region; improper positioning of the mandible due to tilt of the occlusal plane in relation to the frontal plane; and asymmetry in soft tissue volume, including muscle tissue. Dental compensation is often seen in the anterior tooth region of patients with skeletal mandibular protrusion, and in patients with facial asymmetry, dental compensation in the molar region does not allow the midline of the mandible to be in a symmetric position. Dental plaster models have been used to investigate the buccolingual inclination of the maxillary and mandibular first molar in facial asymmetry patients^{5,14)} and to assess changes in the buccolingual inclination of the molar region before and after orthognathic surgical treatment in jaw deformity patients^{10,13)}. However, to the best of our knowledge, there have been no reports on buccolingual inclination of the molar region, including the frontal morphology of the mandibular body, in patients with facial asymmetry.

In this study, vertical multiplanar reconstruction (MPR) sections prepared from X-ray computed tomography (CT) scans were examined to clarify asymmetry in the buccolingual tooth axis of molars and the frontal-plane skeletal morphology of the mandible in jaw deformity complicated by facial asymmetry.

Materials and Methods

Subjects consisted of 15 patients with jaw deformities accompanied by facial asymmetry who visited the Orthodontics Department of Tokyo Dental College. There were four men and eleven women of ages ranging from 17.4 to 37.8 years (mean age, 20.6 years). X-ray CT was performed for diagnostic purposes and for planning orthognathic surgery. X-ray CT scans were saved as DICOM files on a photomagnetic disc and uploaded to an IBM/PC AT compatible computer. Using DICOM viewer software (ExaVision Lite, Ziosoft Inc., Tokyo), MPR images were prepared. The same software was used to position the mandible on a reference plane based on the menton and left and right gonions. A vertical MPR section passing through the mesial root of the mandibular first molar perpendicular to the molar dentition was prepared (Figs. 1, 2).

The following parameters were measured on the shifted and non-shifted sides (Fig. 3).

1. Maximum buccolingual width of the mandibular body: maximum buccolingual width parallel to the mandibular basal line.
2. Height of the mandibular body: distance between the buccal alveolar ridge and the lowest point of the mandible.
3. Inclination angle of the mandibular body: angle formed by the mandibular basal line and the line connecting the lowest point of the mandible and the midpoint of the buccolingual alveolar process peaks.
4. Buccal protrusion of the mandibular body: distance from the widest buccolingual contour to the line connecting the lowest point of the mandible and the buccal alveolar ridge.
5. Inclination angle of the buccolingual tooth axis of the first molar: angle formed by the mandibular basal line and the line connecting the midpoint of the buccolingual diameter at the crown and that at one third the root apex.

The mean and standard deviations were calculated for each parameter. Comparisons between the shifted and non-shifted sides

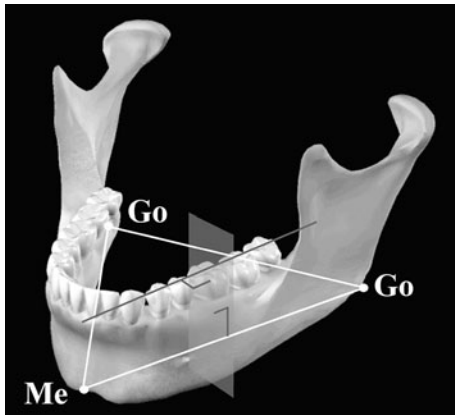


Fig. 1 Reference and frontal planes

Mandible was positioned on reference plane based on menton and left and right gonions. Vertical section passing through mesial root of mandibular first molar perpendicular to molar dentition was prepared.

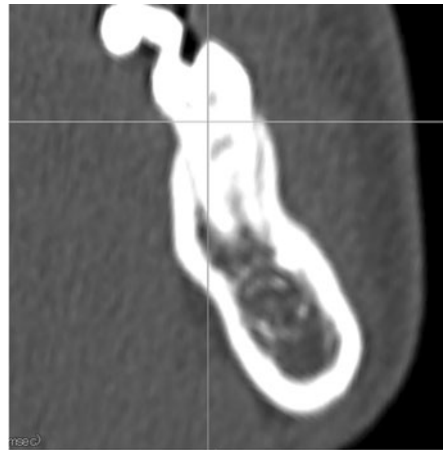


Fig. 2 Frontal MPR section

Mandibular vertical section was prepared using DICOM viewer software.

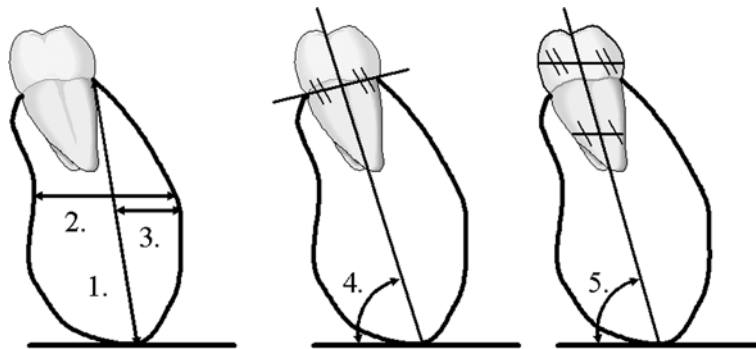


Fig. 3 Morphological parameters measured on frontal MPR sections

1. Height of mandibular body (mm); 2. Maximum buccolingual width of mandibular body (mm); 3. Degree of buccal protrusion of mandibular body (mm); 4. Inclination angle of mandibular body (deg.); 5. Inclination angle of buccolingual tooth axis of first molar (deg.)

were performed with the paired Student's *t*-test. The levels of significance used were $p < 0.01$ and $p < 0.05$. $p \geq 0.05$ was considered not significant. The subjects were not divided by gender due to comparison with paired Student's *t*-test.

Furthermore, on each frontal cephalogram, a perpendicular bisector was drawn on the plane connecting the left and right zygomaticofrontal sutures, and the distance to the menton was measured in order to assess the degree of median deviation.

Statistical analysis was conducted to assess

asymmetry (shifted side minus non-shifted side) in each parameter and correlations between median deviation and asymmetry. The levels of significance used were $p < 0.01$ and $p < 0.05$. $p \geq 0.05$ was considered not significant.

Results

1. Asymmetry in mandibular body morphology

No significant asymmetry was seen in the height of the mandibular body, the maximum

Table 1 Data for shifted and non-shifted sides

| Measured parameter | Shifted side | Non-shifted side | Significance |
|--|------------------|------------------|--------------|
| Height of mandibular body (mm) | 24.59 \pm 2.76 | 24.31 \pm 3.18 | ns |
| Maximum buccolingual width of mandibular body (mm) | 14.44 \pm 1.59 | 14.27 \pm 1.31 | ns |
| Degree of buccal protrusion of mandibular body (mm) | 5.72 \pm 0.61 | 5.71 \pm 0.74 | ns |
| Inclination angle of mandibular body (deg.) | 70.89 \pm 4.46 | 74.23 \pm 4.13 | p<0.01 |
| Inclination angle of buccolingual tooth axis of first molar (deg.) | 68.80 \pm 5.70 | 73.64 \pm 5.63 | p<0.01 |

ns: not significant

buccolingual width of the mandibular body or the degree of buccal protrusion of the mandibular body. However, between the shifted and non-shifted sides, there was a difference of about 3.5° in the inclination angle of the mandibular body, and the inclination angle for the non-shifted side was significantly greater than that for the shifted side (p<0.01). Furthermore, there was a difference of about 5° in the inclination angle of the buccolingual tooth axis of the first molar, and the inclination angle for the non-shifted side was significantly greater than that for the shifted side (p<0.01) (Table 1).

2. Relationship to median deviation

The average median deviation was 3.77 \pm 1.99 mm. The degree of median deviation showed no statistically significant correlations with asymmetry in the height of the mandibular body, the maximum buccolingual width of the mandibular body, the inclination angle of the buccolingual tooth axis of the first molar or the degree of buccal protrusion of the mandibular body, but there was a relatively strong correlation with asymmetry in the inclination angle of the mandibular body ($r = -0.65$, p<0.01) (Fig. 4).

Discussion

Morphological parameters of the mandibular body were previously measured on vertical sections by placing a dry mandible

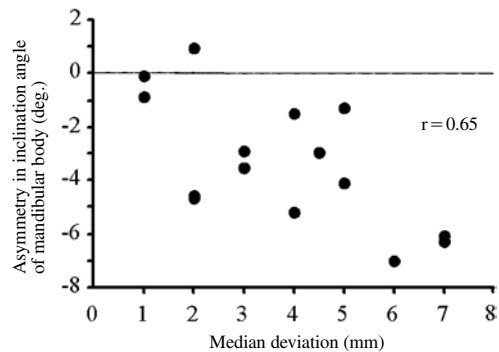


Fig. 4 Relationship between median deviation and asymmetry in inclination angle of mandibular body

on a reference plane and either measuring 3-dimensional coordinates using a 3-dimensional coordinate system¹⁾ or performing CT^{2,9)}. However, these methods cannot be used with live individuals and are rather complicated, as a special immobilizer is required to position mandibles on the reference plane. Hence, the present study utilized CT images and prepared MPR sections, which are radio-opaque images that can be reconstructed in any given plane. The advantages of MPR are that soft tissue can also be visualized, and the internal structures of the craniomaxillo-facial bone can be observed in detail. However, image quality of structures is markedly affected, depending on scanning plane, thus negatively affecting the stability of distance data³⁾. It is necessary to establish a standard reference plane to eliminate the negative

effects of changes in scanning planes; ensure the stability of distance data on MPR sections; and compare individual data. In the present study, a computer was used to position the mandible on a reference plane based on the menton and left and right gonions, and accurate vertical MPR sections of the mandibular body, including the molar region, were prepared. Then, 5 measurements, including the tooth axis of the molar region and the size and inclination angle of the mandibular body, were made on both the shifted and non-shifted sides.

When examined in the sagittal plane, patients with skeletal mandibular protrusion show dental compensation where maxillary anterior teeth incline buccally and mandibular anterior teeth incline lingually to compensate for the skeletal discrepancy of the maxilla and mandible^{8,12}. Furthermore, morphological studies of the mandibular symphysis have shown that, when compared to healthy individuals, there are no significant differences in the basal bone, but lingual inclination is seen with the alveolar bone, thus suggesting a significant correlation with mandibular anterior tooth inclination⁷. Therefore, one of the major objectives for presurgical orthodontic treatment is to eliminate dental compensation, thereby achieving normal tooth axes for the mandibular and maxillary anterior teeth and improving facial features. However, there have been no thorough studies on dental and skeletal compensation in the molar region in patients with facial asymmetry.

If orthognathic surgery is performed without addressing compensation, then the degree of lateral movement is small, and even if the midpoints of the maxilla and mandible match, facial symmetry may be insufficient. Nakakawaji *et al.*⁶ studied jaw deformity patients with facial asymmetry and reported that, following orthognathic surgery to match the maxillary and mandibular midpoints, the degree of improvement in the position of the mental midpoint and mandibular midpoint in relation to the facial midpoint was less than 50%. Kuroyanagi *et al.*⁴ studied patients following orthognathic surgery using a 3-dimensional

digitizing system and reported that the degree of change in soft tissue in the mental region was 80% that of the changes in the menton. Kusayama *et al.*⁵ and Shigefuji *et al.*¹⁴ investigated dental compensation in the molar region associated with orthognathic surgery in patients with facial asymmetry using frontal cephalograms and 3-dimensional dental images. They found that there were significant differences in the buccolingual tooth axis of the first molar between the shifted and non-shifted sides before treatment. The maxillary molars on the shifted side tilted buccally, while the mandibular molars on the shifted side tilted lingually. A significant correlation was also seen between mandibular displacement and maxillary molar axes in the non-shifted side, thus confirming dental compensation due to skeletal discordance in the frontal plane. However, to the best of our knowledge, there have been no studies investigating buccolingual inclination of molars and mandibular body morphology.

In the present study, there was no morphological asymmetry in the mandibular body in the molar region in the frontal plane, but in order to compensate for horizontal displacement of the basal bone in the molar region of the maxilla and mandible, buccolingual inclination of the tooth axis of the first molar and buccal inclination of the mandibular body were seen on the non-shifted side when compared to the shifted side. This suggests that the compensation mechanism involving mandibular and maxillary anterior teeth in patients with skeletal mandibular protrusion influences not only the buccolingual inclination of molars, but also the mandibular body. There was also a significant correlation with the degree of skeletal median deviation in the inclination angle of the mandibular body. Therefore, to achieve favorable post-treatment occlusal stability and facial symmetry in a clinical setting, it is necessary to actively improve the buccolingual tooth axis of molars in presurgical orthodontic treatment using mechanical means, such as standard edgewise brackets in the non-shifted side of the mandible or intermaxillary transverse elastic

placed from the shifted side of the maxilla to the non-shifted side of the mandible. However, asymmetry in mandibular body inclination cannot be improved orthodontically, while excessive buccal correction of the shifted side may lead to gingival recession. As a result, in patients with marked mandibular asymmetry, it is necessary to improve asymmetry by two-jaw surgery. This leads to overcorrection and contributes to post-treatment occlusal stability. In orthognathic surgery for jaw deformity accompanied by facial asymmetry, to achieve favorable results, a wide range of data, including 3-dimensional data, need to be thoroughly examined for treatment planning, including diagnosis and surgery.

The above findings clarified that in orthognathic surgery for jaw deformity accompanied by facial asymmetry, actively improving asymmetry in the buccolingual inclination of the tooth axis of the molar region during presurgical orthodontic treatment is important in achieving favorable post-treatment occlusal stability and facial symmetry.

References

- 1) Kasai K, Nakajima Y, Mashita M, Yasuda K, Enomoto Y, Go K, Iwasawa T, Kanazawa E (1990) Correlation between morphologies of mandibular vertical sections and linear measurements of the skull. *J Jpn Orthod Soc* 49:511–521. (in Japanese)
- 2) Kawamura A, Kanazawa E, Kasai K (1998) Relationship between teeth positions and morphological characteristics of vertical sections of the mandible obtained by CT scanning. *Orthod Waves* 57:299–306. (in Japanese)
- 3) Kobayashi M (2003) Comparison of the distance measurement stability in two X-ray computed tomography visualization methods. *Shikwa Gakuho* 103:497–508. (in Japanese)
- 4) Kuroyanagi W, Nojima K, Nishii Y, Yamaguchi H (2005) Three-dimensional changes in lower facial soft tissue following orthognathic surgery —Investigation of facial asymmetry cases—. *Shikwa Gakuho* 105:414–420. (in Japanese)
- 5) Kusayama M, Motohashi N, Kuroda T (2003) Relationship between transverse dental anomalies and skeletal asymmetry. *Am J Orthod Dentofac Orthop* 123:329–337.
- 6) Nakakawaji K, Otsuka A, Sueishi K, Suzuki T, Yamaguchi H, Sebata M (1986) A study of facial asymmetry cases with mandibular prognathism. part 2. comparison between pre- and post-treatment of frontal cephalometric and facial photographic analysis. *Bull Jpn Soc Jaw Deform* 5:156–157. (in Japanese)
- 7) Nojima K, Nakakawaji K, Sakamoto T, Isshiki Y (1998) Relationships between mandibular symphysis morphology and lower incisor inclination in skeletal Class III malocclusion requiring orthognathic surgery. *Bull Tokyo Dent Coll* 39:175–181.
- 8) Nojima K, Nagai H, Nishii Y, Sakamoto T, Yamaguchi H (2002) Morphological evaluations in skeletal Class III malocclusion requiring maxillofacial surgery using orthognathic surgical analysis. *Bull Tokyo Dent Coll* 43:163–171.
- 9) Okada N, Kasai K (1996) Relationship between mandibular tooth inclination and maxillofacial morphology using CT scanning. *Nihon Univ J Oral Sci* 22:381–392. (in Japanese)
- 10) Okada R, Motoyoshi N, Kuroda T (1996) Molar occlusal changes in the frontal dimension following surgical orthodontic treatment for the patient with skeletal mandibular protrusion. *Jpn J Jaw Deform* 6:129–136. (in Japanese)
- 11) Proffit WR, White Jr RP (2003) *Dentofacial problems: Prevalence and treatment need, Contemporary Treatment of Dentofacial Deformity*, 1st ed., pp. 1–28, Mosby, St. Louis.
- 12) Robinson SW, Spiedel TM, Issacson RJ, Worms FW (1972) Soft tissue profile change produced by reduction of mandibular prognathism. *Angle Orthod* 42:227–235.
- 13) Sato Y, Yamagata S, Okamoto T, Yamamoto T, Imai T, Iida J, Ueda Y, Okuda K, Takamichi O, Ohata N, Oda M, Yamaguchi H, Totsuka Y, Inoue N (2001) A study of the discrepancy in upper and lower basal arch widths related to inclination of the upper and lower molars in jaw deformity patients. *Jpn J Jaw Deform* 11:21–28. (in Japanese)
- 14) Shigefuji R, Motoyoshi N, Kuroda T (2001) Longitudinal changes of molar dental compensation following orthognathic surgery in facial asymmetry patients. *Jpn J Jaw Deform* 11:11–20. (in Japanese)

Reprint requests to:

Dr. Kunihiko Nojima
Department of Orthodontics,
Tokyo Dental College,
1-2-2 Masago, Mihama-ku,
Chiba 261-8502, Japan
E-mail: nojima@tdc.ac.jp