

[\[Print Version\]](#)
[\[PubMed Citation\]](#) [\[Related Articles in PubMed\]](#)

TABLE OF CONTENTS

[\[INTRODUCTION\]](#) [\[CASE REPORT\]](#) [\[DISCUSSION AND...\]](#) [\[REFERENCES\]](#) [\[FIGURES\]](#)

The Angle Orthodontist: Vol. 72, No. 4, pp. 371-376.

Treatment of Condylar Hypoplasia with Distraction Osteogenesis: A Case Report

Tülin Arun, DDS, PhD;^a Fulya Kayhan, DDS, PhD;^b Meral Kiziltan, MD, PhD^c

ABSTRACT

This report describes the surgical-orthodontic treatment procedures of a patient with condylar hypoplasia. Condylar hypoplasia is a major factor in any facial abnormality in a growing child. This case report describes a patient with a facial anomaly with an acquired unilateral condylar hypoplasia. His asymmetry was corrected by using functional therapy for the correction of muscle tonus and distraction osteogenesis for lengthening the mandibular ramal height. Fixed orthodontic appliances were used for conventional orthodontic therapy and final occlusal adjustment.

KEY WORDS: Condylar hypoplasia, Facial asymmetry, Distraction osteogenesis.

Accepted: December 2001. Submitted: August 2001

INTRODUCTION [Return to TOC](#)

Facial abnormalities may appear as a result of many pathologic conditions, but there are two major categories of abnormalities: genetic or congenital and acquired.¹⁻⁴ In the genetic group, the early differentiation of tissues and/or developmental processes are affected. Congenital hemifacial microsomia, micrognathia, Treacher Collins syndrome, Pierre Robin syndrome, Crouzon syndrome, and cleft lip and palate exemplify the genetic group. In each of these conditions, later growth patterns may be affected as a consequence of the developmental abnormality.^{1,2} In the second group, the acquired group of causes, trauma or infection are believed to be the primary reasons for the anomaly. Acquired condylar hypoplasia may develop after the loss of one or both condylar growth centers in the very early stages of life and is sometimes accompanied by ankylosis.⁵ In cases in which infection is the primary etiology, septic and destructive arthritis develop as a result of penetration of an infection such as suppurative otitis media into the joint capsule.⁶

When an affected side fails to grow downward and forward, a three-dimensional asymmetry is produced. The mandibular skeletal midline deviates to the affected side, a lack of vertical growth on the same side produces a cant of the occlusal plane, and mandibular retrognathia is seen as a result of the hypoplasia. The lower border of the mandibular corpus and angulus on the contralateral side is usually flattened. The severity of the deformity depends on the degree of hypoplasia or agenesis of the tissues involved, and the more severe the deformity,


the greater the probability that it will worsen with growth.¹⁻⁷

In growing patients, orthopedic treatment with functional appliances is often helpful in correcting deformities or in reducing the worsening of deformities with growth.⁸⁻¹⁰ If the facial asymmetry develops progressively during orthopedic treatment, mandibular distraction osteogenesis or surgical reconstruction of the temporomandibular joint with a costochondral graft of the remaining ramus tissue may be considered.²⁻¹¹ After the patient has stopped growing, skeletal deformities can be corrected only by double jaw surgery and/or genioplasty or unilateral mandibular augmentation.²

Osteodistraction is the process of generating new bone by stretching, first described in 1905 by Codivilla¹² and later developed by Ilizarov.¹³⁻¹⁵ It is been known for some time that new bone can be generated in a gap between two bone segments in response to the application of gradual stretching across the bone gap. Gradual traction of bone has been a standard procedure for treating the endochondral bones of the extremities. Since 1992, when McCarthy et al¹⁶ reported mandibular lengthening by distraction, other authors have also published papers reporting cases using the same technique in the human mandible¹⁷⁻²⁰ and facial bone area.²¹⁻²³ There are also studies showing the histologic and cellular changes produced by distraction osteogenesis.^{24,25}


CASE REPORT [Return to TOC](#)

An 8½-year-old boy was referred to the Orthodontic Department of Marmara University Dental School for the evaluation and treatment of facial asymmetry. His right condyle had been fractured when he was about 1 year old, but this had caused little pain and discomfort, and consequently the diagnosis was not made at the time of the injury. When he was 2½ years old, his family became aware of the progressing asymmetry of his face.




At the initial examination, it was observed that jaw opening was not affected, whereas lateral movements were limited. The patient was in the mixed dentition stage with a Class II deep bite occlusion with the lower dental midline deviated 7 mm to the right side at habitual occlusion. This was exaggerated during maximal opening. He had marked facial asymmetry with 7 mm of deviation of the chin point to the right side relative to the craniofacial midline, which was confirmed with posteroanterior measurements ([Figure 1A-D](#) ). There was a deficiency of vertical growth on the right side.


As a result of the shortening of the right ramal height compared with the left ramal height, a tilt of the occlusal plane was present. The patient's lower facial height was reduced considerably, and the mental muscle was hyperactive during swallowing and speaking. Radiographic and tomographic findings supported the clinical findings in these aspects. The tomographic data demonstrated that there was a mild deformation of the anterior border of the glenoid fossa, an absence of the right condylar head as a result of the probable resorption of the fractured condylar head, and an inferior position of the condyle in the fossa. The more superior position of the right angulus compared with the left was also evident tomographically.


Electromyographic recording




In view of the fact that there could be asymmetries of the masseter and temporal muscles because of the pathology of the skeleton, neuromuscular activity of these muscles was studied by electromyography (EMG) at the Department of Neurology of Cerrahpaşa faculty, İstanbul University with a four-channel EMG device (Dantec Counterpoint MK2).²⁶⁻²⁸ Surface silver chloride bipolar disc electrodes were placed bilaterally over the masseter and temporal muscle region with a distance of 2 cm between the electrodes. The patient was instructed to bite with maximum force while sitting as quietly as possible with his head in upright position. Four trials were done in each session, and 30-second intervals were allowed between trials to avoid muscle fatigue. The EMG results indicated marked differences between the tonic muscle activity of the right and left muscle groups ([Figure 2A](#) ). Asymmetry of the muscles was treated with functional therapy.

Treatment progress

The restoration of neuromuscular function was accomplished by using an upper acrylic plaque with soft material on the occlusal surfaces, which was designed to encourage the patient to bite in a correct position, for 6 months. The patient was instructed to chew and bite on the soft material ([Figure 2B](#) ). EMG records, taken at the end of this 6-month period, showed that the right masseter muscle had gained a stronger amplitude. Consequently, the patient was given a functional appliance-activator that was used for a 2-year period to correct overbite and midline and to enhance posterior vertical alveolar development on the right side and thereby correct the occlusal cant ([Figure 2C](#) ). When EMG records were taken again for the assessment of the tonic activity, the right masseter muscle had an amplitude comparable to that of the left masseter muscle. The temporal muscles were also found to be symmetrical in tonus. When the silent periods were assessed for the temporal and masseter muscles, the silent period was either insufficient or not formed at all ([Figure 2D](#) ).

Because the deficiency of ramal height on the right side caused persistence of the facial asymmetry, a right side distraction osteogenesis was planned. The patient was instructed to wear the appliance until the time of the surgical procedure to maintain the muscle coordination and the posterior vertical alveolar height achieved with the earlier treatments ([Figure 3A-C](#) ). A multidirectional distraction screw (Normed, Tuttlingen Germany) was placed in the patient's right ramus and corpus area in the Department of Surgical Reconstruction

of İstanbul University. One and a half months after the start of the distraction procedure, the skeletal midline matched. To overcome a possible future relapse, a 7-mm overcorrection was planned ([Figure 4A–C](#) ).

Since there was a severe lack of space for the upper dental arch, fixed appliance therapy with tooth extractions was initiated ([Figure 5A–G](#) ). During orthodontic treatment the anticipated spontaneous relapse of the midline occurred, and the midlines matched. There was no sign of the occlusal cant, and the facial asymmetry was greatly improved. The therapy was ended when a Class II molar and Class I skeletal relationship with pleasing facial aesthetics and a good intercuspation were achieved ([Figure 6A–J](#) ). Fixed lingual upper and lower retainers were used for the purpose of retention. At the end of the therapy, EMG recordings of the right and left temporal and masseter muscle tonic activity were obtained again. The mean amplitudes for the muscles were found to be symmetrical ([Figure 7](#) ).

DISCUSSION AND CONCLUSIONS [Return to TOC](#)

The main goals of treatment of acquired condylar hypoplasia in children are to establish a normal facial appearance and to provide effective function. A coordination of the interceptive orthodontic treatment and the surgical approach is needed to achieve these goals. The most important factor in the treatment of children is the elimination of late deformities or at least a minimization of these deformities. [1,2,7](#)

In the present case, the patient's lower facial height was restored, and the convexity of the soft tissue profile was corrected as planned. The planned distraction distance and vector were obtained. The patient did not experience pseudoarthrosis, nerve injury, tooth damage, persistent pain, discomfort, or infection. In spite of the underdevelopment of the right condyle and the asymmetry of the structures, the muscles were treated to a compatible and proportional state. Both the anterior temporal and masseter muscles were balanced between the right and left sides with respect to EMG amplitudes. The next step of treatment is a minor surgical correction of the flattening of the lower border of left side of the mandible to improve symmetry.

ACKNOWLEDGMENTS

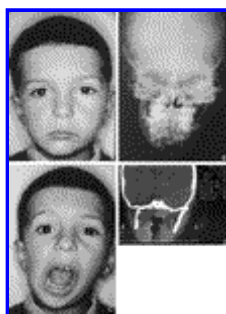We would like to thank Associate Professor Tamer Koldaş of the Department of Reconstructive Surgery, İstanbul University, for performing the distraction osteogenesis, and research assistant Hüseyin Özkan of the Department of Orthodontics, Marmara University, for his practical assistance in the conventional orthodontic approach at the final stage of treatment.

REFERENCES [Return to TOC](#)

1. Epker BN, Fish LC. *Dentofacial Deformities: Integrated Orthodontic and Surgical Correction*. Vol II, St Louis, Mo: Mosby; 1986:949.
2. Proffit WR, White RP. *Surgical Orthodontic Treatment*. St Louis, Mo: Mosby; 1991:483–502.
3. Bishara SE, Burkey PS, Kharouf JG. Dental and facial asymmetries: a review. *Angle Orthod*. 1994; 64:89–98. [[PubMed Citation](#)]
4. Swennen G, Schliephake H, Demph R, Schierle H, Malevez C. Craniofacial distraction osteogenesis: a review of the literature. *Int J Oral Maxillofac Surg*. 2001; 30:89–103. [[PubMed Citation](#)]
5. Proffit WR, Vig KWL, Turvey TA. Early fracture of the mandibular condyles: frequently an unsuspected cause of growth disturbances. *Am J Orthod*. 1980; 78:1–24. [[PubMed Citation](#)]
6. Norman JE de B, Bramley P. *A Textbook and Colour Atlas of the Temporomandibular Joint*. London, England: Wolfe Medical Publications Ltd; 1990.
7. Gorlin RJ, Pindborg JJ, Cohen MM Jr. *Syndromes of the Head and Neck*. 2nd ed. New York, NY: McGraw-Hill; 1976:546.
8. Melsen B, Bjerregaard J, Bundgaard M. The effect of treatment with functional appliance on a pathologic growth pattern of the condyle. *Am J Orthod Dentofacial Orthop*. 1986; 90:503–512. [[PubMed Citation](#)]
9. Williamson EH. Treatment of condylar fracture using a functional appliance in a 6-year-old child. *Facial Orthop Temporomandibular Arthrol*. 1986; 3:3–5.
10. Chate RAC. The propellant unilateral magnetic appliance (PUMA): a new technique for hemifacial microsomia. *Eur J Orthod*. 1995; 17:263–271. [[PubMed Citation](#)]
11. Nakata S, Mizuno M, Koyano K, Nakayama E, Watanabe M, Murakami T. Functional masticatory evaluation in hemifacial microsomia. *Eur J Orthod*. 1995; 17:273–280. [[PubMed Citation](#)]
12. Codivilla A. On the means of lengthening in the lower limbs, the muscles and tissues which are shortened through deformity. *Am J*

13. Ilizarov GA. The principles of the Ilizarov method. *Bull Hosp J Dis Orthop Inst.* 1988; 48:1–11. [[PubMed Citation](#)]
14. Ilizarov GA. The tension-stress effect on the genesis and growth of tissues: part I. The influence of stability of fixation and soft tissue preservation. *Clin Orthop.* 1989; 238:249–281.
15. Ilizarov GA. The tension-stress effect on the genesis and growth of tissues: part II. The influence of the rate and frequency of distraction. *Clin Orthop.* 1989; 239:263–285.
16. McCarthy JG, Schreiber J, Karp N, Thorne CH, Grayson BH. Lengthening the human mandible by gradual distraction. *Plast Reconstr Surg.* 1992; 89:1–10. [[PubMed Citation](#)]
17. Figueroa AA, Polley JW. Management of severe cleft maxillary deficiency with distraction osteogenesis: procedure and results. *Am J Orthod Dentofacial Orthop.* 1999; 115:1–12. [[PubMed Citation](#)]
18. Molina F, Ortiz-Monasterio F, De La Paz Aguilar M, Barrera J. Maxillary distraction: aesthetic and functional benefits in cleft lip-palate and prognathic patients during mixed dentition. *Plast Reconstr Surg.* 1998; 101:951–963. [[PubMed Citation](#)]
19. Swennen G, Figueroa AA, Schierle H, Polley JW, Malevez C. Maxillary distraction osteogenesis: a two-dimensional mathematical model. *J Craniofac Surg.* 2000; 11:312–317. [[PubMed Citation](#)]
20. Paccione MF, Mehrara BJ, Warren SM, Greenwald JA, Spector JA, Luchs JS, Longaker MT. Rat mandibular distraction osteogenesis: latency, rate, and rhythm determine the adaptive response. *J Craniofac Surg.* 2001; 12:175–182. [[PubMed Citation](#)]
21. Al Ruhaimi KA. Comparison of different distraction rates in the mandible: an experimental investigation. *Int J Oral Maxillofac Surg.* 2001; 30:220–227. [[PubMed Citation](#)]
22. Vargervik K, Miller AJ. Neuromuscular patterns in hemifacial microsomia. *Am J Orthod.* 1984; 86:33–42. [[PubMed Citation](#)]
23. Shirrazi M, Ehterami S, Djahanguiri B. Appliance effects on the masseter and temporal muscle electromyography of patients with facial asymmetry. *J Pedod.* 1990; 14:240–241. [[PubMed Citation](#)]
24. Huang CS, Ross RB. Surgical advancement of the retrognathic mandible in growing children. *Am J Orthod.* 1982; 82:89–103. [[PubMed Citation](#)]
25. Tehranchi A, Behnia H. Treatment of mandibular asymmetry by distraction osteogenesis and orthodontics: a report of four cases. *Angle Orthod.* 2000; 70:165–174. [[PubMed Citation](#)]
26. Kaplan RG. Induced condylar growth in a patient with hemifacial microsomia. *Angle Orthod.* 1989; 59:85–90. [[PubMed Citation](#)]
27. Yamashiro T, Okada T, Takada K. Case report: facial asymmetry and early condylar fracture. *Angle Orthod.* 1998; 68:85–90. [[PubMed Citation](#)]
28. Cope JB, Samchukov M. Regenerate bone formation and remodelling during mandibular osteodistraction. *Angle Orthod.* 2001; 70:99–111.

FIGURES [Return to TOC](#)



[Click on thumbnail for full-sized image.](#)

FIGURE 1. Initial clinical photographic (A), radiographic (B), wide-open photographic (C), and tomographic (D) record of the patient



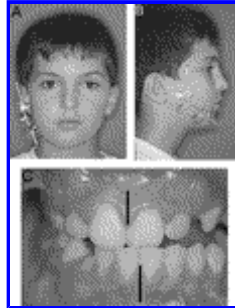
[Click on thumbnail for full-sized image.](#)

FIGURE 2. (A) The electromyographic (EMG) record before treatment. (B) The upper acrylic plaque with soft material loaded on occlusal surfaces. (C) The activator that was used during functional therapy. (D) The EMG record at the end of functional therapy



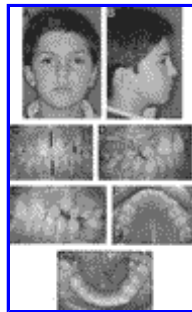
[Click on thumbnail for full-sized image.](#)

FIGURE 3. (A–C) Facial asymmetry and dental midline deviation before distraction osteogenesis



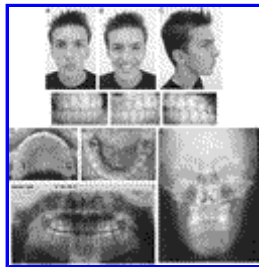[Click on thumbnail for full-sized image.](#)

FIGURE 4. (A–C) Multidirectional distraction screw application and overcorrection of the lower midline



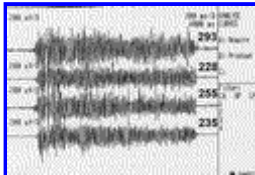
[Click on thumbnail for full-sized image.](#)

FIGURE 5. (A–G) Extraoral and intraoral views of the patient showing correction of skeletal and dental midline deviation at the end of the distraction osteogenesis



[Click on thumbnail for full-sized image.](#)

FIGURE 6. (A–J) Final extraoral and intraoral and radiographic views of the patient



Click on thumbnail for full-sized image.

FIGURE 7. Final electromyographic record

^a Associate Professor, Department of Orthodontics, Faculty of Dentistry, Yeditepe University, İstanbul, Turkey

^b Research Associate, Department of Orthodontics, Faculty of Dentistry, Yeditepe University, İstanbul, Turkey

^c Professor, Department of Neurology, Faculty of Medicine, İstanbul University, İstanbul, Turkey

Corresponding author: Tülin Arun, DDS, PhD, Yeditepe Üniversitesi, Dişhekimliği Fakültesi, Bağdat cad. No. 238 Göztepe, İstanbul, Turkey
(E-mail: tarun@yeditepe.edu.tr)