

SEARCH:

GO

Advanced Search

[Welcome](#) | [My Account](#) | [E-mail Alerts](#) | [Access Rights](#) | [Sign In](#)

INFORMATION FOR:

Authors/Reviewers



GO

CURRENT ISSUE: Vol. 144, No. 4, April 2008. Theme Issue: Melanoma

Advertisement

This Month in *Archives of Dermatology*

The Cutting Edge

- Successful Treatment With Etanercept of von Zumbusch Pustular Psoriasis in a Patient With Human Immunodeficiency Virus

Studies

- Utility of Lesion Diameter in the Clinical Diagnosis of Cutaneous Melanoma **FREE**
- Lymphatic Invasion Identified by Monoclonal Antibody D2-40, Younger Age, and Ulceration: Predictors of Sentinel Lymph Node Involvement in Primary Cutaneous Melanoma

Observations

- Suppression of Melanoma-Associated Neovascularization by Bevacizumab
- An Inquiry Into the Nature of the Pigmented Lesion Above Franklin Delano Roosevelt's Left Eyebrow

Editorials

- Early Recognition at Last
- Lymphangiogenesis: Host and Tumor Factors in Nodal Metastasis
- Health Promotion Programs for Melanoma Prevention: Screw or Spring?
- Staying on Top in Dermatology: Why We Must Act Now to Address the Capacity Challenge

skINsight

- Dermoscopy for the Screening of Common Urticaria and Urticaria Vasculitis

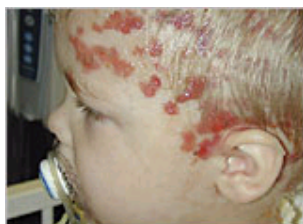[Complete Table of Contents](#)


Advertisement

EXPLORE & INTERACT

ARCHIVES CLINICAL CHALLENGE: YOU MAKE THE DIAGNOSIS

Acute Generalized Bullous Eruption in a 2-Year-Old Boy



CME COURSE

Survival Differences Between Patients With Scalp or Neck Melanoma and Those With Melanoma of Other Sites in the Surveillance, Epidemiology, and End Results (SEER) Program

TOP CONTENT

MOST VIEWED ARTICLES

- Carbamazepine-Induced, CD30⁺, Primary, Cutaneous, Anaplastic Large-Cell Lymphoma
- Heterozygosity for a Single Mutation in the *ABCC6* Gene May Closely Mimic PXE
- Between Light and Dark, the Chimera Comes Out
- Autoinflammatory Diseases
- Acne Vulgaris
- Visual Screening for Malignant Melanoma
- Cutaneous and Ocular Signs of Childhood Rosacea
- The Cutaneous Lupus Erythematosus Disease Area and Severity Index

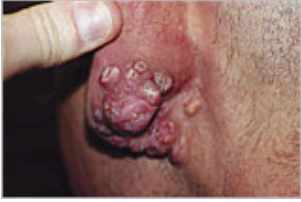OFF-CENTER FOLD: QUIZ CASES

A Protuberant Nodule Under the Foot

Multiple Painful Vaginal Ulcerations


Bluish Subcutaneous Nodule in a Child

Multinodular Lesions of the Earlobes



skINSight VIDEO SUPPLEMENT

Three-Dimensional Images and Vessel Rendering Using Optical Coherence Tomography



Safety and Efficacy of ABT-874, a Fully Human Interleukin 12/23 Monoclonal Antibody, in the Treatment of Moderate to Severe Chronic Plaque Psoriasis

Nevus of Ota Successfully Treated by Fractional Photothermolysis Using a Fractionated 1440-nm Nd

MOST SENT ARTICLES

Junctional CD8⁺ Cutaneous Lymphomas With Nonaggressive Clinical Behavior

Long- and Short-term Histological Observations of Congenital Nevi Treated With the Normal-Mode Ruby Laser

Efficacy and Safety of 5% Imiquimod Cream in Treating Patients With Multiple Superficial Basal Cell Carcinomas

The Pathogenesis of Chronic Idiopathic Urticaria
The Labial Melanotic Macule

Congenital Plaque-Type Glomovenous Malformations Presenting in Childhood

Mediation of Alopecia Areata by Cooperation Between CD4⁺ and CD8⁺ T Lymphocytes

Familial Primary Cutaneous Amyloidosis: Clinical, Genetic, and Immunofluorescent Studies

Treatment of Tattoos by Q-Switched Ruby Laser: A Dose-Response Study

Outpatient Phototherapy for Psoriasis

MOST VIEWED COLLECTIONS

Neurology

Dermatology, Other

Diagnosis

Public Health

Dermatologic Disorders, Other

Drug Therapy

Ophthalmology

Cardiovascular System

Pediatrics, Other

Aging/ Geriatrics



STAY CONNECTED

- Table of Contents E-mail Alerts
- Topic Collection E-mail Alerts
- RSS Feeds
- Calendar of Events
- Physician Jobs

CALL FOR NOTABLE NOTES

We invite authors to submit manuscripts for Notable Notes, which features humanity items, such as historical notes of interest, practice pearls, definitions and demonstration of dermatologic terms and signs. See our [Instructions for Authors](#) for details.

[HOME](#) | [CURRENT ISSUE](#) | [PAST ISSUES](#) | [TOPIC COLLECTIONS](#) | [CME](#) | [SUBMIT](#) | [SUBSCRIBE](#) | [HELP](#)
[CONDITIONS OF USE](#) | [PRIVACY POLICY](#) | [CONTACT US](#) | [SITE MAP](#)

© 2008 American Medical Association. All Rights Reserved.