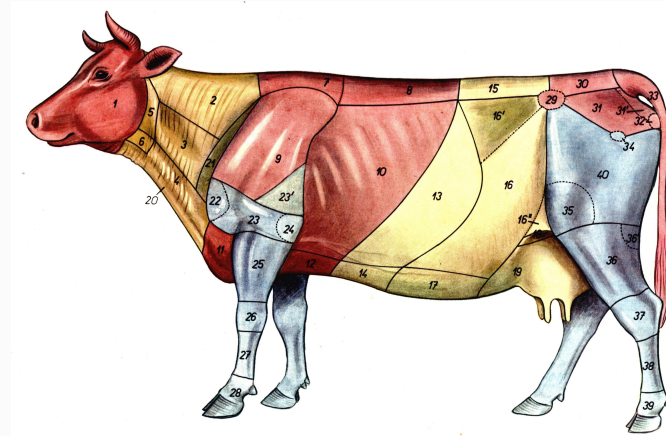




南京农业大学动物医学院

Animal Anatomy



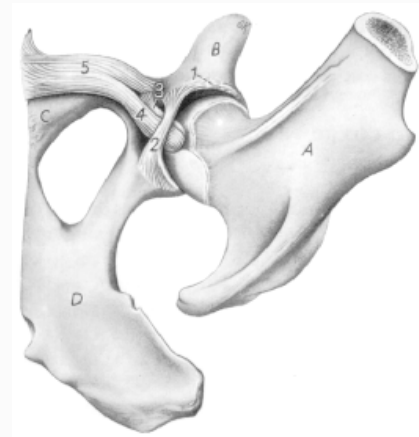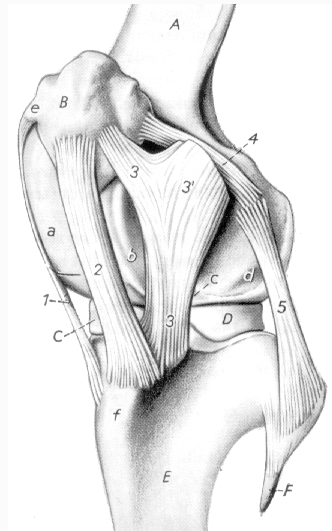
Lei Zhihai

College of Veterinary Medicine, NAU



南京农业大学动物医学院

2 Arthrology

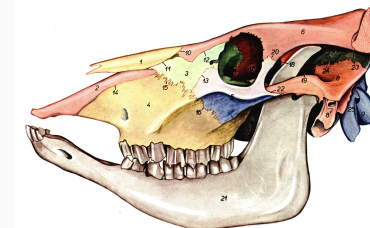
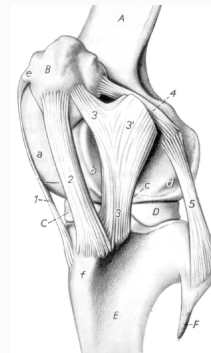




1 General description

In order for the skeleton to serve the purposes of protection and movement, the bones are articulated by the fibrous tissue, cartilage or even bone. All of these junctions are named as arthroses or joints. According to the mechanical properties, joints are classified into two fundamentally contrasting groups:

Synarthroses 直接连结
diarthroses 间接连结





1.1 synarthroses 直接连结

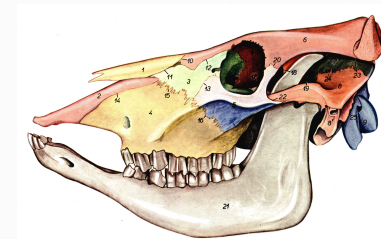
Synarthroses occur between two bone, which connected firmly without space between them. Therefore, they are immovable or slightly movable. Synarthroses are classified into:

fibrous joints 纤维连结

cartilage joints 软骨连结

bony joints 骨性结合

based on the type of material uniting the articulating bones.





1.1 synarthroses

1.1.1 fibrous joints 纤维连结

syndesmoses 韧带连结:

sutures 缝: skull

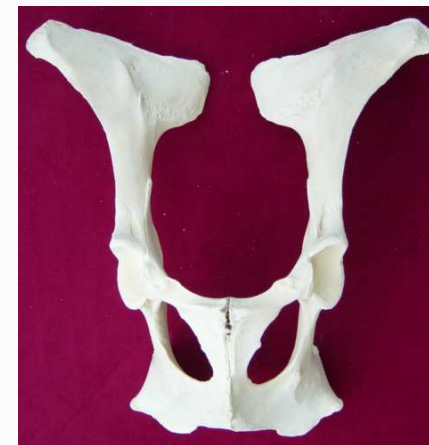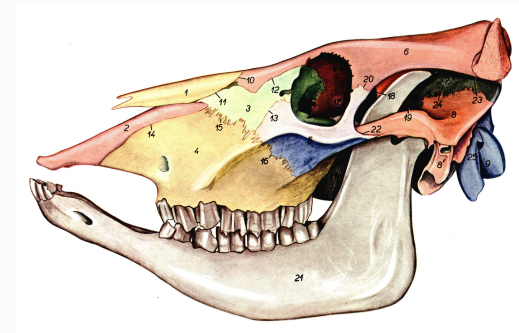
1.1.2 cartilage joints 软骨连结

synchondroses 透明软骨连结

symphysis 纤维软骨连结

1.1.3 bony joints 骨性结合

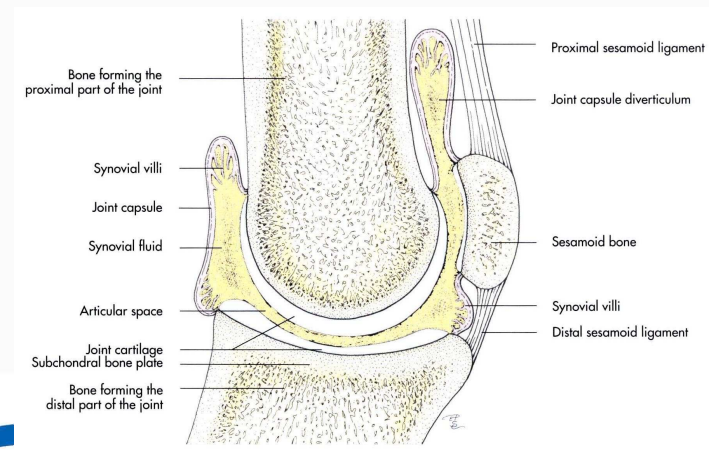
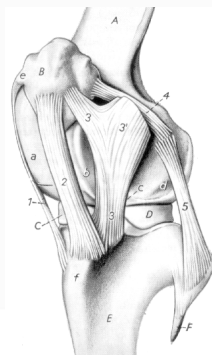
synostoses 骨性结合





1.2 diarthroses 间接连结

In a diarthroses, the opposite surfaces of articulated bones are separated by a space, which is filled with synovial fluid, and only connected by sleeve like fibrous membrane. It is also named as **synovial joint**. Synovial joints provide free movement between the bones they join and are typical of nearly all limb joints.





1.2.1 structure of synovial joints

Articular surface

Articular cartilage

Articular capsule

fibrous layer

synovial membrane

Articular cavity

Accessory structure

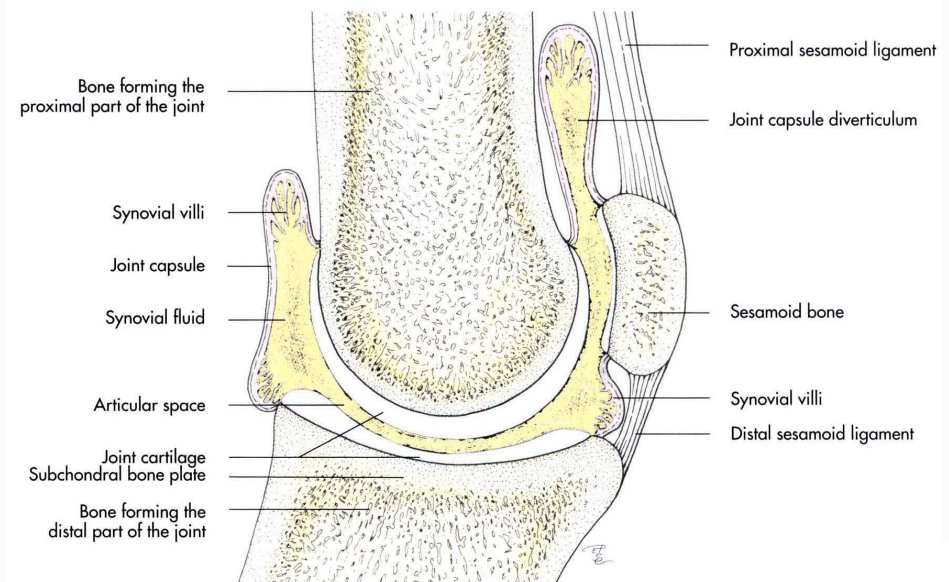
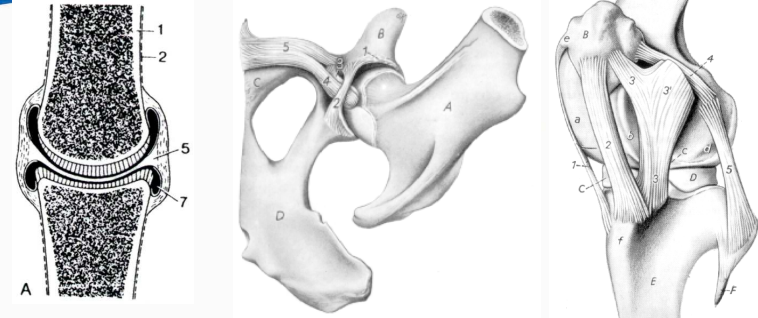ligament

extracapsular lig.

intracapsular lig.

articular disc

articular labrum





1.2.2 classification of synovial joints

Can be classified according to different characteristics:

I. Number of bones forming the joint:

simple joints 单关节

composite joints 复关节

II. Type of movement allowed by the joint:

Uniaxial joints 单轴关节

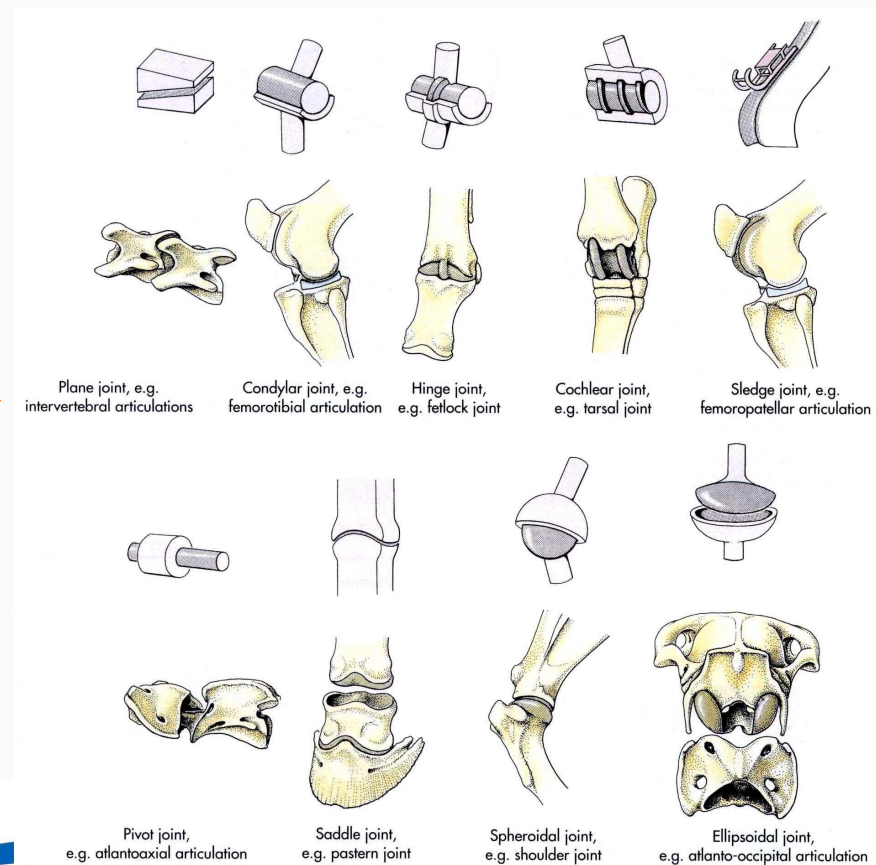
Hinge joint 屈戌关节

Pivot joint 车轴关节

Biaxial joints 双轴关节

saddle joint 鞍状关节

ellipsoid joint 椭圆关节





1.2.2 classification of synovial joints

II. Type of movement allowed

By the joint:

Uniaxial joints

Biaxial joints

Multiaxial joints: 多轴关节

Ball-and-socket joint 球窝关节

III. Form of articular surfaces

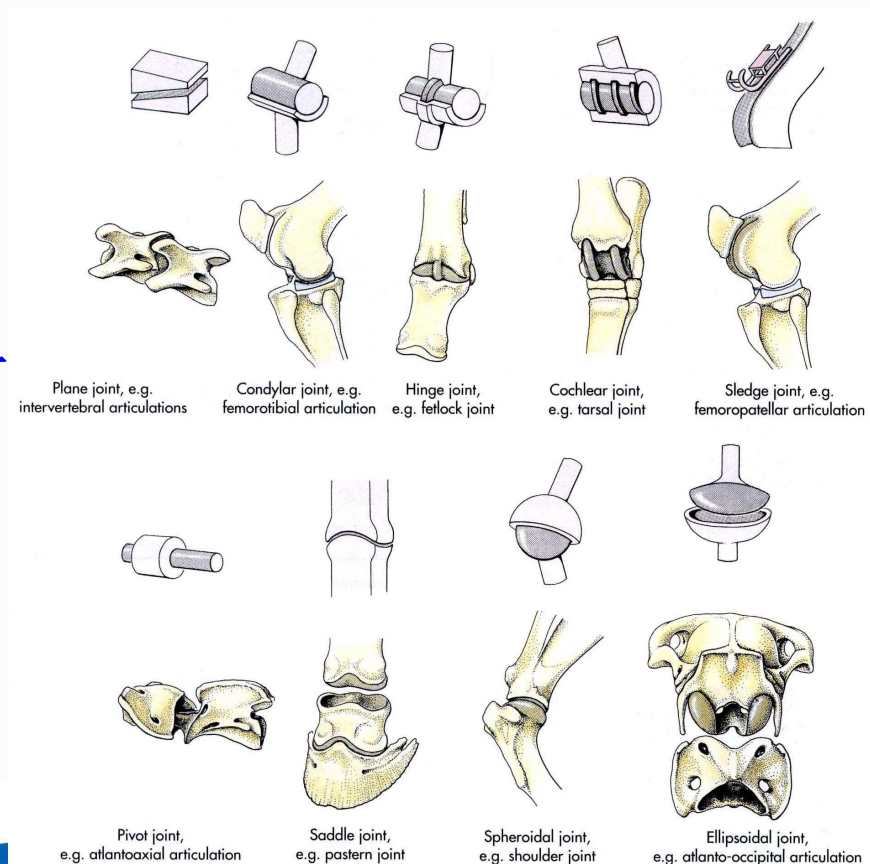
Hinge joint; Pivot joint

Ellipsoid joint; Saddle joint

Ball-and-socket joint

Plane joint

Condylar joint





1.2.3 joint movements

Articular movements are usually grouped as three pairs of antagonistic movements based on three orthogonal axes, which a joint may have.

Flexion 屈

Extension 伸

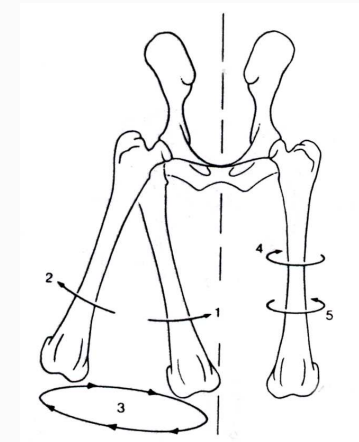
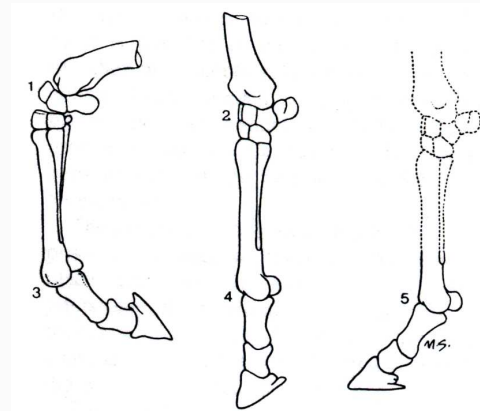
Abduction 展

Adduction 收

Pronation 旋前

Supination 旋后

Circumduction 环转





2 joints of the trunk

2.1 intervertebral articulation

Vertebral column

Joints between vertebral body

Intervertebral disc

pulpy nucleus 髓核

fibrous ring 纤维环

Joints of vertebral arches

plane joints 平面关节

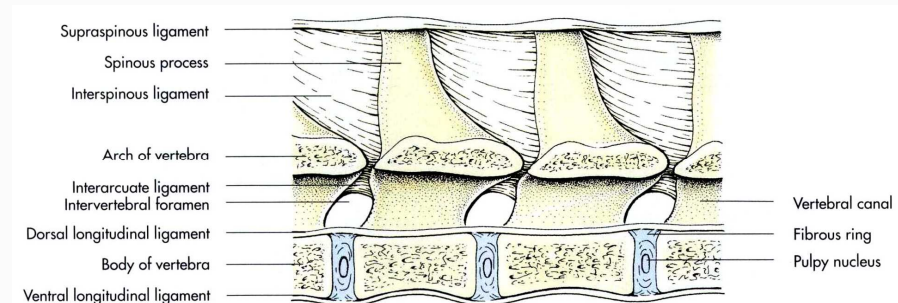
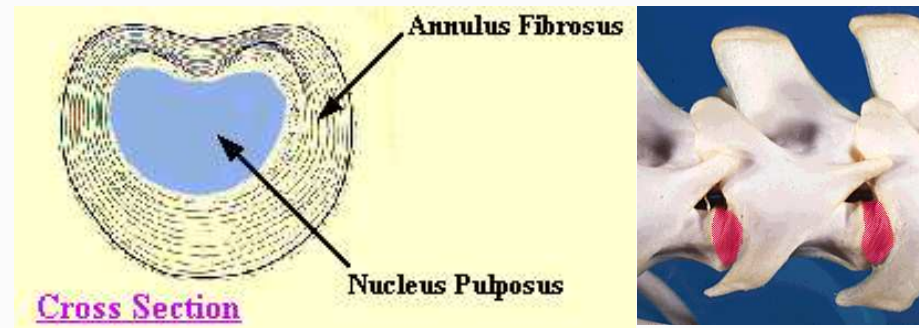
Ligaments of the vertebral column

Short ligaments

Interarcuate ligaments

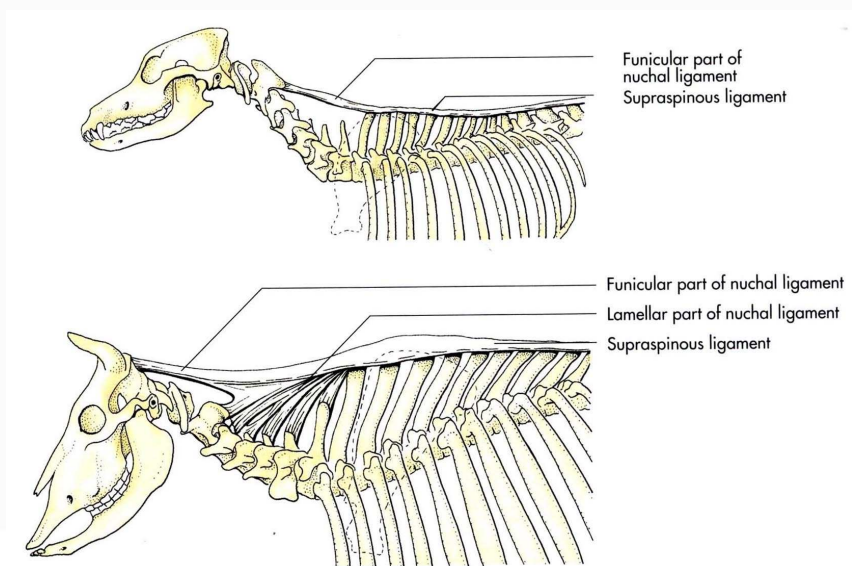
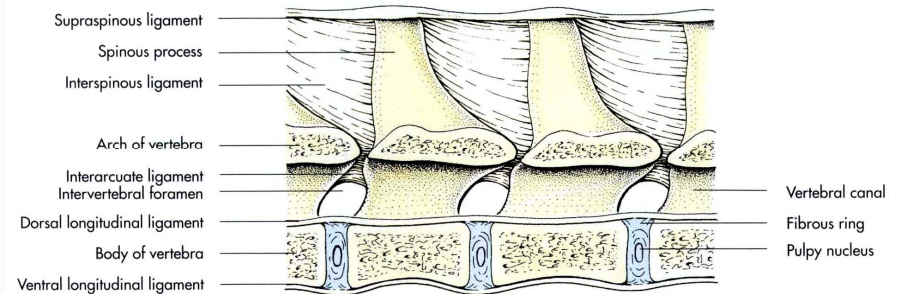
Intertransverse ligaments

Interspinous ligaments





2 joints of the trunk
2.1 intervertebral articulation
long ligaments
Supraspinous ligament
Nuchal ligament 项韧带
 funicular part 索状部
 laminar part 板状部
Dorsal longitudinal ligament
 背侧纵韧带
Ventral longitudinal ligament
 腹侧纵韧带
Atlanto-occipital joint
Atlantoaxial joint





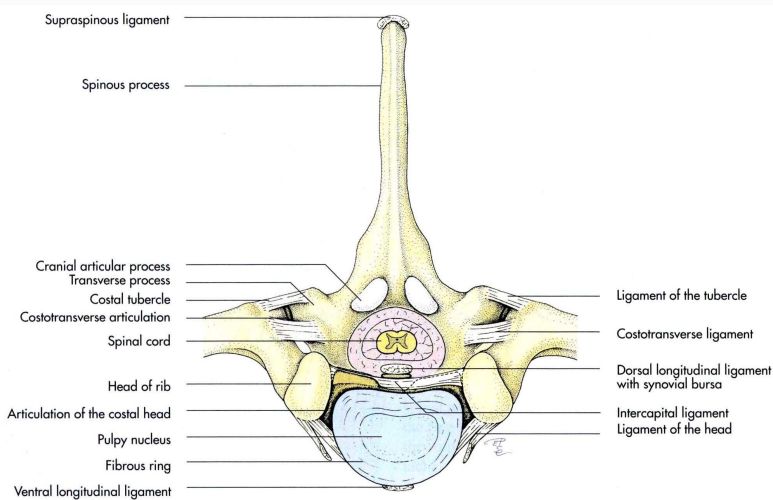
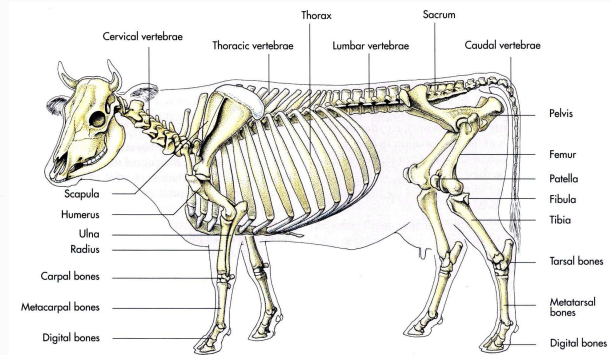
2.2 joints of the thorax

2.2.1 costovertebral joint

Joint of costal head 肋头关节

Costotransverse joint 肋横突关节

2.2.2 sternocostal joint





3 articulations of the skull

Cartilagenous junctions

Osseous sutures 缝

Temporomandibular joint

颞下颌关节 condylar joint

condyloid process of mandible

articular are of squamous

part of temporal bone

articular tubercle

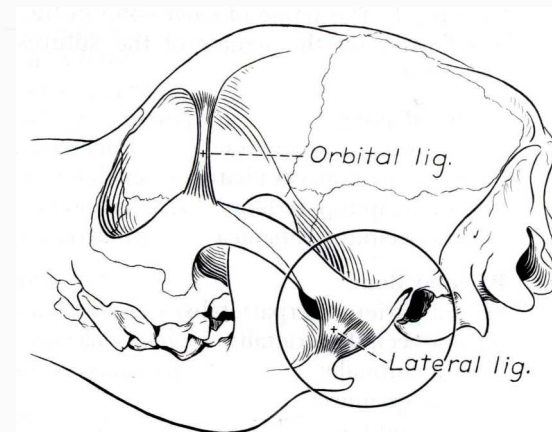
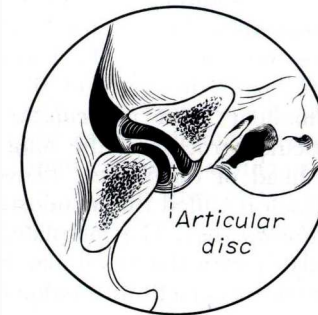
mandibular fossa

fibrocartilagenous disc

Lateral ligament 侧韧带

Caudal ligament 后韧带

Function: open and close mouth





4 articulations of the thoracic limb

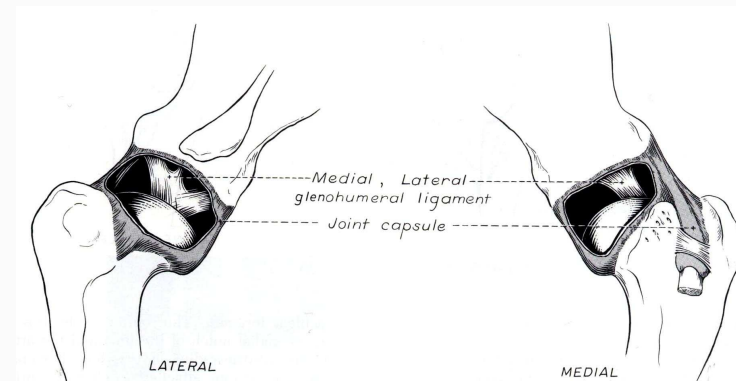
The forelimb is joined to the axial skeleton by an arrangement of muscles, tendons and fascia, without forming a conventional joint.

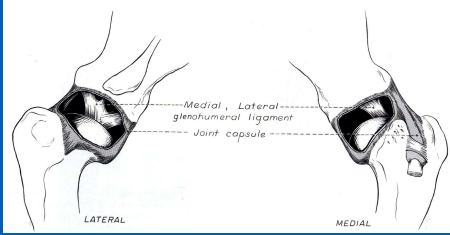
Should joint 肩关节

Elbow joint 肘关节

Carpal joints 腕关节

Phalangeal joints 指关节





4.1 should joint

Glenoid cavity 关节盂

Humeral head 肱骨头

Glenoid lip

Spheroid joint

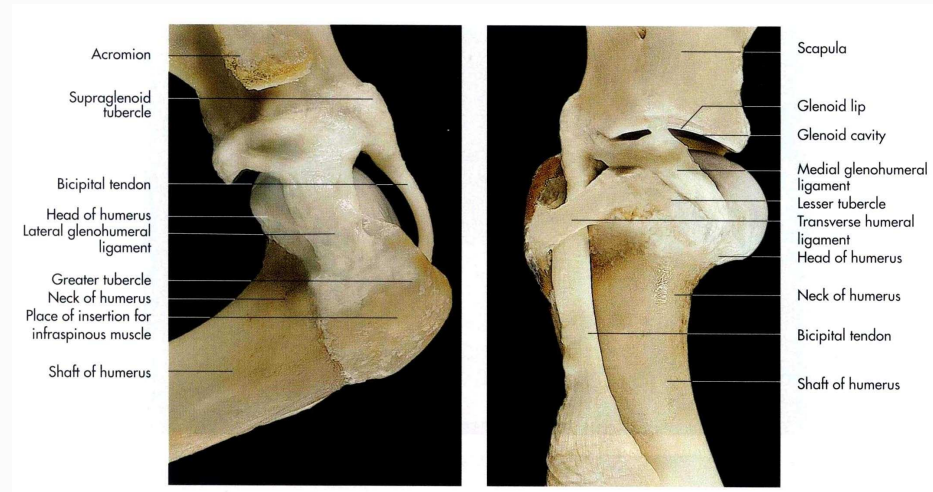
No collateral ligaments

Joint capsule is spacious

Medial glenohumeral lig.

Lateral glenohumeral lig.

function as a hinge joint with primary movements being flexion and extension. Rotation, adduction and abduction are restricted.





4.2 elbow joint

Comosite joint 复关节

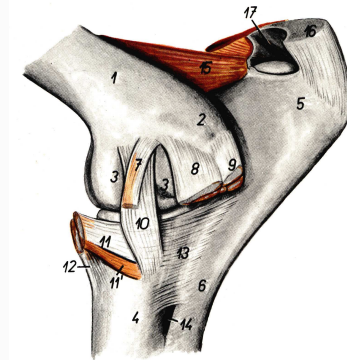
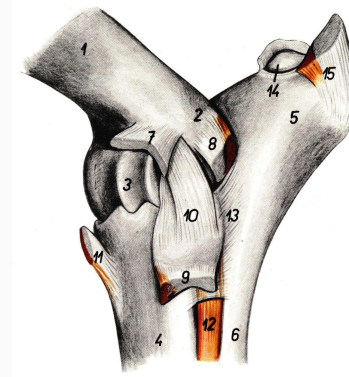
Humeral condyle

Radial head 桡骨头

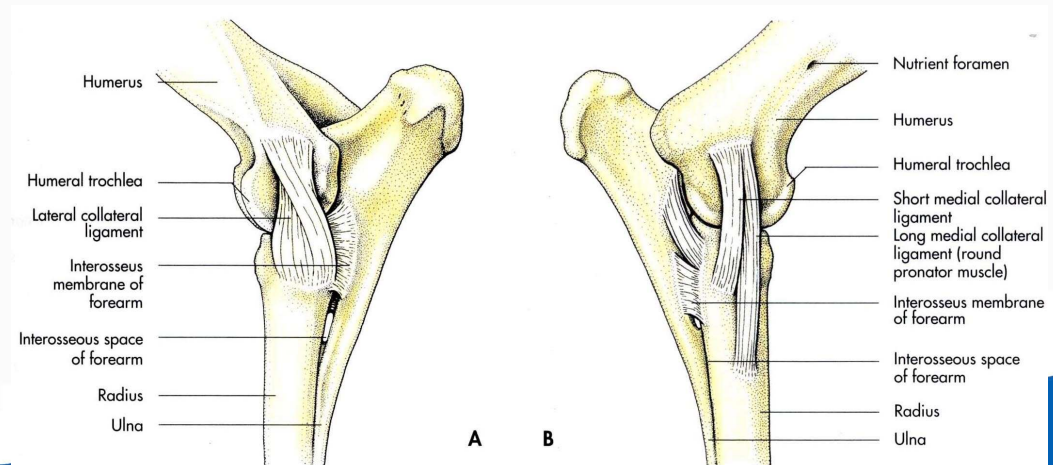
Trochlear notch of ulna

Lateral collateral ligament

Medial collateral ligament



Bovine elbow joint, lat. & med.





4.3 carpal joint

Comosite joint 复关节

Hinge joint 屈戌关节

Antebrachio-carpal joint

Radiocarpal joint

Ulnocarpal joint

Middle carpal joint

Intercarpal joint

Carpometacarpal joint

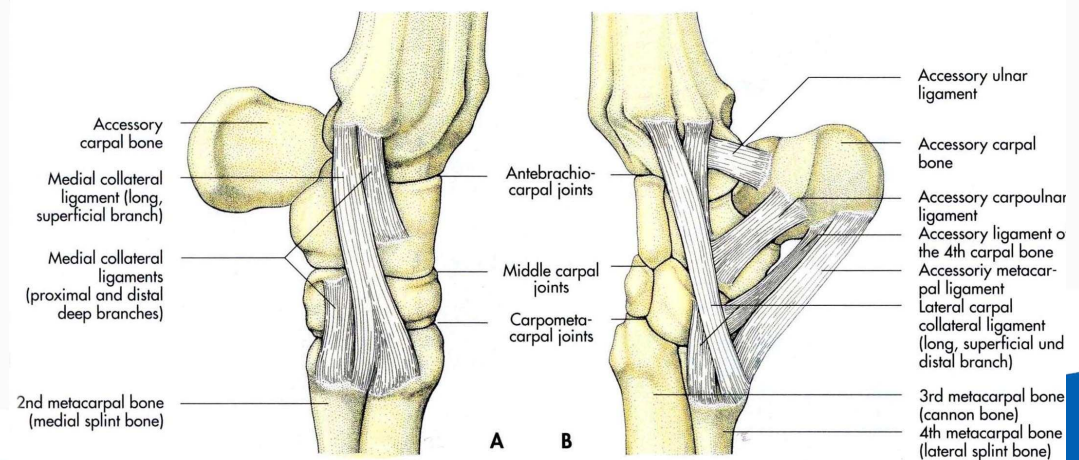
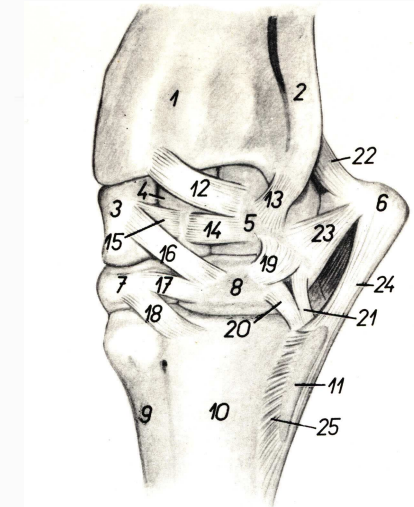
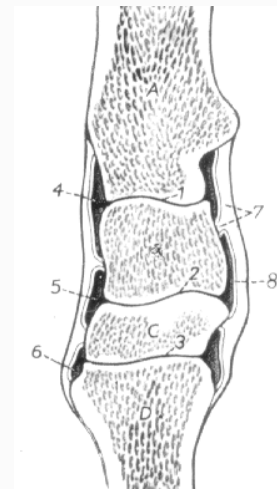
3 synovial cavities

Lateral collateral lig.

Medial collateral lig.

Extensor retinaculum

Flexor retinaculum

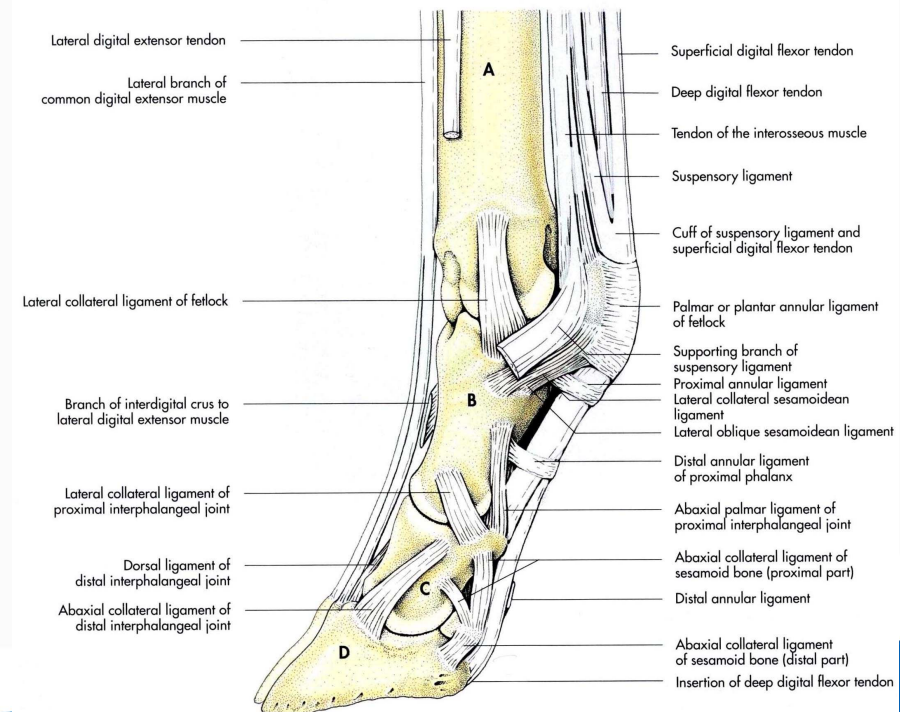
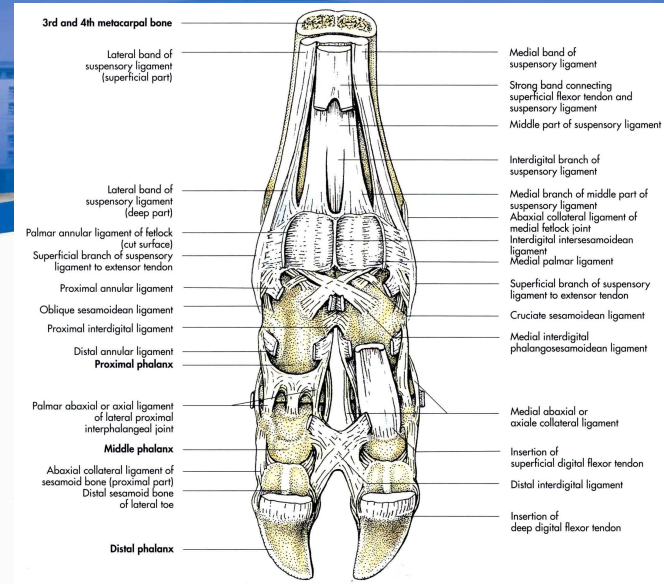


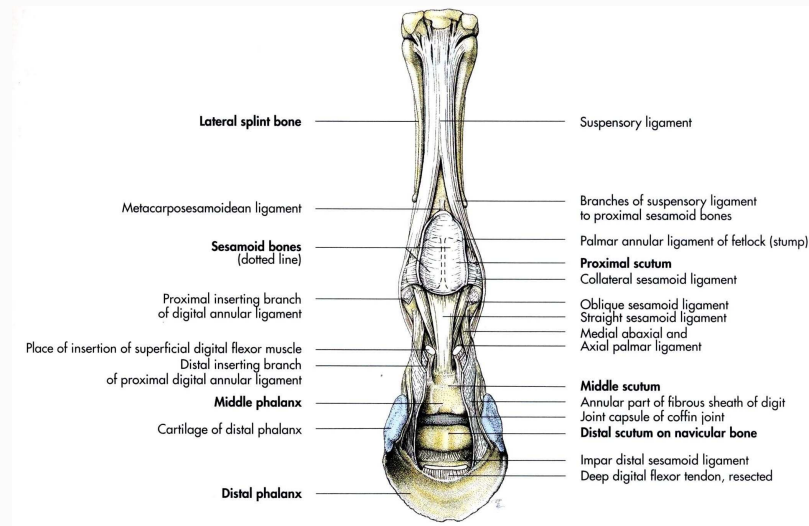
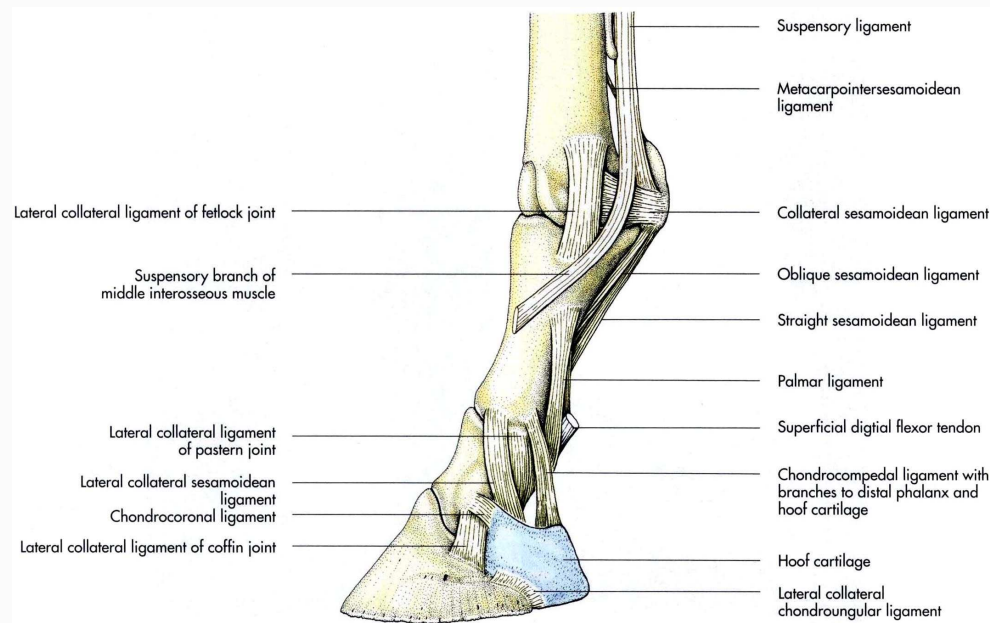


4.4 phalangeal joint

南京农业大学动物医学院

4.4 phalangeal joint
Comosite joint 复关节
Metacarpophalangeal joint
fetlock joint 系关节
Proximal interphal. Lig.
Collateral ligaments
Suspensory ligament 悬韧带
Palmar ligament 掌侧韧带
Sesamoid ligament 籽骨韧带
Proximal interphalangeal joint
or pastern joint 冠关节
Distal interphalangeal joint
or coffin joint 蹄关节







5 articulations of the pelvic limb

The hindlimb is joined to the trunk by the pelvic girdle(hip bones). The ilium articulates dorsally with the sacrum forming the sacroiliac joint.

The joints of hindlimb include:

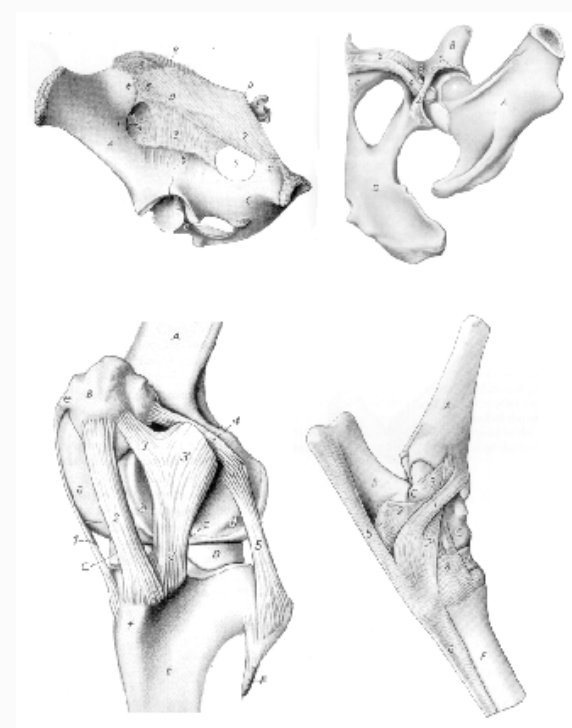
Sacroiliac joint 荐髂关节

hip joint 髋关节

stifle joint 膝关节

tarsal joints 跗关节

Phalangeal joints 趾关节





5.1 sacroiliac joint

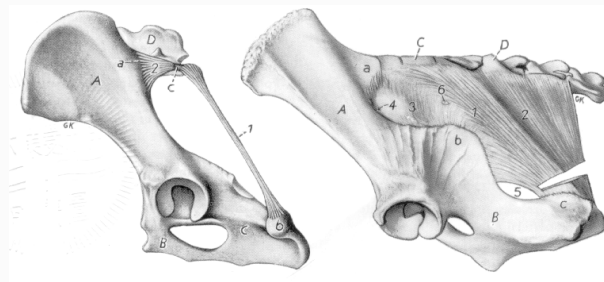
The sacroiliac joint is tightly formed by the auricular surfaces of the wing of the ilium and the wing of the sacrum.

Ventral sacroiliac ligament 荐髂腹侧韧带

Dorsal sacroiliac ligament 荐髂背侧韧带

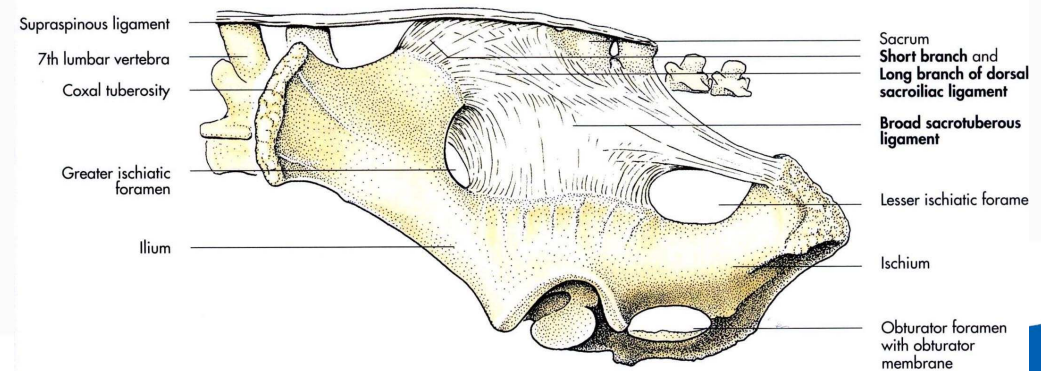
Broad sacrotuberous ligament 荐结节阔韧带

Sacrospinous ligament 荐结节韧带 (犬)



dog

pig





5.2 coxofemoral joint

The hip joint is a spheroid joint formed by the head of the femur articulating with the acetabulum.

The joint capsule is spacious.

Acetabular lip 髋臼唇

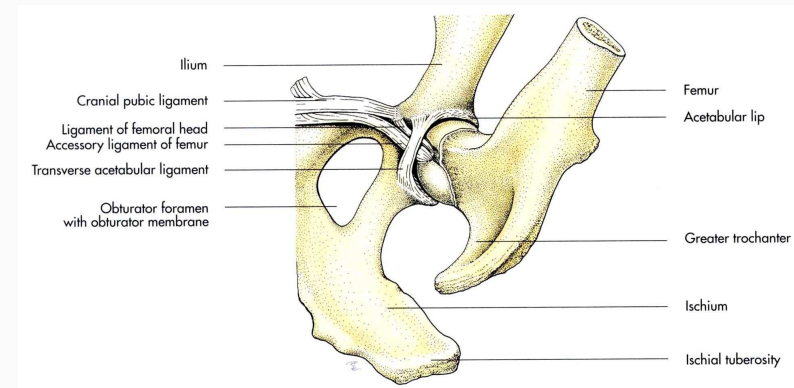
Ligament of the head of femur

股骨头韧带（圆韧带）

Accessory ligament 副韧带

Transverse acetabular lig.

髋臼横韧带





5.3 stifle joint

Composite, incongruent hinge joint

Femoropatellar joint 股膝关节

Patellar retinacula 膝支持带

Femoropatellar ligament 股膝韧带

Patellar ligament 膝韧带

Femorotibial joint 股胫关节

Meniscus 半月板

2 femorotibial joint sacs

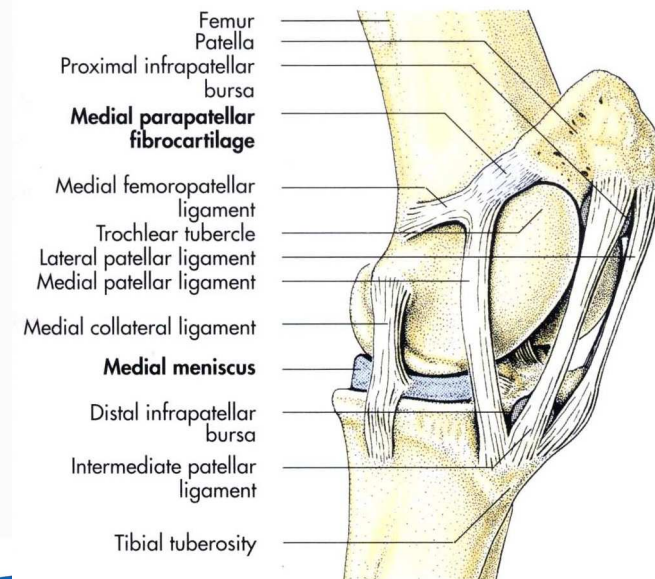
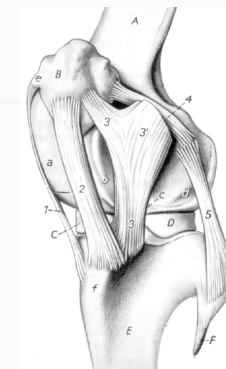
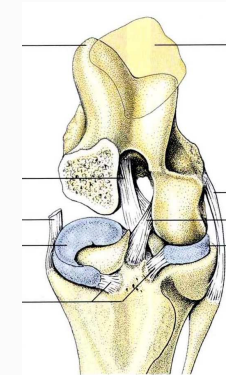
Meniscal ligaments

Lateral collateral ligament

Medial collateral ligament

Caudal cruciate ligament

Cranial cruciate ligament





5.4 tarsal joint

Composite joint, formed between the tibia and fibula, the tarsal bones and the metatarsal bones with 4 levels of articulation.

Tarsocrural joint

Proximal intertarsal joint

Distal intertarsal joint

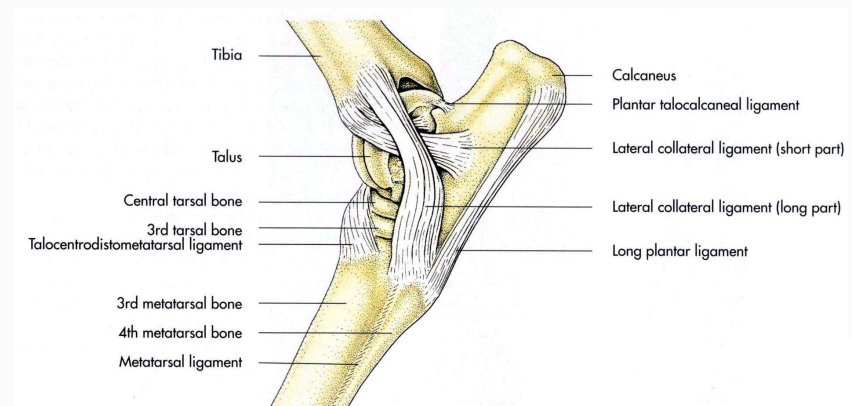
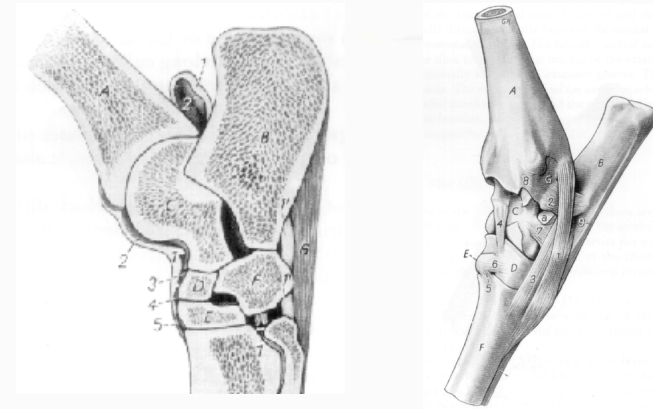
Tarsometatarsal joint

Lateral collateral ligament

Medial collateral ligament

Dorsal tarsal ligament

Long plantar ligament





5.5 phalangeal joint

The joints of the metatarsus and digits are similar to the corresponding joints of the thoracic limb.

